

Malignant melanoma metastasis to pancreas diagnosed by endoscopic ultrasound guided fine needle aspiration Cytology: A case report

Ram Nawal Rao^{1,*}, Paramita Paul², Sanjay Kannaujia³, Praveer Rai⁴

¹Additional Professor, ^{2,3}Senior Resident, Dept. of Pathology, ⁴Additional Professor, Dept. of Gastroenterology, Sanjay Gandhi Postgraduate Institute of Medical Sciences, Lucknow, Uttar Pradesh

***Corresponding Author:**

Email: rnawalrao@gmail.com

Abstract

Pancreatic metastasis of malignant melanoma is rarely diagnosed on EUS FNAC while the patient is alive. Primary or secondary pancreatic malignant melanoma are rarely described in the literature. Most of the cases have been reported in the literature by surgical pathology. A 52-year-old male patient presented with 3 episodes of pain in abdomen for last 15 days. Patient had history of blackish discoloration with mass in big toe which was amputated 1 year ago. On examination, multiple soft to firm non tender nodules palpable over right shin, right thigh and over right scapula. Patient was admitted for evaluation of pancreatic mass. CT abdomen and thorax showed lobulated heterogenous mass replacing pancreas with encasement of splenic vessels. Endoscopic ultrasound-guided fine needle aspiration (EUS-FNA) was performed from the mass of the pancreas. A probable cytomorphological diagnosis of malignant melanoma metastatic to pancreas was made. The final diagnosis of malignant melanoma was confirmed by strong positivity of HMB45 and S100 immunocytochemical staining on endoscopic ultrasound-guided fine needle aspiration cytology (EUS-FNAC). We report a very unusual case of malignant melanoma metastatic to pancreas diagnosed by EUS-FNAC. Although this is uncommon in the pancreas, malignant melanoma should be considered in the differential diagnosis of metastatic pancreatic masses on cytology.

Keyword: Melanoma, Endoscopic, Cytology and Immunocytochemistry

Introduction

Malignant melanoma metastatic to the pancreas is extremely rare,^(1,2) and cytologically only <5 cases have been reported in the literature, most of cases which have been diagnosed on histopathology. Malignant melanoma is a highly aggressive neoplasm which originates from melanocytes. Surgical exploration for abdominal metastases of cutaneous melanoma reveals pancreatic metastases in 16% of patients which is usually accompanied by other intra-abdominal spread.⁽³⁾ Endoscopic ultrasound (EUS) and EUS-guided fine-needle aspiration (EUS-FNA) of primary and metastatic pancreatic masses have already been described. Imaging studies including ultrasound, CT, and MRI have limited value to distinguish the tumors from primary ductal adenocarcinoma. EUS-FNA can provide tissue diagnosis from pancreatic masses, specifically when other modalities have failed. We report a case of malignant melanoma metastatic to pancreas diagnosed by immunocytochemistry and endoscopic ultrasound guided fine needle aspiration cytology.

Case Report

A 52 year old male presented with pain abdomen for past 6 months. Pain was in the left hypochondrium, occurred once a month for first 3 months, each episode lasting for 8-12 hrs. Pain was non colicky in nature, not associated with vomiting, and relieved by parenteral diclofenac. Patient had 3 episodes of pain for last 15 days. No history of jaundice, GI bleed, diarrhoea, pallor, icterus, cynosis, edema, lymphadenopathy, DM and HTN seen. He had history of blackish

discolouration with mass in big toe which was amputated 1 year ago. On examination, multiple soft to firm nontender nodules palpable over right shin, right thigh and over right scapula. Patient was admitted for evaluation of pancreatic mass. Serum amylase was not significantly elevated. USG abdomen showed bulky mass in pancreas. CT abdomen and thorax showed lobulated heterogenous mass replacing pancreas with encasement of splenic vessels. Para-aortic, pericardial, and gastrohepatic nodes were enlarged. Multiple opacities were seen in bilateral lung fields. Multiple polypoidal masses were seen in the gastric body and antrum.

Endoscopic ultrasound (EUS) was performed which showed mass measuring 3.5x 2.5cm in size in the pancreas (**Fig. 1**) and multiple black nodules in fundus, body and antrum of stomach. EUS FNA from pancreas showed clusters and singly scattered oval to spindle shaped atypical cells on a necrotic background. These cells display enlarged, moderately pleomorphic hyperchromatic nuclei with condensed chromatin, prominent nucleoli and moderate amount of cytoplasm with intracytoplasmic melanin pigments (**Fig. 2**). Few large bizarre cells are also seen. Fine needle aspiration cytology (FNAC) from skin of shin, scapula and thigh lesions also done and showed tumor cells with melanin pigment of similar morphology.

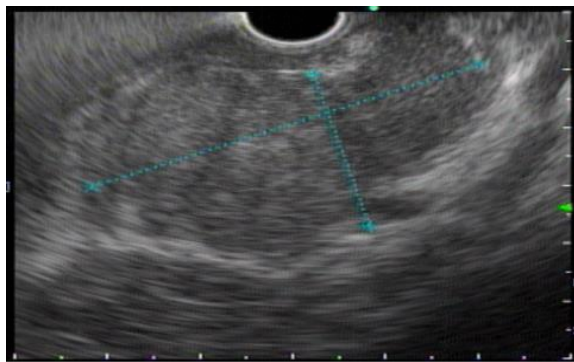

Fig. 1: EUS ultrasound showed well defined mass measuring 3.5x 2.5cm in size in pancreas

Immunocytochemistry was done on the EUS-FNA cytology smears from pancreas mass and showed strong positive immunostaining for HMB45 (**Fig. 3**) and S100 (**Fig. 4**). Cytologic and immunocytochemistry findings was confirmed the diagnosis of malignant melanoma metastatic to pancreas. Radiotherapy opinion was taken and planned for chemotherapy after confirming the diagnosis. Status of the patient is afebrile, pain free and hemodynamically stable.

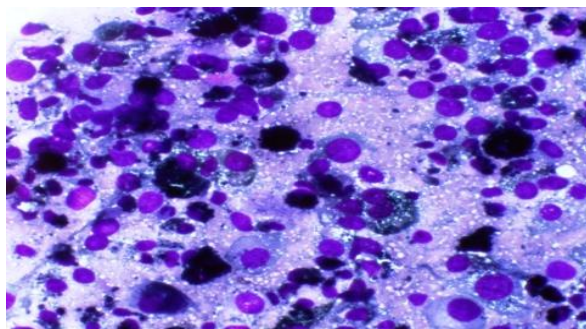


Fig. 2: Cytology smear showed clusters and singly scattered atypical cells having moderately pleomorphic hyperchromatic nuclei with condensed chromatin, prominent nucleoli and moderate amount of cytoplasm with intracytoplasmic melanin pigments. Few large bizarre cells are also seen (MGG x40)

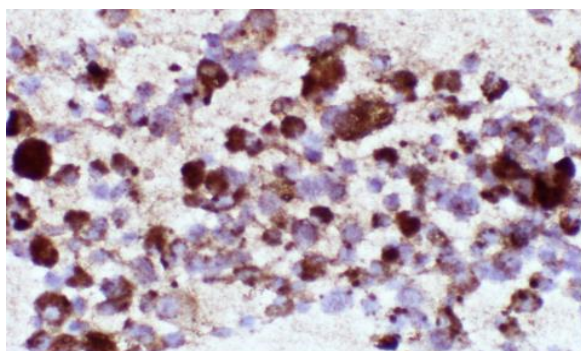


Fig. 3: HMB-45 showed strong immunostaining positivity in the tumor cells.(HMB45, x40 magnification)

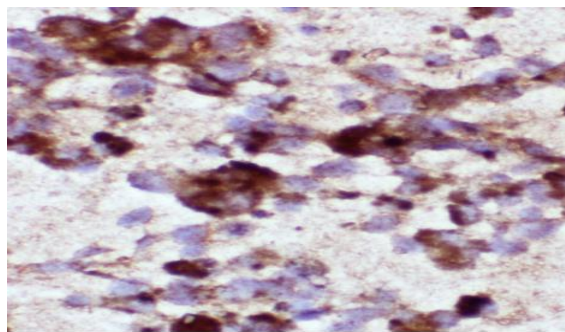


Fig. 4: S100 showed strong immunostaining positivity in the tumor cells.(S100, x40 magnification)

Discussion

Metastatic pancreatic malignant melanoma is considered to be a highly aggressive neoplasm. Malignant melanoma only rarely metastasizes to the pancreas from another primary tumor account for approximately <2%.^(1,2) Only few cases of metastatic malignant melanoma to pancreas diagnosed by EUS ultrasound guided fine needle aspiration cytology have been reported in the literature. The first use of EUS-FNA for the diagnosis of malignant melanoma metastatic to the pancreas in two cases had performed in cystic or solid pancreatic masses. Preparation of a cell block from the FNA aspirate and use of immunostaining may help to obtain the final diagnosis. Despite thorough examination of the skin and mucous membranes, however, a primary site might not be found in these patients.⁽³⁾ **Minoguchi M, et al** reported a 35-year-old woman displaying a solid mass of the pancreas with confirmative diagnosis of metastatic melanoma of the pancreas. Her past medical history included a radical hysterectomy 2 years previously for malignant melanoma of the vagina. Twelve months later, lung metastasis was also resected. EUS-FNA recognized the pancreatic tumor was histologically and immunohistochemically identical to the surgical specimen of her lung neoplasm. Imaging studies including US, CT, and MRI have limited value to distinguish the tumors from primary ductal adenocarcinoma. EUS-FNA can provide tissue diagnosis from pancreatic masses, specifically when other modalities have failed.⁽⁴⁾ A case of resection of pancreatic metastasis of malignant melanoma originating from the nasal cavity was detected in a 46-year-old man who had undergone proton-beam therapy for nasal melanoma 12 months earlier, he underwent distal pancreatectomy with splenectomy and the pathological diagnosis was metastatic malignant melanoma to the pancreas and further discussed their incidence, therapeutic strategy, and outcome of mucosal melanoma of the head and neck.⁽⁵⁾ Retrospective evaluation of stage of primary malignancies, interval between diagnosis of primary tumors and detection of

pancreatic metastases, treatment for metastases to the pancreas, survival rate, and prognostic factors in 31 patients with pancreatic metastases including a single case of malignant melanoma had been done in which pancreatic metastases were synchronous in six cases and metachronous in twenty five cases, with median interval time of 40.8 months (range 3-186) between the diagnosis of primary tumor and detection of pancreatic metastases. The median survival after the detection of the metastases was 16 months. In multivariate analysis, non-renal cell carcinoma as primary malignancy and positive symptom related to pancreatic metastases were associated with poor prognosis. The patients (0.17%) underwent the procedure for surgical management of malignant melanoma metastatic to the pancreas,⁽⁶⁾ the median overall survival of 11.4 months,⁽⁷⁾ and portends a poor prognosis with a 5-year survival of less than 10% and a median survival of 6–9 months.⁽⁸⁾ The cases of pancreatic metastasis included 22 patients, 10 men and 12 women, mean age 61 years (range: 35-76) in which the primary tumors were renal-cell carcinoma, colorectal cancer, lung cancer, breast cancer, cutaneous melanoma and ileal carcinoid. Computed tomography and endoscopic ultrasound was done in 18 patients mainly showed solitary and hypodense or hypoechoic masses. The confirm diagnosis was obtained before surgery by EUS-guided fine needle aspiration, ultrasound-guided biopsy or duodenoscopy.⁽⁹⁾ The metastatic lesions to the pancreas from primary tumors composed of renal cell carcinoma, lobular carcinoma of the breast, endometrioid carcinoma of the ovary, colonic adenocarcinoma, jejunal leiomyosarcoma, melanoma, and non-small-cell lung cancer have been reported in the literatures. The median interval between primary tumor and pancreatic metastases was 36 months (range: 5–192 months).⁽¹⁰⁾

The role and efficacy of surgical resection of multiple metastatic lesions is comparatively less impressive. Some groups have published reports of survival benefit from resection of multiple lesions.⁽⁸⁾ The resection of single metastatic lesions yielded a higher survival rate as compared to resection of multiple metastases. However, the technical feasibility of a complete surgical extirpation is higher in isolated metastases than in multiple metastases. Isolated pancreatic metastasis from malignant melanoma (IPMMM) is rare because most melanoma patients already have a widespread disease at diagnosis.⁽¹¹⁾ Pancreatic metastatic tumors are uncommon and account for less than 2% of all pancreatic carcinomas.⁽¹²⁾ Around one-third of patients with malignant melanoma develop metastases.⁽¹³⁾ In our patient the primary lesion was seen in big toe along with nodules formation in multiple sites including pancreas, stomach, right shin, right thigh and scapula. After 2 month of follow up, patient is well and active.

We concluded that malignant melanoma metastatic to pancreas diagnosed by EUS-FNAC should be

considered in the differential diagnosis of metastatic pancreatic masses on cytology when a patient with pancreatic mass had a history of other malignancy or even with presence of several years earlier treated history.

References

1. Nikfarjam M, Evans P, Christophi C. Pancreatic resection for metastatic melanoma. *HPB (Oxford)*.2003;5:174–9.
2. Roland CF, van Heerden JA. Non-pancreatic primary tumors with metastasis to the pancreas. *Surg Gynecol Obstet*.1989;168:345–7.
3. DeWitt JM, Chappo J, Sherman S. Endoscopic ultrasound-guided fine-needle aspiration of melanoma metastatic to the pancreas: report of two cases and review. *Endoscopy*. 2003;35(3):219-222.
4. Minoguchi M, Yanagawa N, Ishikawa C, Sasajima J, Goto M, Okamoto M, Saito Y, Murakami M, Orii Y, Yaosaka T. Pancreatic metastasis of malignant melanoma diagnosed by EUS-guided fine needle aspiration (EUS-FNA). *Nihon Shokakibyō Gakkai Zasshi*.2007;104(7):1082-7.
5. Sugimoto M, Gotohda N, Kato Y, Takahashi S, Kinoshita T, Shibasaki H, Kojima M, Ochiai A, Zenda S, Akimoto T, Konishi M. Pancreatic Resection for Metastatic Melanoma Originating from the Nasal Cavity: A Case Report and Literature Review. *Anticancer Res February* 2013;33(2):567-573.
6. Boo SJ, Kim MH, Kim YS, Ryu CH, Kim HJ, Park DH, Lee SS, Seo DW, Lee SK, Kim SC, Han DJ. Clinical characteristics of pancreatic metastases. *Korean J Gastroenterol*. 2011;57(6):358-64.
7. Goyal J, Lipson EJ, Rezaee N, Edil BH, Schulick R, Wolfgang CL, Hruban RH, Antonarakis ES. Surgical Resection of Malignant Melanoma Metastatic to the Pancreas: Case Series and Review of Literature. *J Gastrointest Cancer*. 2012;43(3):431–436.
8. Meyer T, Merkel S, Goehl J, Hohenberger W. Surgical therapy for distant metastases of malignant melanoma. *Cancer*. 2000;89:1983–91.
9. Moussa A, Mityr E, Hammel P, Sauvanet A, Nassif T, Palazzo L, Malka D, Delchier JC, Buffet C, Chaussade S, Aparicio T, Lasser P, Rougier P, Lesur G. Pancreatic metastases: a multicentric study of 22 patients. *Gastroenterol Clin Biol*. 2004;28:872.
10. Crippa S, Angelini C, Mussi C, Bonardi C, Romano F, Sartori P, Uggeri F, Bovo G. Surgical Treatment of Metastatic Tumors to the Pancreas: A Single Center Experience and Review of the Literature. *World Journal of Surgery*.2006;30(8):1536-1542.
11. David Jérémie Birnbaum, Vincent Moutardier, Olivier Turrini, Anthony Gonçalves, and Jean Robert Delpero. Isolated Pancreatic Metastasis from Malignant Melanoma: Is Pancreatectomy Worthwhile? *J Surg Tech Case Rep*. 2013 Jul-Dec;5(2):82–84.
12. Z'graggen K, Fernández-del Castillo C, Rattner D W, Sigala H, Warshaw AL. Metastases to the pancreas and their surgical extirpation. *Arch Surg*. 1998;133:413–7.
13. Allen PJ, Coit DG. The surgical management of metastatic melanoma. *Ann Surg Oncol*. 2002;9:762–70.