

Endometriosis of the appendix presenting as acute appendicitis

Kafil Akhtar^{1,*}, Mohd Talha², Shivani Gupta³, Ashok Kumar⁴

¹Professor, ²Resident, ³Pathologist, ⁴Consultant Pathologist, Dept. of Pathology, ^{1,2}Jawaharlal Nehru Medical College, Aligarh Muslim University, Aligarh, Uttar Pradesh, ^{3,4}Ashok Pathology and Research Center, Aligarh, Uttar Pradesh, India

***Corresponding Author:**

Email: drkafilakhtar@gmail.com

Abstract

Acute appendicitis is a surgical emergency and accounts for 27.5% of the surgical cases. It is a very common cause of gynecologic lower abdominal pain and may occur simultaneously with a variety of gynecologic diseases. We report a case of a 24 years old female, who presented to the surgical emergency department with complaints of acute pain in abdomen for the last 1 day with tenderness in right iliac fossa. Laboratory reports showed leucocytosis with neutrophilia, with presence of toxic granules. A provisional diagnosis of appendicitis was made and the patient was operated. The appendectomy specimen on histopathological examination showed ectopic endometrial glands and stroma in the serosa, based on which a diagnosis of appendiceal endometriosis was given. This case emphasizes the importance of considering the diagnosis of appendiceal endometriosis in a young female of child bearing age with a clinical diagnosis of appendicitis.

Keywords: Appendicitis, Endometriosis, Endometrial glands, Stroma.

Introduction

Acute appendicitis accounts for 27.5% of surgical emergencies, with a peak occurrence between 10-30 years of age.¹ It usually presents with peri-umbilical pain, which shifts to the right lower abdominal quadrant, accompanied by anorexia, nausea and vomiting. On physical examination, right lower quadrant tenderness at McBurney's point is typically elicited. There is also localized tenderness to percussion, guarding, positive psoas sign, obturator sign and Rovsing's sign. Eighty percent cases show leukocytosis with >10000 cells per mm³. An elevated leucocyte count in conjunction with neutrophilia and elevated C-reactive protein level, however, has a sensitivity of 97-100%. Ultrasound may show a non-compressible appendix > 6 cms in diameter and CT scan with features of periappendiceal inflammatory reaction help in the diagnosis.² Histopathological examination in acute appendicitis is characterized by mucosal ulceration and transmural polymorphic infiltrate, accompanied by mural necrosis.³

Appendiceal endometriosis was first reported in 1860 and its prevalence is about 0.8%.^{4,5} Endometriosis of the gastrointestinal tract, although rare, may cause a wide spectrum of symptoms. The symptomatology of the disease is often related to the location of the lesion. Endometriosis is the presence of endometrial glands and stroma outside the uterine cavity and its musculature.⁴ It usually affects 4.0% to 50.0% of women in their reproductive life. The most common symptom is pelvic pain seen in about 50.0% of the cases.⁵ Appendiceal endometriosis may also cause cyclic and chronic right lower quadrant pain, melena, lower intestinal haemorrhage, caecal intussusception and intestinal perforation, especially during pregnancy.^{3,4}

Case Summary

A 24 year old woman presented to the surgical emergency department with complaints of acute abdominal pain for the last 1 day in the right lower quadrant, accompanied by nausea, vomiting and anorexia. The patient was afebrile and hemodynamically stable. Her past medical and surgical history was non-contributory. Her physical examination revealed tenderness in the right lower quadrant and suprapubic region, with no distension, guarding, rebound or rigidity. Her gynaecologic examination revealed no cervical/vaginal discharge or uterine and adnexal tenderness. Laboratory investigations revealed leucocytosis of 15000/mm³ with 80.0% neutrophils on differential count. Her urinalysis was normal and urine pregnancy test was negative. Computed tomography (CT) scan of abdomen and pelvis with intravenous and oral contrast revealed a mildly dilated and congested appendix, 7.5 mm in diameter, with minimal wall thickening, consistent with acute appendicitis (Fig. 1). Arterial flow was adequate and demonstrated in both the ovaries ruling out ovarian torsion. A provisional diagnosis of acute appendicitis was made and appendectomy was performed.

Intra-operatively, the appendix was mildly congested. Gross examination showed an enlarged appendix measuring 6.5×0.6 cm, with small nodules in the wall of size 5×3×2 mm, tan to greyish black in color and rubbery in consistency (Fig. 2). On microscopic examination of the appendix, ectopic endometrial glands surrounded by endometrial stroma were seen in the serosa. A final diagnosis of appendiceal endometriosis was given (Fig. 3 and 4). Postoperatively, the patient recovered with no residual pain. After 6 months of follow up examination her gynecologic record remains clear and ultrasonography,

CT scan and diagnostic laparoscopy has revealed no other sites of endometriosis.

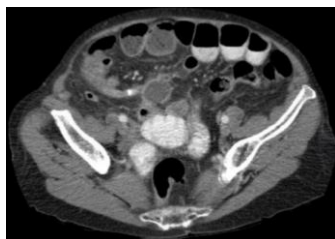

Fig. 1: Computed tomography scan of abdomen and pelvis with intravenous and oral contrast revealed a mildly dilated appendix, measuring 7.5 mm in diameter, and mild wall thickening consistent with acute distended appendicitis



Fig. 2: Grossly the appendix measured 6.5×0.6 cm, with small nodules in the wall of the appendix measuring 5×3×2 mm with tan to greyish black in color and rubbery consistency

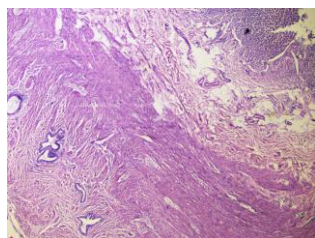


Fig. 3: Endometriosis of the appendix: On microscopic examination of the appendix, ectopic endometrial glands were seen surrounded by endometrial stroma in the serosa. Hematoxylin and Eosin x 10X

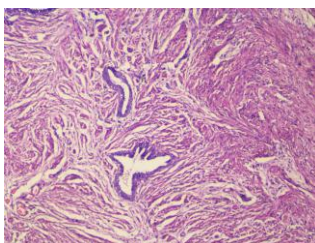


Fig. 4: High power of Figure 3

Discussion

Endometriosis is diagnosed, when endometrial tissue is found outside its normal location in the uterus. It is seen in 10.0% of women within their menstrual age. It is called "adenomyosis" or "internal endometriosis" when the endometrial tissue is found within the uterine muscles. External endometriosis is

commonly found in the genital organs and the pelvic peritoneum.⁶

Appendiceal endometriosis was first described in 1860.⁴ The actual prevalence of extra-genital endometriosis is unknown, but some reports state it's prevalence to be about 0.8%.^{4,5} Extragenital endometriosis occurs in almost every organ and tissue in the body like the gastrointestinal system, mesentery, liver, operation scars, but rare in the kidneys, lungs, central nervous system, skin and the extremities.⁶⁻⁸ Interestingly, spleen is one of the only sites where extra-genital endometriosis has not been reported.⁷ The incidence of appendiceal endometriosis has been reported to be between 0.05-0.8%.⁵

Several theories have been proposed to explain the pathogenesis of extra-genital endometriosis.⁸ The implantation or retrograde menstruation theory proposes that endometrial tissue from the uterus is transported in a retrograde fashion through the fallopian tubes.⁹ The direct transplantation theory and the dissemination theory can also explain the pathogenesis of extra-pelvic endometriosis.

The coelomic metaplasia theory hypothesizes that the peritoneal cavity contains progenitor cells or cells capable of differentiating into endometrial tissue. The induction and embryonic rest theory claims that a specific stimulus to a Mullerian origin cell nest produces endometriosis.⁹ The most recent theory is the cellular immunity theory, which suggests that alterations in cell-mediated and humoral immunity allow ectopic endometrial cells to proliferate.⁸

Appendiceal endometriosis patients can be categorized into four groups in terms of symptomatology: (1) patients who present with acute appendicitis; (2) patients who present with invagination of the appendix; (3) patients with atypical symptoms such as abdominal colic, nausea and melena; and (4) patients who are asymptomatic.

The pathogenesis of appendiceal endometriosis is varied. Patients may present as acute appendiceal inflammation because of partial or complete luminal occlusion by the endometrioma or the invaginated endometrial tissue.¹⁰ Another mechanism suggested is that of haemorrhage within the ectopic endometrium within the seromuscular layer of appendix, which is followed by edema, obstruction and inflammation.

The most common symptoms is pain in the right lower abdominal quadrant, which is seen in one-third of the patients.⁶ Physical examination is still the most important diagnostic tool, but imaging is increasingly used now a days. There is a need for early diagnosis and treatment to avoid perforation and other complications.¹¹ Leukocytosis with the predominance of polymorphonuclear leukocytes accompanies acute appendicitis in most cases, along with elevated C-reactive protein. In our patient, fever was absent, but there was an increase in leukocyte count. Computed tomographic scans obtained to diagnose appendiceal

endometriosis often show a distended appendix without inflammation.¹²

Endometriosis should be considered in the scenario of appendiceal invagination, presence of foreign bodies, inflammation, polyps and neoplasia.⁶ Endometrial involvement of the appendix is usually accompanied by inflammation, fibrosis and hyperplasia or hypertrophy of the muscularis propria.¹³ This hypertrophic segment potentiates hyperperistalsis, which leads to invagination, particularly in a fully mobile appendix with a wide proximal lumen and a fat-free mesoappendix.¹³ Patients often present with chronic intermittent abdominal pain, nausea, vomiting, melena (or "currant jelly stool"), fever or constipation.¹⁴ Occasionally patients are asymptomatic. The radiographic findings are generally normal unless a small-bowel obstruction exists.¹³ Computed tomographic abdominal scans may demonstrate a soft tissue mass in the region of the cecum¹¹

Appendiceal endometriosis is often seen in patients with ovarian endometriosis. Uncu et al studied 125 infertile patients with ovarian endometriosis and performed appendectomy in 65 of them. Thirteen of the appendectomy pathological specimens revealed appendiceal endometriosis, which has led to a discussion whether to perform elective appendectomies in patients who have undergone gynaecological operations because of endometriosis.¹³

Endometriosis of the appendix has been reported to have a high incidence of association with leiomyoma of the uterus and menstrual abnormalities.³ Some authors have reported cases of endometriosis with symptoms of abdominal pain with menstruation.^{4,5} However, our patient had no history of these abnormalities and her symptoms did not coincide with menstruation.

Appendiceal endometriosis is diagnosed microscopically with foci of endometrial glandular tissue and endometrial stroma, with hemorrhage within the wall of the appendix.⁶ Muscular and seromuscular involvement occurs in two-thirds of patients, while serosa is involved in only one-third of the patients and mucosa is not involved. But Luzier et al found submucosal involvement in one-third of patients with endometriosis of the appendix.¹⁴ They also reported the endometriotic foci in the muscle layer and serosa and found no correlation between the location of the endometriotic foci and the patients symptoms. Therefore, mucosal or submucosal endometriosis is much more likely to mimic primary inflammatory diseases such as Crohn's disease, infectious or ischemic enteritis or colitis, or mucosal prolapse than endometriosis of the outer bowel wall.^{13,14} Our patient of appendiceal endometriosis showed grossly small nodules in the wall of the appendix with microscopic evidence of endometrial glands surrounded by endometrial stroma in the serosa.

Appendiceal endometriosis appears to be an incidental finding and one that is not clinically

important.¹³ Abdominal pain in young women can present as a unique diagnostic dilemma. A thorough history and physical examination including a gynecologic examination is key to determining the etiology of pain. The differential diagnosis should include ectopic pregnancy, endometriosis, ovarian torsion, or pelvis inflammatory disease, keeping in mind that they may be concurrent with acute appendicitis or other surgical diseases.^{4,5,8}

The treatment of appendiceal endometriosis is surgery and hormone therapy. The treatment tends to be determined by the age of the patient and the degree of the patient's symptoms. Laparoscopic appendectomy is now commonly performed for appendicitis. Laparoscopic surgery is useful for women with chronic abdominal pain which may be due to endometriosis, ovarian cysts, adhesions and hernias. It enables the exploration of the total peritoneal cavity and the selection of the appropriate method for a definitive diagnosis. A gynaecological assessment should be performed to determine the extent of endometriosis, and postoperative follow-up is mandatory for appendiceal endometriosis. In our patient, the postoperative gynaecological examination did not reveal any other endometriotic lesions.

Conclusion

Endometriosis of appendix is relatively rare. It is most commonly secondary to a primary foci of ovarian endometriosis. A thorough examination to rule out other primary sites should be attempted. With the recent increase in the incidence of appendicitis in young female, clinicians need to be aware of this possibility and consider endometriosis of appendix in the differential diagnosis of acute appendicitis and thus, play a role in the early detection of this disease.

References

1. Boyd CA and Riall TS. Unexpected gynaecologic findings during abdominal surgery. *Current Problems in Surg* 2012;49(4):195-251.
2. Doria AS, Moineddin R, Kellenberger CJ. US or CT for diagnosis of appendicitis in children and adults, a meta-analysis. *Radiol* 2006; 24(1):83-94.
3. Khoo JJ, Ismail MS, Tiu CC. Endometriosis of the appendix presenting as acute appendicitis. *Singapore Med J* 2004;45:435-436.
4. Harris RS, Foster WG, Surrey MW, Agarwal SK. Appendiceal disease in women with endometriosis and right lower quadrant pain. *J Am Assoc Gynecol Laparosc* 2001;8:536-541.
5. Berker B, Lashay N, Davarpanah R, Marziali M, Nezhat CH, Nezhat C. Laparoscopic appendectomy in patients with endometriosis. *J Minim Inv Gynecol* 2005;12:206-209.
6. Uncu H and Taner D. Appendiceal endometriosis: two case reports. *Arch Gynecol Obstet* 2008;278:273-275.
7. Apostolidis S, Michalopoulos A, Papavramidis TS, Papadopoulos VN, Paramythiotis D, Harlaftis N. Inguinal endometriosis: three cases and literature review. *South Med J* 2009;102:206-207.

8. Papavramidis TS, Sapalidis K, Michalopoulos N, Karayanopoulou G, Raptou G, Tzioufa V et al. Spontaneous abdominal wall endometriosis: a case report. *Acta Chir Belg* 2009;109:778-781.
9. Seli E, Berkkanoglu M, Arici A Pathogenesis of endometriosis. *Obstet Gynaecol Clin North Am* 2003; 30: 41-61.
10. Ijaz S, Lidder S, Mohamid W, Carter M, Thompson H. Intussusception of the appendix secondary to endometriosis: a case report. *J Med Case Reports* 2008;2:12-10.
11. Memisoglu K, Karip B, Mestan M, Onur E. The value of preoperative diagnostic tests in acute appendicitis, retrospective analysis of 196 patients. *World J Emerg Surg* 2010;5:5-10.
12. Douglas C and Rotimi O. Extragenital endometriosis a clinicopathological review of a Glasgow hospital experience with case illustrations. *J Obstet Gynaecol* 2004;24:804-808.
13. Idetsu A, Ojima H, Saito K, Yamauchi H, Yamaki E, Hosouchi Y et al. Laparoscopic appendectomy for appendiceal endometriosis presenting as acute appendicitis: report of a case. *Surg Today* 2007;37:510-513.
14. Luzier J, Verhey P, Dobos N. Preoperative CT diagnosis of appendiceal intussusception. *AJR Am J Roentgenol* 2006;187:325-326.