

## Papillary carcinoma of thyroid-an unusual lateral neck presentation

Fefar AD<sup>1,\*</sup>, Gohel U<sup>2</sup>, Mistry SN<sup>3</sup>, Khavdu PJ<sup>4</sup>, Mehta MR<sup>5</sup>

<sup>1</sup>Assistant Professor, <sup>2</sup>Junior Resident, <sup>3,4</sup>Associate Professor, <sup>5</sup>Professor, Dept. of ENT, Head & Neck Surgery,

**\*Corresponding Author:**

Email: dralps.ent@gmail.com

### Abstract

Thyroid carcinoma is the most common endocrine neoplasia. The most common thyroid cancer variant is papillary carcinoma accounting for approximately 85% of cases. Its presentation as cervical cystic mass laterally is extremely rare condition. The cystic change may cause diagnostic dilemma. The aim of presenting this case report is need for doing excision biopsy instead of FNAC in such patients.

**Keywords:** Papillary carcinoma of thyroid, Lateral Neck, Cervical Lymph node

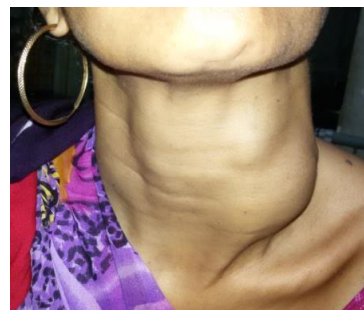### Introduction

Thyroid carcinoma is the most common endocrine neoplasia. The most common thyroid cancer variant is papillary carcinoma accounting for approximately 85% of cases.<sup>(1)</sup> Its presentation as cervical cystic mass laterally is extremely rare condition. The cystic change may cause diagnostic dilemma.<sup>(2)</sup> FNAC may not reveal actual diagnosis always as area of aspiration is limited however this may be reinforced by USG or CT Scan. In such cases surgeon should go for excision biopsy.<sup>(3)</sup>

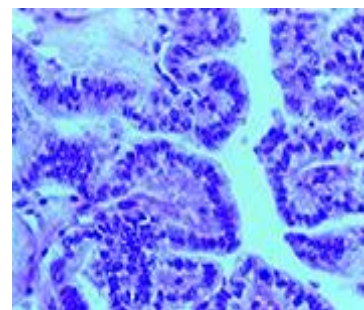
### Case Report

Permission from the institute ethical committee has been taken. A 36-year-old female patient presented in the E.N.T. outpatient department, P. D. U. Medical College, Rajkot, with history of left neck swelling for 4 years which increased progressively in size. Patient has no dysphagia, dyspnea, hoarseness or other significant medical history. Family and personal history is insignificant. On examination there is presence of 8\*6 firm swelling along lateral aspect of neck extending from just above clavicle to thyroid cartilage along sterno-cleido-mastoid muscle on left side. Thyroid function tests were within normal limits. USG revealed few hypoechoic nodules within left thyroid with normal right thyroid and isthmus with approximately 10\*8 cm<sup>2</sup> cystic lesion along left side of neck. Patient was subjected to FNAC which showed nodular goiter with cystic degeneration. CT Scan was suggestive of 26\*17 mm<sup>2</sup> heterogenously enhancing lesion arising from upper pole of the left thyroid gland with another 10\*8 mm<sup>2</sup> cystic lesion in lower pole along with multiple heterogenously enhancing lymphnodes along jugular chain suspected of malignancy. Further S. thyroglobulin value was 6173 ng/ml. Patient underwent total thyroidectomy with left modified radical neck dissection and central compartment clearance. Histopathological examination was suggestive of papillary carcinoma with all nodes free of tumour. She subsequently underwent radioactive iodine therapy postoperatively and a radioactive iodine scan six weeks

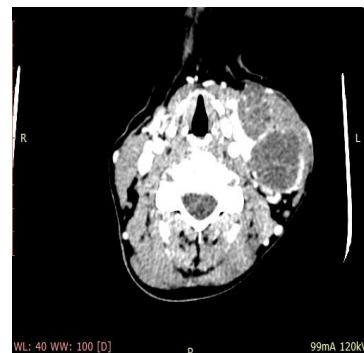later revealed no residual thyroid. The patient is on thyroxine supplementation and regular follow-up.



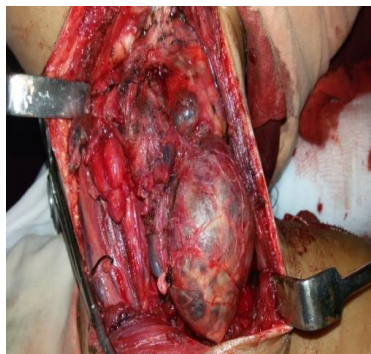**Fig. 1: Clinical photograph of swelling**



**Fig. 2: Histo-Pathological features**



**Fig. 3: CT scan film**



**Fig. 4: Intra-operative photograph**

### Discussion

Papillary carcinoma of thyroid occurs mainly between 2<sup>nd</sup> to 5<sup>th</sup> decades of life with female having 3 fold preponderance. Numerous etiological factors like high dose radiation, genetic factors, iodine deficiency etc have been associated. Genetic defect includes RET Proto oncogene activation, B-RAF, RAS mutation is found. It stains with cytokeratin, thyroglobulin on immunohistochemistry. Approximately 25% of papillary carcinomas are occult, discovered incidentally at surgery.<sup>(4,5)</sup> The appearance of a solitary lateral cervical cystic mass as the only initial presenting symptom of occult thyroid carcinoma is extremely rare, with approximately 40 cases previously reported in the literature.<sup>(6)</sup> Papillary thyroid carcinoma is a malignant epithelial tumour showing follicular cell differentiation with characteristic nuclear features i.e. orphan annie nuclei and psammoma bodies. It has got histological variant like tall cell, follicular, solid, encapsulated, diffuse sclerosing, clear cell, trabecular.<sup>(1)</sup> FNAC is less sensitive in the diagnosis of cystic neck masses compared with solid masses.<sup>(6)</sup> FNAC is taken from only small area, particularly in cystic swelling fluid will be aspirated. Solid area may not be inspected. So cervical cystic swelling should always be subjected to

excision for histological examination. Papillary carcinoma carries an excellent prognosis with more than 95% -10 year survival rate especially in younger patients.<sup>(7)</sup>

### Conclusion

Clinician should always have high degree of suspicious for malignancy in patient presenting with lateral neck cyst. FNAC has limited role in diagnosis for cystic lateral neck swelling. Excision should be done in such cases.

We declare no conflict of interest in any form.

### References

1. Robert A. Hendrix, Diseases of the Thyroid and Parathyroid Glands Che: 63: Ballenger's Otolaryngology Head and Neck Surgery, Sixteenth ed. p. 1455-1483, BC Decker.
2. H. Seven, A. Gurkan, U. Cinar, et al. Incidence of occult thyroid carcinoma metastases in lateral cervical cysts. Am J Otol, 25 (2004), pp. 11-17.
3. American Thyroid Association (ATA) Guidelines Taskforce on Thyroid Nodules and Differentiated Thyroid Cancer, Cooper DS, Doherty GM, Haugen BR, et al. Revised American Thyroid Association management guidelines for patients with thyroid nodules and differentiated thyroid cancer. Thyroid 2009; 19:1167-1214.
4. Robbins and Cotran PATHOLOGIC BASIS OF DISEASE, Seventh Edition, Elsevier.
5. Coleman SC, Smith JC, Burkey BB, Day TA, Page RN, Nettekville JL. Long standing lateral neck mass as the initial manifestation of well-differentiated thyroid carcinoma. Laryngoscope. 2000 Feb; 110(2 Pt 1):204-9.
6. Chi HS, Wang LF, Chiang FY, Kuo WR, Lee KW. Branchial cleft cyst as the initial impression of a metastatic thyroid papillary carcinoma: two case reports. Kaohsiung Med Sci 2007;23:634-638.
7. Sharanappa V, Tambat RM, Srinivas NM, Razack A. Clinical Presentation of Papillary Carcinoma Thyroid as a Lateral Neck Cyst: Case Report. IOSR-JDMS; Volume 13, Issue 12 Ver. VIII (Dec. 2014), PP 42-46.