

Ultrasound guided internal jugular vein cannulation with short and long axis approach- Technical ease and complications

Madhavi Sanjay Chaudhari^{1*}, Sanket Bharat Shah², Hemlata Vithal Kamat³

¹Professor, ²Consultant Anaesthesiology, Vadodara, ³Professor, Dept. of Anaesthesiology, Pramukhswami Medical College, Gujarat

***Corresponding Author:**

Email: madhavic@charutarhealth.org

Abstract

Introduction: Central venous cannulation is commonly performed procedure on critically ill patients. Of the two methods, landmark technique and ultrasound (USG) guided latter increases success rate and decreases complications associated with the procedure.

Ultrasound guided cannulation can be done in short or long axis approach. In the short axis approach, both artery and vein can be simultaneously viewed and hence would have less chances of arterial puncture. In the long axis approach only one vessel and the entire length of the needle is visualized and therefore there would be less chances of posterior wall puncture.

In this prospective randomized observational study USG guided internal jugular vein (IJV) cannulation was done by trainees (post graduate students). The aim of this study was to find the incidence of successful cannulation and incidence of complications by short and long axis approach.

Materials and Method: Fifty patients were randomly allocated into two groups, short axis and long axis. All the patients were cannulated by Seldinger technique and free flow of blood was confirmed through all the ports.

Results: Demographic variables were comparable between the two groups. On first attempt 92% of patients in long axis and 76% of patients in short axis were cannulated. In both the groups, remaining patients were cannulated on second attempt and large number of patients had arrhythmias. Four patients had arterial puncture in short axis group but none was seen in long axis group.

Conclusion: All patients were successfully cannulated. Higher first attempt successful cannulation and overall less complication were seen in long axis approach but the difference was not statistically significant.

Keywords: Internal jugular vein, Cannulation, Ultrasound, Short axis, Long axis

Introduction

Central venous cannulations (CVC) on critically ill patients is preferably done under real-time ultrasound guidance by a variety of medical specialities.⁽¹⁻⁷⁾ Blind surface landmark guided CVC is challenging in obese, swollen neck, coagulopathies, previous radiotherapy and scars. Several meta-analysis that reviewed landmark versus USG guided IJV cannulation demonstrated relative risk reductions in complications, higher proportion of successful cannulations on first attempt with shorter average time for cannulation with ultrasound.⁽⁸⁻¹¹⁾ The National Institute for Clinical Excellence published guidelines supporting the routine use of ultrasound for IJV cannulation. It is not known which scanning axis, short or long, provides the optimal conditions for vascular access. Few studies are available regarding comparison of short and long axis. Blavias et al did study on phantom limb, in which there are fixed and specific locations of the vessels while in humans there would be anatomic variants.⁽¹²⁾ Study done by Suresh Chittoodan on elective cardiac patients, comparing short versus long axis approach for IJV cannulation did not reveal specific results.⁽¹³⁾ So we analysed which approach, whether short or long axis would be better in general population where IJV cannulation was performed by trainees. The aim of the study was to compare the two approaches and know the

incidence of successful cannulation and incidence of complications.

Materials and Methods

This prospective randomized observational study of 50 patients was conducted after IEC approval, in a tertiary care centre. Patients with failed peripheral venous access, requiring access for frequent blood sampling, monitoring the trend of CVP, irritant hyperosmolar drug and fluid administration, haemodialysis and plasmapheresis were included in the study. Patients having infection at local site, post-radiotherapy, History of prior long term IJV cannulation, radical neck dissection, pacemakers, thrombus in IJV and malfunctioning of USG machine were excluded from the study.

After obtaining written and informed consent from the patient or relatives as in intubated and patients with altered mental status, under all aseptic precautions USG guided IJV cannulation using vascular high frequency probe was performed by 2nd/3rd year anesthesia resident doctor. The whole procedure was performed under the guidance and supervision of anesthesia consultant having experience of five years or more in landmark technique and experience of two years or more in ultrasound guided cannulation.

Patients were divided into two groups, short axis and long axis as per computerized randomization. In the

short axis approach, the long axis of the transducer was perpendicular to the long axis of the vessel (Fig. 1). Initially the transducer was placed at the apex of the triangle formed by two heads of sternocleidomastoid muscle and scrolled down till the place where IJV and carotid artery were side by side (Fig. 2). In both the groups, vein was confirmed by compressibility test and with characteristic doppler signal of venous hum. On ultrasound, artery was visualized as round, pulsatile, non-compressible, anechoic with characteristic doppler signal of pulsatile waveform (Fig. 3). In the short axis approach, needle entry was at contact with a 45° to 60° angle to the skin (Fig. 4). Indentation of the anterior internal jugular vein wall was checked and needle tip visualization was done. In the long axis approach the transducer was rotated 90° after initial short axis view (Fig. 5). Needle entry, parallel to the ultrasound probe was 0.5 cm rostral to probe edge at 30° to 45° from skin (Fig. 6). The full length of the needle was seen traversing the skin and entering the anterior wall of IJV (Fig. 7).

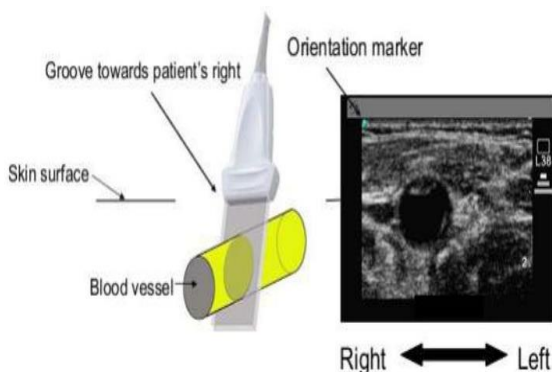


Fig. 1: Transverse transducer orientation with short axis ultrasound appearance

Only after ensuring continuous venous blood aspiration and fixing the needle hub with thumb and finger, the guide-wire was threaded through the needle. Approximately half the length of guide wire was inserted. Throughout the procedure, patient was monitored for any cardiac arrhythmias. Confirmation of the venous placement was done by visualizing guide-wire in the lumen of vein using ultrasound probe, after which the needle was withdrawn.

Guide wire was seen as a dot in the lumen of the vessel in short axis approach (Fig. 8). A nick was made on the skin with scalpel and the skin and subcutaneous track dilated with dilator. After removing dilator, the catheter was passed over the guide-wire. Then guide-wire was removed. Blood return was confirmed through all ports and flushed with saline. When there was bright

red colour or pulsatile blood flow, it confirmed the arterial puncture. So, the needle was removed and pressure was applied for 5-10 minutes. An attempt was counted as separate skin puncture. Successful cannulation of the vein was considered as free flow of blood through all the ports. The catheter was securely sutured in place and sterile transparent dressing was applied over it. Bilateral breath sounds were confirmed. Post procedure chest X-ray was done of all patients to see whether any complications had occurred. Post procedure all details regarding IJV cannulation were noted, including number of attempts and the complications which occurred with each approach.

Statistical Analysis: Both the groups of patients were compared by “t” test, chi square test.

Results

We studied 50 cases in two equal groups, short axis and long axis. Most of the procedures (86%) were performed in SICU and remaining in OT, in both the groups (Fig. 9). The mean age in long axis approach was (47.64+18.93) years and in short axis approach was (51.52+19.37) years. The mean weight in long axis approach was (55.20+7.74) kgs and in short axis approach was (59.56+10.09) kgs. 16 out of 25 patients in short axis were males while in long axis 12 out of 25 were males (Fig. 10).

In the first attempt, in the long axis approach 23 out of 25 patients (92%) and in the short axis approach 19 out of 25 patients (76%) were successfully cannulated. 2 patients in long axis approach and 6 patients in short axis approach were successfully cannulated on second attempt. No statistically significant difference was found in mean number of attempts for CVC in between both the approaches using independent sample T test (Table 1).

Table 1: Comparison of number of attempts by short axis and long axis

Approach	Number of patients	Mean number of attempts (SD)	p value
Long axis	25	1.08 (0.277)	0.128
Short axis	25	1.24 (0.436)	

Procedural complications in our study were noted in individual approach and then compared. Arrhythmias occurred in 56% of patients in short axis and 44% in long axis approach, and chi square test was used to compare them (Table 2).

Table 2: Comparison of number of patients with arrhythmia in short axis and long axis approach

Approach	Arrhythmia (%)	No arrhythmia (%)	p value
Short axis	14 (56%)	11 (44%)	0.396
Long axis	11 (44%)	14 (56%)	

One out of 25 patients in short axis and 3 out of 25 patients in long axis had difficulty in passing guidewire. In long axis approach, there was no difficulty in aspiration of blood but in short axis one patient was noted. Difficulty in visualization of vein was recorded in 5 patients and 3 patients in short axis and long axis approach respectively. Four patients in short axis had arterial puncture while in long axis there was none.

Of the total 50 patients, 22 patients had no complications (12 and 10 in long and short axis respectively). In long axis approach, the maximum number of complications in one patient was two; while in short axis approach 2 patients had three complications each (Fig. 11). Mean number of complications in patients with systolic blood pressure (SBP) less than or equal to 90mmHg and with SBP more than 90 mmHg in short axis and long axis approach was compared using individual T test and revealed no statistical difference (Table 3).

Table 3: Comparison of mean number of complications for short axis and long axis approach according to blood pressure

Systolic Blood Pressure	Short axis approach		Long axis approach		p value
	Number of patients	Mean number of complications (SD)	Number of patients	Mean number of complications (SD)	
Less than or equal to 90	6	1.33 (0.816)	4	1.00 (0.816)	0.545
Greater than 90	19	0.89 (1.049)	21	0.62 (0.740)	0.339

Discussion

CVC is a commonly performed procedure on critically ill patients in ICU and OT, by anesthesia residents during their training. Landmark technique for CVC can lead to a variety of complications such as hematoma, pneumothorax, arterial puncture, hemothorax, chylothorax, brachial plexus injury, air embolism, catheter malposition, catheter knotting, dysrhythmias, and arteriovenous fistula.⁽¹⁴⁾ Several attempts may be required at one location or involving several different sites. The NICE guidelines has advised that ultrasound guidance be used for CVC to decrease morbidity and mortality associated with the procedure.⁽¹⁵⁾ Real-time US guidance of CVC insertion provides the operator with visualization of the desired vein and the surrounding anatomic structures prior to and during the insertion of the catheter. This method appears to improve the success rate and decrease the complication rate associated with CVC placement. Using ultrasound, Denys and Uretsky⁽¹⁶⁾ found that 8.5% of 200 patients had abnormal IJV anatomy, with a small fixed IJV in 3%, no right IJV at all in 2.5%, an IJV medial to the carotid in 2% and an IJV lateral to the carotid with no overlap in 1%. The position of the IJV in relation to the carotid artery shows high variability (Fig. 12). In the majority of patients, the IJV lies lateral to the carotid artery; as one moves more cranially, it comes closer and sometimes even anterior to the carotid artery. In up to 5%, the position might even be medial to the carotid artery. These common anatomic variants may explain the higher complication rates and need for multiple attempts to achieve success using the landmark technique alone.

Ultrasound-guided internal jugular vein cannulation can be performed using two approaches: short axis (needle out-of-plane) or long axis (needle-in-plane). There are advantages and disadvantages to each approach.

In the short axis approach, both the artery and vein can be simultaneously viewed and minimal probe adjustment is required. There would be less chances of arterial puncture. However, during cannulation the needle may not be seen as it is advanced out of the scanning plane. Therefore needle tip location is based on visualisation of tissue movement and educated guess work.

With the long axis view, however, the operator advances the needle in the long axis of the scanning beam and can visualise the entire length of the needle as it punctures the target vessel. Although needle visualisation is improved, the acquisition of the long axis image of the internal jugular vein is technically more difficult than the short axis view. Using the long axis view, information regarding the location of the carotid artery relative to the internal jugular vein may be lost. Therefore correct identification of the single vessel in the scanning field is essential.

In our study, the mean number of attempts in short axis was 1.24 and in long axis was 1.08 (P value was 0.128) which was statistically not significant.

However in Suresh Chittoodan et al⁽¹³⁾ first attempt was higher in short axis (98%) as compared to long axis (78%). The procedures were performed by experienced anesthetists and were done on patients specific for elective cardiac surgery. So due to experience of the anesthetists, short axis would have been a better approach with lesser attempts. In our study procedures were done by inexperienced anesthetists.

Tarek F Tammam et al⁽¹⁷⁾ did a similar study in which he compared short axis and long axis and also compared both of this approaches with landmark technique. The study revealed no major difference in short axis (1.13) and long axis (1.17) for mean number of attempts but for landmark technique number of attempts were 2.57 far higher than ultrasound guided short axis and long axis, which proved superiority of

ultrasound guided central venous cannulation compared to landmark technique.

In the study done by Blavias et al,⁽¹²⁾ mean number of attempts in short axis were 4.18 and for long axis was 5.76. This study was done on inanimate model and there would be no anatomic variations on the location of the vessels and the procedure was performed by emergency medicine residents who were not well trained in ultrasound.

In our study 4 out of 25 patients in the short axis group had inadvertent arterial puncture. There was no arterial puncture in the long axis approach. So long axis may be considered a better approach if arterial punctures are to be avoided, provided correct identification of vein is done prior to needle insertion.

Tarek F Tammam et al⁽¹⁷⁾ in his study had only 1 arterial puncture in ultrasound guided short axis group and 7 cases in landmark technique.

Suresh Chittoodan et al⁽¹³⁾ in his study had 4% inadvertent arterial puncture in long axis approach which was different from our study. The explanation for this may be only one vessel was visualized in long axis view on the ultrasonography screen which can be confused for the vein.

In our study, there were 10 patients in whom blood pressure was less than 90mm Hg during cannulation. The mean number of complications was 1.33 in short axis approach and 1.00 in long axis approach; p value was 0.545 which was statistically not significant. But overall the total number of complications was less in long axis approach and so long axis approach may be better in hypotensive patients as the needle would be seen traversing along the whole length and the chances of posterior wall puncture would be less. In short axis approach the vein would be more easily compressed during hypotension and, and sometimes inadvertent arterial puncture is likely, if artery is just posterior to the vein.

Michael B Stone et al⁽¹⁸⁾ described that ultrasound guided cannulation by short axis approach may lead to inadvertent posterior wall puncture and also arterial puncture. This study was done on residents who performed on phantom limbs. In short axis the person may lose the track of the needle and may cause inadvertent arterial puncture if he is not well versed with ultrasound machine.

There was no complication of pneumothorax in any of the approach in our study. Tarek F Tammam et al⁽¹⁷⁾ also had no pneumothorax in both approaches. However in his study 1 patient had pneumothorax in landmark group.

In our study of the total 50 patients, 22 patients had no complications. Out of these 22 patients, 12(48%) were in long axis approach and 10(40%) in short axis approach. 16 patients had single complication, of which 7 were in short axis and 9 in long axis approach. 10 patients had two complications each, of which 6 were in short axis and 4 in long axis approach. There were only

2 patients with three complications each, both of them were in short axis approach. In long axis approach there were no patients with 3 complications. Thus overall patients with long axis approach had lesser number of complications.

In our study, in short axis approach 14 patients had arrhythmia while in long axis approach 11 patients had arrhythmia.

Ideally arrhythmia should not be relied as a correct sign of central venous cannulation. Guide wire insertion to a greater extent may lead to cardiac tamponade or vessel tear. However in our study no patient had major complication like tamponade or vessel tear. According to the recent references guide wire should not be inserted more than 16cm from skin in right internal jugular vein cannulation.⁽¹⁹⁾

Importantly, additional approaches to vascular access, most notably an oblique approach and a more dynamic approach in which the provider switches freely between short axis and long axis approach views to maximize visibility of needle tip and accuracy of needle direction seems more logical in minimizing the rate of complications. Although, these alternate approaches merit investigation, these approaches require additional dexterity on the part of the performer and may involve appropriate training to novice sonologists. These techniques can then be prospectively evaluated with traditional short and long axis approaches.

Strengths of our study

In our study, all the procedures performed by trainees were successful on second attempt with no life threatening complications in both the approaches, under the guidance and supervision of experienced consultants.

Limitations of our study

Limited number of patients studied over a limited period of time and procedure performed by inexperienced anesthetists. We did not include the time duration and difficulty scale for cannulation.

Future research may explore the role of novel technology such as 3/4D imaging which may further facilitate advances in ultrasound-guided vascular access.⁽⁶⁴⁾

Conclusion

All the patients were successfully cannulated. Both the approaches can be compared for their merits and demerits, but no single approach can be considered as best approach as the present study did not find statistically significant difference between the two approaches in terms of success and complications of cannulation.

Financial support and sponsorship

Nil

Conflicts of interest

There are no conflicts of interest.

References

1. Vincent JL, Bihari DJ, Suter PM, et al. The prevalence of nosocomial infection in intensive care units in Europe. Results of the European prevalence of Infection in Intensive Care study. EPIC international advisory committee. *JAMA* 1995;274:639-44.
2. Etheridge SP, Berry JM, Krabill KA, Braunlin EA. Echocardiographic guided internal jugular vein cannulation in children with heart disease. *Arch Pediatr Adolesc Med* 1995;149:77-80.
3. Verghese ST, McGill WA, Patel RJ, et al. Ultrasound guided internal jugular vein cannulation in infants: a prospective comparison with the traditional palpation method. *Anesthesiology* 1999;91:71-7.
4. Hind D, Calvert N, Mc Williams R, et al. Ultrasonic locating devices for central venous cannulation: meta analysis. *BMJ* 2003;327-361.
5. Hatfield A, Bodenham A. Portable ultrasound for difficult central venous access. *Br J Anaesth* 1999;82:822-6.
6. Randolph AG, Cook DJ, Gonzales CA, Pribble CG. Ultrasound guidance for placement of central venous catheters: a met analysis of the literature. *Crit Care Med* 1996;24:2053-8.
7. Kwon TH, Kin YL, Cho DK. Ultrasound guided cannulation of femoral vein for acute haemodialysis access. *Nephrol Dial Transplant* 1997;12:1009-12.
8. Hrics P, Wilber S, Bland MP, Gallo. Ultrasound assisted internal jugular vein catheterisation in the ED. *Am J Emerg Med* 1998;16:401-3.
9. Mallory DL, McGee WT, Shawker TH, et al. Ultrasound guidance improves the success rate of internal jugular vein cannulation. A prospective randomized trial. *Chest* 1990;98:157-60.
10. Slama M, Novara A, Safavian A, et al. Improvement of internal jugular vein cannulation using an ultrasound guided technique. *Intensive care Med* 1997;23:916-19.
11. Rothschild JM. Ultrasound guidance of central vein catheterisation. Agency for Healthcare research and Quality. Available at www.ahrq.gov/clinic/ptsafety/pdf/chap21.pdf.
12. Blavias M, Brannam L, Fernandez E. Short axis versus Long axis approaches for teaching ultrasound guided vascular access on a new inanimate model 2003;10(12):1307-11.
13. Chittoodan S, Breen D, Donnell BDO, Iohom G. Long versus Short axis ultrasound guided approach for internal jugular vein cannulation: A prospective randomized controlled trial. 2011;13(1):21-5.
14. Eisen L, Narasimhan M, Berger JS, Mayo PH, Rosen MJ, Schneider RF. Mechanical complications of central venous catheters. *J. Intensive Care Med* 2006;21:40-46
15. National Institute for Clinical Excellence. Guidance on the use of ultrasound locating devices for placing central venous catheters. London: NICE 2002. NICE Technology Appraisal No 49.
16. Denys BG, Uretsky BF. Anatomical variations of internal jugular vein location: Impact on central venous access. *Crit Care Med* 1991;19:1516-9.
17. Tarek F Tammam, Eid M El-Shafey, Hossam F Tammam. Ultrasound- Guided Internal Jugular Vein Access: Comparison between Short Axis and Long Axis Techniques. *Saudi J Kidney Dis Transpl* 2013;4(4):707-713.
18. Michael B, Stone MD, Cynthia Moon MD, Darrell Sutijono MD, Michael Blavis MD: Needle tip visualization during ultrasound guided vascular access: short axis vs. long axis approach. *American Journal of Emergency medicine*.2010;28,343-47.
19. Andrews RT, Bova DA, Venbrux AC. How much guidewire is too much? Direct measurement of the distance from subclavian and internal jugular vein access sites to the superior vena cava-atrial junction during central venous catheter placement. *Crit Care Med*. 2000 Jan;28(1):138-42.