

## Research Communication

# Human Scapulae: Supra Scapular Notch, Morphometry and Variations

\*Dushyant Agrawal<sup>1</sup>, Brijendra Singh<sup>1</sup>, Gitika Arya Agrawal<sup>2</sup>

<sup>1</sup>Department of Anatomy, All India Institute of Medical Sciences (AIIMS), Jodhpur, India

<sup>2</sup>Dr.SarvepaliRadhakrishnan Rajasthan Ayurveda University, Jodhpur, India

### \*Corresponding author:

Dr. Dushyant Agrawal, Assistant Professor, Department of Anatomy,

All India Institute of Medical Sciences, Basni phase -2, Jodhpur – 342005 (Rajasthan) India

Email id: dushyantanatomy@gmail.com

### Abstract:

**Aim:** This present study meant to describe different shape and dimensions of suprascapular notch, and to classify different types of scapula on the basis of notch.

**Material & Methods:** 293 dried scapulae were observed, examined and studied in detail. Scapulae with supra-scapular notch were included in the present study. Measurements of suprascapular notch were taken with the help of digital Vernier calliper and recorded in millimetres. The superior transverse diameter, Inferior transverse diameter of supra scapular notch, depth were recorded. The data was analyzed statistically.

**Observations & Results:** We observed five types of notch in scapulae, type I: without a discrete notch (ill defined), 36 (12.28%), type II: a 'V' shaped notch, 69 (23.54%); type III: 'U' shaped notch, 132 (45.0%); type IV: inverted 'V' shaped notch, 52 (17.74%); type V with absent supra scapular notch: 4(1.36%).

**Conclusion:** The present classification of the suprascapular notch is simple, easy to use, and based on specific dimensions which help to clearly distinguish five types of these structures. This study will also help clinicians to correlate suprascapular nerve entrapment with a specific type of suprascapular notch.

**Keywords:** Suprascapular notch; suprascapular foramen; suprascapular nerve, Scapula

## Introduction

The scapula (shoulder blade) is a triangular flat bone that lies on the posterolateral aspect of the thorax, overlying the 2nd to 7th ribs. The convex posterior surface of the scapula is unevenly divided by the spine of the scapula into a small supraspinous fossa and a much larger infraspinous fossa. The concave costal surface of the scapula has a large subscapular fossa. The triangular body (blade) of the scapula is thin and translucent superior and inferior to the scapular spine. The suprascapular notch is situated in the lateral part of the superior border of the scapula, just adjacent to the base of the coracoids process. This notch is converted into a foramen by the superior transverse scapular ligament and serves as a passage for the suprascapular nerve.

This foramen transmits the suprascapular nerve to the supraspinous fossa, whereas the suprascapular vessels pass above the ligament. Suprascapular nerve supplies supraspinatus and infraspinatus muscles as well as sensory branches to the shoulder and acromioclavicular joint.

Morphological variations of the suprascapular notch are very important clinically because of one of the predisposing factors for compression of the suprascapular nerve in this region. Suprascapular nerve neuropathy is a common symptomatic presentation in some individuals who have been involved in violent overhead activities, using that particular upper limb. The size and shape of the SSN has been supposedly a factor in suprascapular nerve entrapment because narrow SSNs have been commonly observed in patients with this syndrome. [2, 6, 12, 21]

Many of the previous studies observed variations in suprascapular notch studies. Six

different types of anatomical variations of the suprascapular notch have been reported in Nigerian population by Bayramolu et al. [1]. Polguj M reported complete absence of the suprascapular notch [12].

Rengachary et al. classified the suprascapular notch (SSN) into six types based on the shape of the notch and ossification of superior transverse scapular ligament (STSL) [15, 16]. Ticker et al. and Bayramoglu et al. modified the classification of Rengachary et al. and included only U- shaped notch and V -shaped notch, and the notch with ossification of the superior transverse scapular ligament (STSL) [1,15,16, 19]. Natsis et al. and Michael Polguj had established a new method of classifying SSN morphology by using specific geometrical parameters [10]. Hua-Jun Wang et al. had also classified SSN according to Natsis' method and also studied the bony canal [14, 20].

GargSoni et al., Surekha, Muralidhar et al. and Lajja et al.classified SSN based on Rengachary et al. , Natsis et al. and Ticker et al. classification [5,8,10, 15,16, 18, 19] in Indian population.

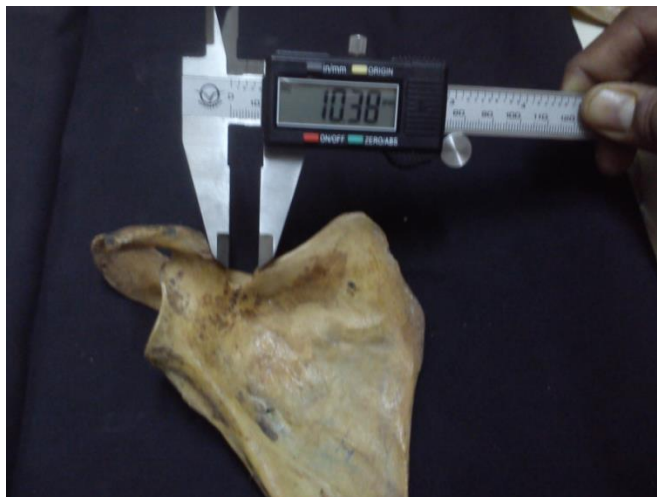### Material and Methods

The present study comprised of detailed work done on 293 dried adult north Indian human scapulae, in which suprascapular notch morphology was observed. These scapulae were obtained from museum of Department of Anatomy in various medical colleges used for under graduate teaching purposes. These bones were of unknown age and sex.

This study also includes scapulae where suprascapular notch was absent. The scapulae with broken superior border were excluded from this study. Measurements of suprascapular notch were made using classic osteometry with the digital Vernier calliper and these were recorded in millimetres. Digital Vernier caliper (manufacturer – Aerospace, India) used in this study was of resolution of 0.01mm. The data was analyzed statistically (figure 1 & 2).



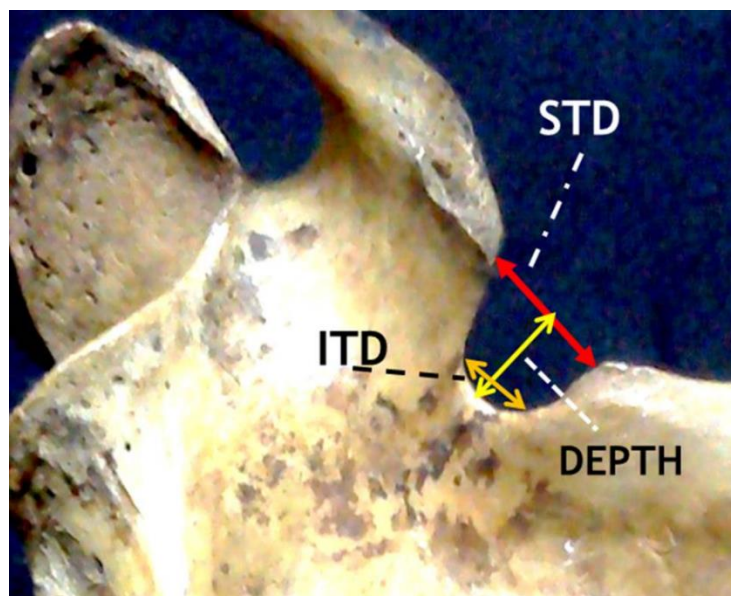
**Figure 1:** Measurement for depth of Supra Scapular Notch



**Figure 2:** Measurement for Superior transverse diameter of Supra Scapular Notch

Measurements taken for each suprascapular notch and superior transverse scapular bar are as follows-

1. **The superior transverse diameter** - maximum distance between superior most edges of suprascapular notch (SSN). (Figure: 3)
2. **The inferior transverse diameter** - maximum distance between the edges of the curved arch at the base of the SSN. (Figure: 3)
3. **Depth** -maximum vertical distance between deepest point at the base of suprascapular notch to an imaginary line between superior edges of notch. (Figure: 3)



**Figure 3:** Dimensions measured for Supra Scapular Notch,

STD: Superior Transverse Diameter, ITD: Inferior Transverse Diameter, Depth

## Results

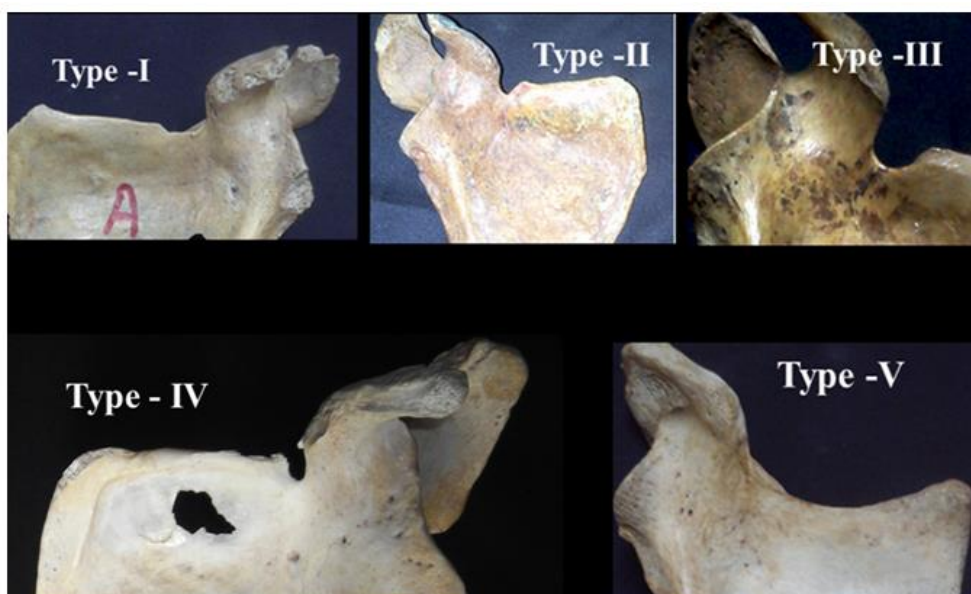By gross examination and measurements we classified 293 into different types according to shape and presence of suprascapular notch (table -1).

**Table 1:** Classification of scapulae (n=293) according to shape of Suprascapular Notch

|  | No. of Scapulae (%) | Right sided Scapulae | Left sided Scapulae |
|--|---------------------|----------------------|---------------------|
| Type I (without Discrete SSN)<br>Figure : 1              | 36 (12.28%)         | 22                   | 14                  |
| Type II ( STD > ITD )<br>Figure : 2 (V-shaped)           | 69 (23.54%)         | 45                   | 24                  |
| Type III ( STD $\approx$ ITD )<br>Figure : 3 (U-shaped)  | 132 (45.0%)         | 88                   | 44                  |
| Type IV ( STD < ITD )<br>Figure : 4 (Inverted- V-shaped) | 52 (17.74%)         | 24                   | 28                  |
| Type V (SSN absent)<br>Figure : 5                        | 4(1.36%)            | 4                    | 0                   |

(STD: Superior Transverse Diameter, ITD: Inferior Transverse Diameter, SSN: Supra Scapular Notch)

Type -I (n= 36) were without discrete shaped suprascapular notch (ill defined –not having continuous margin). Type -II – V shaped (n=79, having wide superior transverse diameter, narrow inferior transverse diameter) and Type -III – U shaped (n= 132, having nearly equal superior & inferior transverse diameter) (figure – 4). Measurement value of Superior, inferior transverse diameter and depth are showing in table -2.



**Figure 4:** Photographs showing different type of Supra scapular notches (Type 1: without discrete notch, Type 2: 'V' shaped, Type 3: 'U' shaped, Type 4: Inverted 'V' shaped, Type 5: Without Notch)

**Table 2:** Dimensions in different type of Supra Scapular Notches

| Types of Scapula                | Superior Transverse Diameter (STD) | Inferior Transverse Diameter (ITD) | Depth of Supra Scapular Notch (D) |
|---------------------------------|------------------------------------|------------------------------------|-----------------------------------|
| <b>Type I</b>                   | 10.36 ± 1.98 mm                    | 9.23 ± 1.56 mm                     | 3.65 ± 0.88 mm                    |
| <b>Type II ( STD &gt; ITD )</b> | 9.80 ± 1.68 mm                     | 5.12 ± 0.32 mm                     | 7.32 ± 1.44 mm                    |
| <b>Type III ( STD ≈ ITD )</b>   | 9.54 ± 1.42 mm                     | 8.56 ± 1.72 mm                     | 6.88 ± 1.02 mm                    |
| <b>Type IV ( STD &lt; ITD )</b> | 3.16 ± 0.64 mm                     | 6.28 ± 0.68 mm                     | 4.24 ± 0.62 mm                    |

(STD: Superior Transverse Diameter, ITD: Inferior Transverse Diameter)

Type -IV (n=52) were inverted V shaped suprascapular notch (having narrow superior transverse diameter, wide inferior transverse diameter). Suprascapular notch were absent in type – V scapulae (n=4).

### Discussion

Several morphological variations and classifications of the suprascapular notch were reported in various populations.

SSN is commonly bridged by superior transverse scapular ligament, in living which may get ossified sometimes, thus foramen completed and transmits suprascapular nerve to suprascapular fossa. Various factors have been identified as being causes of suprascapular nerve entrapment including variations in suprascapular notch (SSN) along with the variations of suprascapular ligament ossifications [1, 13].

Many of researchers observed morphological variations of SSN and classified them in different populations [Hrdicka, Olivier, Rengachary et al., Ticker et al., Bayramoglu et al., Natsis et al., Sinkeet, Wang and Polguy] [1, 6, 10, 13-17, 19, 24].

Rengachary et al. has classified SSNs into six types, based on its inferior shape as well as the degree of ossification of transverse suprascapular ligament [15, 16], though this classification did not help to clearly differentiate among various types –

Type I – the entire superior border of the scapula shows a wide depression from the medial superior angle to the base of coracoid process,

Type II – a wide, blunt, V-shaped notch,

Type III – a symmetrical, U-shaped notch with parallel margins,

Type IV – a small, V-shaped notch,

Type V – similar to type III with the medial part of the ligament ossified and

Type VI –ligament completely ossified and forming a foramen.

In the present study, Type III supra scapular notch (U-shaped) is more commonly observed (45.0%) and this observation is similar to that of other earlier studies. U shaped notch (type III) was reported in various frequencies by Jadhav et al.in 39.79% , by Iqbal et al. in 14% , Ticker et al. 77%, Bayramoglu et al. 62.5 % , Duprac et al.63.3 % , Muralidhar et al. 69.23% in past [1,4, 7, 9, 18, 19].

In our study (Table-1), second common type of SSN observed is type II (V-shaped – 23.54%), which is similar to the observations of Rengachary et al. and Natsis et al., but differed

to the findings of Sinkeet et al. described type I SSN as the second common type [10, 15-17].

In the present study Type V SSN (1.36 %) observed that it is the least common type, which is different to that of Rengachary et al. and Sinkeet et al., who observed type VI as the least common type of supra scapular notches [15-17].

Type VI supra scapular notch reported by Rengachary et al. was defined as the notch with complete ossification of transverse scapular ligament (transverse scapular bar) forming suprascapular foramen [15].

On the other hand, following examination of 423 scapulae, Natsis et al. proposed a classification [10]:

- Type I – without a discrete notch,
- Type II – a notch with the longest transverse diameter,
- Type III – a notch with the longest vertical diameter,
- Type IV – a bony foramen
- Type V – a notch and a foramen.

In our study, the presence of both supra scapular notch and the supra scapular foramen together in same scapula was not observed.

In the present study, superior transverse diameter (STD) of the notch was greater than the inferior transverse diameter (ITD) in 23.54 % scapulae, lesser in 17.74% and equal in 45.0% scapulae.

A reduction in the height of suprascapular foramen may predispose to entrapment of suprascapular nerve. Dunkelgrun et al. stated that the U-shaped notch had a larger area than the V-shaped notch, which was the reason that the V-shaped notch was more likely to be associated with suprascapular nerve entrapment [3]. In present study we observed that the U-shaped notch was more common (45.0%) than the V-shaped notch (23.54%) and inverted V-shaped notch (17.74%). These observations are almost similar to those of other studies done in past as has been shown in Table-3.

Though, exact cause of various shapes of SSN is not clear but Odita et al. suggested that the ossifications of the coracoid process and epiphysis influence the shape of the SSN and it could be the cause of the population difference [11]. In conclusion, knowing the anatomical variations in detail is better for understanding of location and source of the entrapment syndrome.

**Table 3:** Comparative distribution U and V type of notches in different studies

| <b>Name of Study</b> | <b>U-type</b> | <b>V-type</b> |
|----------------------|---------------|---------------|
| Duparc [4]           | 63.3%         | 36.7%         |
| Bayramoglu [1]       | 62.5%         | 25%           |
| Ticker et al [19]    | 77%           | 23%           |
| Muralidhar [9]       | 69.23%        | 26.92%        |
| Present Study        | 45.0%         | 23.54%        |

**Note:** No potential conflict of interest relevant to this article was reported

## References

1. Bayramolu, A., Demiryürek, D., Tüccar, E., Erbil, M., Aldur, MM., Tetik, O. and Doral, MN., 2003, Variations in anatomy at the suprascapular notch possibly causing suprascapular nerve entrapment: An anatomical study. *Knee Surg Sports Traumatol Arthroscopy*, 2003, vol. 11, p. 393-8.
2. Bhatia DN, de Beer JF, van Rooyen KS, Du Toit DF, 2006. Arthroscopic suprascapular nerve decompression at the suprascapular notch. *Arthroscopy*, 22: 1009-1013.
3. Dunkelgrun M, Lesaka K, Park SS, Kummer FJ, Zuckerman JD. Interobserver reliability and intraobserver reproducibility in suprascapular notch typing. *Bull Hosp Joint Dis*. 2003; 61: 118-22.
4. Duparc F, Coquerel D, Ozeel J, Noyon M, Gerometta A, Michot Ch. Anatomical basis of the suprascapular nerve entrapment and clinical relevance of the supraspinatus fascia. *Surg Rad Anat* 2010; 32: 277-284.
5. G Soni, V.S. Malik, L. Shukla, S. Chhabra, N. Gaur, 2012. Morphometric Analysis of the Suprascapular Notch. *The Internet Journal of Biological Anthropology*. 2012 Volume 5, Issue 1.
6. Hrdicka A, 1942. The scapul: visual observations. *Am J PhysAntropol*, 29: 73-94.
7. Iqbal, K, Iqbal, R. and Khan, SG. Anatomical variations in shape of suprascapular notch of scapula: J. *Morphol. Sci* 2010; vol. 27, no. 1, p. 1-2.
8. Lajja K. Sutaria, Tushar V. Nayak, Sejal V. Patel, H. R. Jadav, C.A., 2013. Pensi, Morphology and morphometric analysis of suprascapular notch; *IJBAR* (2013) 04 (01).
9. Muralidhar Reddy Sangam, Sattiraju Sri Sarada Devi, Karumanchi Krupadanam, Kolla Anasuya. A Study on the Morphology of the Suprascapular Notch and Its Distance from the Glenoid Cavity; *Journal of Clinical and Diagnostic Research* 2013; February, Vol-7(2): 189-192.
10. Natsis, K., Totlis, T., Sikaras, P., Appell, H. And Skandalakis, P., 2007. Proposal for Classification of the Suprascapular Notch: a Study on 423 Dried Scapulas. *Clinical Anatomy*, 2007, vol. 20, p. 135-139.
11. Odita JC, Ugbodaga CI, Omene JA, Okolo AA. *Pediatric Radiol* 1983; 13: 276-278.
12. Ofusori, DA, Udera., Okwuonu, CU. And Adesanya, OA, 2008. Complete absence of the suprascapular notch in a Nigerian scapula: A possible cause of suprascapular nerve entrapment. *International Journal of Shoulder Surgery*, 2008, vol. 2, p. 85-6.
13. Olivier G. *Pratique anthropologique. Le Scapulum*. Vigot Freres 1960; Paris.
14. Polguy M, Podgorski M, Jedrzejewski K, Topol M, 2012. The double suprascapular foramen: Unique anatomical variation and the new hypothesis of its formation. *Skeletal Radiol* 2012 Jun 22.
15. Rengachary SS, Burr D, Lucas S, Hassanein KM, Mohn MP, Matzke H., 1979. Suprascapular entrapment neuropathy: a clinical, anatomical and comparative study. Part 1. *Neurosurgery*. 1979; 5: 441-46.
16. Rengachary SS, Burr D, Lucas S, Hassanein KM, Mohn MP, Matzke H., 1979. Suprascapular entrapment neuropathy: a clinical, anatomical and comparative study. Part 2. *Neurosurgery*. 1979; 5: 447-51.
17. Sinkeet SR, Awori KO, Odula PO, Ogeng JA, Mwachaka PM. The suprascapular notch: its morphology and distance from the glenoid cavity in a Kenyan population. *Folia Morphol*. 2010; 69 (4): 241-45.
18. Surekha D Jadhav, 2012. The Suprascapular Notch: Its Various Shapes In Indian Dry Scapulae: *RJPBCS Volume 3 Issue 4 Page No. 1086*.
19. Ticker J B, Djurasovic N, Strauch RJ, April EW, Pollock RG, Flatow EL, Bigliani LU, 1998. The incidence of ganglion cysts and other variations in anatomy along the course of the suprascapular nerve. *J Should Elb Surg* 7: 472-478.
20. Wang H, Chen C, Wu L, Pan C, Zhang W, Li Y, 2011. Variable Morphology of the Suprascapular Notch: An Investigation and Quantitative Measurements in Chinese Population. *Clinical Anatomy* 24: 47-55.
21. Yücesoy C, Akkaya T, Özel O, Cömert A, Tüccar E, Bedirli N, Ünlü E, Hekimoflu B, Gümüşoğlu H, 2009. Ultrasonographic evaluation and morphometric measurements of the suprascapular notch. *Surg Rad Anat*, 31: 409-414.