

Morphological study of variation in Arterial supply of kidney in Gujarat

Sanjay Vikani^{1*}, Pankaj Maheria², Satish Patel³, Kuldeep Suthar⁴

^{1,4}Assistant Professor, ²Associate Professor, ³Tutor, Dept. of Anatomy, GMERS Medical College, Dharpur, Patan, Gujarat

***Corresponding Author:**

Email: doc.vikani@gmail.com

Abstract

Introduction: Each kidney is irrigated by single renal artery, which is direct lateral branch of abdominal aorta. It is very important to understand the arterial pattern of kidney because it has much morphological variation, and there is many intervention procedure and surgeries carried out in kidney.

Method: This study was done on 30 cadavers of different medical colleges of Gujarat. During routine abdominal region dissection of UG students, precisely dissect Kidneys and its arterial supply, note the pattern and variation if present in artery.

Result: Sixty specimens of 30 Cadavers were dissected carefully and 60 specimen of kidneys observed and we found Double Renal Artery in 2(3.3%) specimens, Accessory renal artery in 13 specimen out of this 7(11.6%) on right side, 4(6.6%) on left side, 2(3.3%)Bilateral. 5 (8.3%)specimens had renal artery lies anterior to renal vein at hilum.

Conclusion: Knowledge of this type of renal artery variation is useful in clinical practise to minimise the complication during surgery and radiological procedure.

Keywords: Kidney, Renal Artery, Accessory Renal Artery, Variations.

Introduction

The kidneys are a pair of essential retroperitoneal excretory organ. Each kidney is supplied by renal artery which is a branch of abdominal aorta. Right renal artery is longer than left renal artery, because aorta lies on left paravertebral gutter. About 1 liter of blood circulate through both kidneys per minute. The renal artery reaches hilum of kidney between renal vein in front and renal pelvis behind, and divide into anterior and posterior division.⁽¹⁾ Renal artery gives 5 segmental branches, 4 from its anterior division and one from its posterior division, that segmental arteries are apical, upper, middle, lower on anterior aspect and only one on posterior aspect.⁽²⁾

Renal vascular segmentation was originally recognized by John Hunter in 1774, but the first detailed account of primary pattern was produced in 1950 from cast and radiographs of injected kidney. This is most common pattern, there may be considerable variation that clinician frequently encounter during the partial nephrectomy. Brodel described a relatively avascular longitudinal zone (Bloodless line of Brodel) along the convex lateral border, which is most suitable site for surgical incision.⁽³⁾ Consecutive arterial pattern is Lobar artery, Interlobar artery, arcuate artery and interlobular artery.

If we see the developmental point of view, The kidneys are develop initially in pelvis, as the abdomen and pelvis grow, the kidney comes into abdomen and reach at its adult position by the 9th week. During the change in kidney position, they receive their blood supply from vessels that are close to them. Initially the renal arteries are branch of common iliac artery, later from distal end of the Aorta. Normally caudal branches of renal vessels undergo involution and disappear. The Position of kidney becomes fixed once they come in

contact with suprarenal gland. The kidneys receive their most cranial arterial branches from abdominal aorta, that become permanent Renal artery, The right renal artery is longer and often more superior.⁽⁴⁾ The Accessory Renal artery is the precocious origin of segmental artery which usually arise from aorta and supplies upper and lower pole of kidney. The artery for lower pole is usually passes behind the pelvis of Ureter, and may cause obstruction to urinary flow producing hydronephrosis.⁽⁵⁾

Material & Method

The Present study was carried out on 30 embalmed cadavers in different Medical colleges of Gujarat. The Cadavers were donated by relatives with consent and death certificate. None of them had any physical abnormality, pathological, traumatic lesion or surgical procedure on abdomen. We precisely dissect kidney with its arterial supply as per Cunningham's manual of practical anatomy Vol-2(Thorax & Abdomen). After clear adjacent tissue we note down arterial pattern, normal or any variation and take a photograph for record.

Result

Sixty specimens of 30 Cadavers were dissected carefully and 60 specimen of kidneys observed and we found Double Renal Artery in 2(3.3%) specimens, Accessory renal artery in 13 specimen out of this 7(11.6%) on right side, 4(6.6%) on left side, 2(3.3%) Bilateral. 5(8.3%) specimens had renal artery lies anterior to renal vein at hilum.

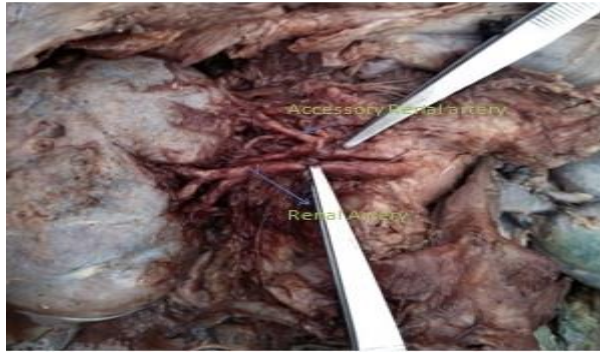


Fig. 1

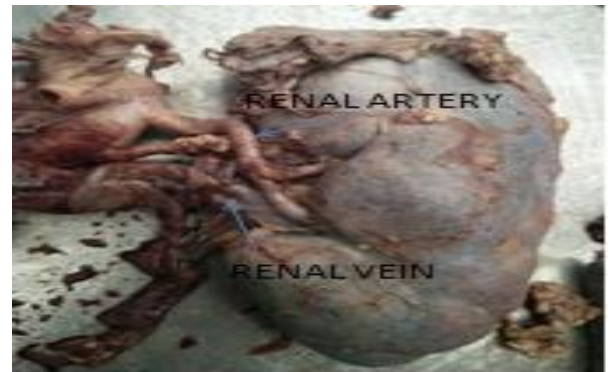

Fig. 3

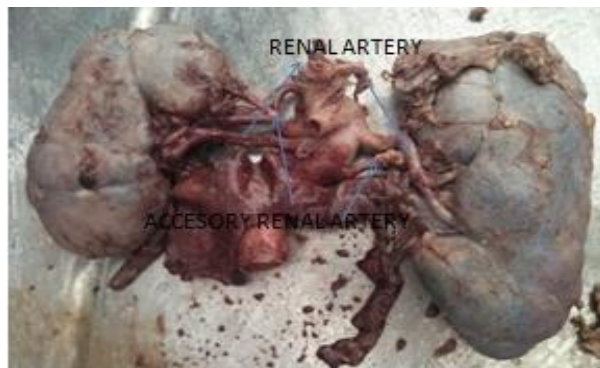

Fig. 2

Table 1

Variation	Right side	Left side
Double renal artery	2(3.3%)	0
Accessory renal artery	7(11.6%)	4(6.6%)
Renal artery anterior to renal vein	2(3.3%)	3(5%)

Discussion

Table 2

Name of Author	No. of Specimen	Variations		
		Double Renal artery	Accessory renal artery	Artery lies Anterior to vein
Present study	60	3.3%	25%	8.3%
Dhar & Lal ⁽⁸⁾	80	-	20%	-
Bordie P et al ⁽¹⁰⁾	54	10%	-	-
Gujar et al ⁽¹²⁾	30	10%	19.9%	15%
Sharmila aristotal et al ⁽¹³⁾	30	13.3%	13.3%	-

There is much Variation in branching pattern & distribution of vessels, about 30% variation in renal arteries. This variation can be dividing in two group early division & extra renal artery. If renal artery branched into segmental artery prior to enter into hilum is called early division. Extra renal artery of two types: Hilar (Accessory) & polar (Aberrant). Hilar artery arises from aorta runs with main renal artery up to hilum, while polar artery directly reach to pole of kidney without reach to hilum. So knowledge of this type of variation of renal artery either accessory or aberrant is very useful during various surgery and various radiological and other interventions.

The pre hilar branching pattern were observed, it may ladder, double, triple, and it represent kidney have segmental distribution and because of this type of variation there may be chance of haemorrhage during kidney transplant, post operative bleeding or segmental ischemia.⁽⁶⁾ Arterial supply of kidney is one of the example of end artery, because there is absence of interarterial anastomosis, that's why it is very much important to gain knowledge about arterial pattern of renal artery. As per Lee Mc Gregor's synopsis of surgical anatomy, in 15-20% of cases on right and left side respectively presence of more than one renal artery.⁽⁷⁾

And study conducted by Dhar and Lal, accessory renal artery present bilaterally in 5% cases and unilaterally in 15% cases.⁽⁸⁾ In our study we found Accessory Renal Artery in 25% specimen out of this 11.66% on right side, 6.66% on left side, 3.33% bilateral. Aberrant or Accessory Renal artery have been case of interest for many years by clinicians, because of they play an important role in hydronephrosis. But it is evident that there is no any specific criteria for aberrant vessels, the term aberrant has been applied with additional renal artery whether they derived from aorta or renal artery.⁽⁹⁾ One of the study by Bordei P et al., had found in 5 cases artery directly reach to superior pole as superior polar artery, 16 were reach to inferior pole as inferior polar artery and 24 kidney had hilar artery out of 54 cases studied.⁽¹⁰⁾ The bilateral double renal arteries has been found 4-10%.⁽¹¹⁾ Some author found double renal artery more on right side, while some says more on left side but there is no any significance of that present on any side. In our study we found in 3.33% cases had additional double renal artery both on right side.

In other study done by Gujar et al they found Accessory Renal artery 6.6% on right side, 13.3% on left side, renal artery anterior to renal vein in 15% cases, while in our study we found 8.3% specimen had anterior renal artery.⁽¹²⁾ In other study by Sharmila Aristotle et al., they remarked Normal arterial Pattern of kidney in 86.6% cases, Accessory renal artery in 13.3% all arise from abdominal aorta. Pre-segmental branches from Accessory renal artery in 6.6% specimen.⁽¹³⁾

Conclusion

The variation in artery is not taken for granted like other variation during the abdominal surgery. Awareness of different arterial variation of blood supply to kidney is most important for nephrologists, urologist during

various nephron preserving surgeries or renal transplant also for manage the renal vascular hypertension. It also useful for radiologist who can give report before renal surgery by giving idea to surgeon about variation of renal artery which can be seen by angiography.

Reference

1. Datta AK. Essentials of Human Anatomy. 9th Ed. Calcutta: Current Books International; 2014,289-302.
2. B D Chaurasia, Human Anatomy. 6th ed.: CBS Publisher & Distributor; New Delhi; 2013,317.
3. Williams PL, Bannister LH, Berry MM, Collins P, Dyson M, Dusse KJE et al. Gray's Anatomy. 40th ed. London: Churchill, Livingstone; 2008,1231.
4. Keith L, Persaud TVN. The developing human, clinically oriented embryology. 8th ed., Elsevier; 2008,294-250.
5. Datta AK. Essentials of Human Embryology. 9th Ed. Calcutta: Current Books International; 2014,289-302.
6. Virendra Budhiraja, Rakhi Rastogi, Asthana AK. Renal artery variations: embryological basis and surgical correlation. Romanian Journal of Morphology and Embryology. 2010;51(3):533-36.
7. McGregor A. I.: A Synopsis of Surgical Anatomy, 7th ed., p. 381,1944.
8. Dhar P, Lal K. Main and accessory renal arteries--a morphological study. Ital J Anat Embryol. 2005;110:101-10.
9. Graves FT. The Aberrant Renal artery. J. Anat. 1956;90:553-558.
10. Bordei P, Saote E, Iliescu D. Double renal arteries originating from the aorta. Surg. Radiol. Anat. 2004;26(6):474-79.
11. Ozkan U, Oguzkurt L, Tercan T, Osman K, Koc Z, Koca N (2006) Renal artery origins and variations: angiographic evaluation of 855 consecutive patients. Diagn Interv Radiol, 12:183-186.
12. Jigna K. Parmar, Subhash Gujar et al., A cadaveric Study of variations in Renal Artery; IJBAR,2012;03:11;815-817.
13. Sharmila A, Sundara Pandian, Christilda F. Anatomical study of variations in the blood supply of kidneys. J Clin Diagn Res. 20013;7(8):1555-7.