

Cadaveric study on the variant pattern of superficial palmar arch and its clinical relevance

Varalakshmi KL^{1,*}, Suresh Bidar Kotimath², Ajay Udyavar³

¹Assistant Professor, MVJ Medical College & Research Hospital, Karnataka, ²Associate Professor, Jazan University, Gizan, Saudi Arabia, ³Professor, Dept. of Anatomy, AJ Institute of Medical Sciences, Mangaluru, Karnataka

***Corresponding Author:**

Email: drvara.hitesh@gmail.com

Abstract

Introduction: Superficial palmar arch is one of the important arterial arcade supplying the human hand. Vascular supply to human hand is one of the challenging areas showing many morphological variations. Presently the modern medical technology has shown vast improvement, it is better to have a detailed knowledge of arterial supply to the hand because significant number of surgical procedures such as canulation of radial artery, radial artery auto grafting in coronary bypass surgeries are carried out. Knowledge of vascular pattern is more important in reconstructive hand surgery.

Materials and Method: 40 human hands procured from 20 embalmed cadavers of A.J. Institute of Medical science, Mangalore used for the study. Dissection of arch was carried out and variations of superficial palmar arch with regards to formative arteries and branching pattern are studied in detail.

Results: Out of 40 hands studied 31 (77.5%) hands showed complete and 9(22.5%) hands showed incomplete superficial palmar arches. In majority of hands (26) complete arch were formed by the direct continuity between ulnar artery and superficial palmar branch of radial artery. In 2 hands arch was formed by ulnar artery and median artery. Out of 9 incomplete arches, 7 hands showed arch formed mainly by ulnar artery and in 2 hands ulnar artery and superficial palmar branch of radial artery without anastomosis.

Conclusion: The results of this study will be helpful for surgeons, intervention radiologist and orthopaedicians for the successful outcome of any hand surgeries.

Keywords: Arterial arcade, Variations, Reconstructive hand surgeries, Coronary bypass surgeries, Canulation for radial artery, Superficial palmar arch

Received: 6th April, 2017

Accepted: 1st June, 2017

Introduction

The human hand requires major blood supply because of the multiple positions and tasks in which it would be involved and these multiple positions will result in distribution of pressure in various direction. This prime purpose is mainly solved by the presence of highly branched and dense network of arteries in the palm mainly contributed by two palmar arches namely superficial and deep palmar arch.⁽¹⁾ Superficial palmar arch can be considered as the main continuation of ulnar artery which curves laterally deep to the palmar aponeurosis and joins with superficial palmar branch of radial artery on the lateral side. From its convexity it gives three common palmar digital branches which anastomose with the palmar metacarpal arteries arising from deep palmar arch. Each common palmar digital arteries runs distally in the web between medial four fingers and divides into two proper palmar digital arteries and supplies them. It also gives a single proper palmar digital artery which runs along the medial side of little finger and supplies it.⁽²⁾

In one third of cases the arch may also formed by the anastomosis between ulnar artery and princeps pollicis artery or arteria radialis indicis or median artery. In third of cases it may be solely formed by ulnar artery.⁽³⁾

According to standards text books and studies by many authors the classical type of complete superficial palmar arch was formed by the union between ulnar artery and superficial palmar branch of radial artery which guarantee the presence of collateral supply in the hand. An incomplete arch shows the absence of anastomosis between the contributing arteries.⁽⁴⁾

Information on the morphological variations of superficial palmar arch is highly useful in case of microsurgical reconstructive surgeries of hand. It is also important in patients with athermatous obstruction of coronary artery where radial artery can be used as a graft materials for revascularisation of infarcted myocardium. So in such patients pre-operative screening of radial artery should be mandatory to prevent complications. Radial artery is also used in case arterial intervention procedures such as radial artery forearm flaps and canulation of radial artery. Immense progress in the hand surgeries, increased the need for knowing the in depth details of superficial palmar arch and its variations.⁽⁵⁾

Before performing any surgical procedures on the hand such as vascular graft application or arterial repair, the surgeons should be aware of normal existence and healthy functioning of these arterial arches to prevent the complications such as acute ischaemia with pain at rest or gangrene.^(6,7)

Thus knowledge of superficial palmar arch is important for anatomist for academical purpose as well as for surgeons, radiologists and orthopaedicians in their clinical practice. Considering the role of superficial palmar arch and its variations in the successful outcome of any hand surgeries the presents study is an attempt to learn the course, relation, variations of superficial palmar arches in human cadavers.

Materials and Method

A total of 40 upper limbs from 20 embalmed cadavers were obtained from the department of anatomy, A.J. Institute of Medical Sciences, Mangalore, Karnataka were used for the study. Deformed, traumatised upper limbs were excluded from the study. Dissection was carried out according to the practical manual of anatomy by Cunningham's volume 1. A transverse incision was given at wrist. From the midpoint of this incision another incision was taken to the tip of middle finger in the median plane. Transverse incision was given at the roots of fingers. The flaps were reflected taking care not to injure the cutaneous vessels and nerves. Palmar aponeurosis was exposed and divided proximally and reflected distally cutting the septae which pass backwards from its edges. This exposed the superficial palmar arch which was later cleaned to study the formation of arches, branching pattern and variations.

Results

The total 40 hands are studied. The statistical analysis is carried out and results are tabulated. Depending on the presence or absence of anastomosis between the contributing arteries in the present study superficial palmar arch was classified into complete and incomplete types. Out of 40 hands 31 hands (77.5%) are complete and 9 (22.5%) hands are incomplete. (Pie chart)

Complete Arches: Complete arches are divided into 3 types depending upon the arteries involved in the anastomosis.

Type 1 Complete arch: In the present study, the arch completed by ulnar artery and superficial palmar branch of radial artery is the most common type, seen in 26 hands(65%). In this pattern the radial artery before passing dorsally to the anatomical snuff box, gives superficial palmar branch which passes to the palm either superficial or deep to the thenar muscles and ends by anastomosing with terminal end of ulnar artery.(Fig. 1)

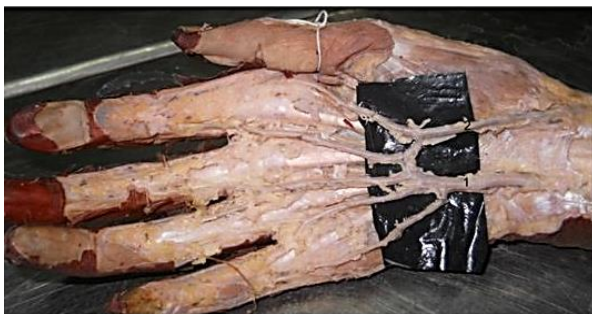

Fig. 1: Type 1 Complete Arch: Ulnar artery (1) & superficial palmar branch of radial artery (Right)

Type 2 complete arch: Arch completed by ulnar artery and princeps pollicis branch of radial artery. Out of 31 complete arches 3(7.5%) hands presents this pattern. Radial artery in the present case passes dorsally at wrist and traverses the anatomical snuff box. It passes between the two heads of first dorsal interosseous muscle and enters into the palm. In the palm it completes the arch by anastomosing with terminal end of ulnar artery and supplies the thumb as arteria princeps pollicis. (Fig. 2)

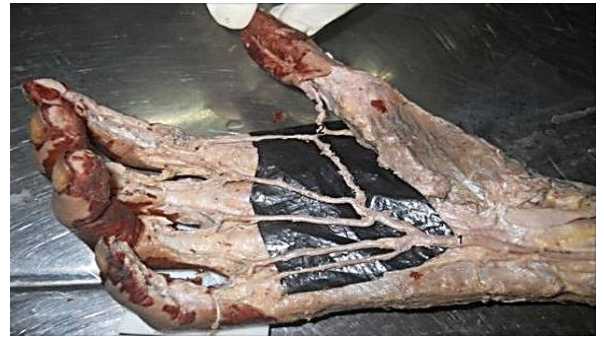

Fig. 2: Type 2 complete arch: Ulnar artery (1) and princeps pollicis artery (2) Right

Type 3 complete arch: Arch completed by ulnar artery and median artery. It is a rare pattern seen in 2(5%) hands. In both the hands the median artery takes origin from ulnar artery below the elbow and enters into the palm to form the arch with ulnar artery. Radial artery passes dorsally to anatomical snuff box without involved in arch formation. (Fig. 3)

Incomplete arches are seen in 9 hands and 2 different patterns were observed.

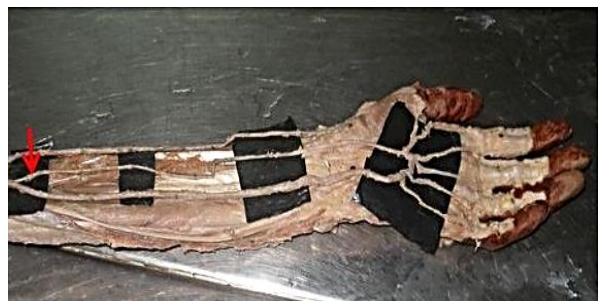

Fig. 3: Type 3 complete arch: Ulnar artery & median artery. (Arrow-Median artery arising from ulnar artery) (Left)

Type 1 Incomplete arch: Arch formed by ulnar artery alone. Out of 9 incomplete arches 7(17.5%) hands showed this pattern. The ulnar artery gives one proper palmar digital branch to medial side of the little finger and 3 common palmar digital branches to adjacent sides of little, ring, middle and index finger. The main trunk of ulnar artery runs in the web between thumb and index finger and supplies it. (Fig. 4)

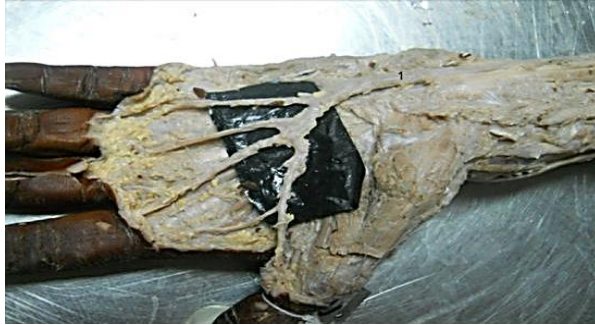

Fig. 4: Type 1 incomplete arch: Ulnar artery (1) alone. (Left)

Type 2 incomplete arch: In this type, the palm is supplied by ulnar artery and superficial palmar branch of radial artery separately without any anastomosis between them. It is seen in 2(5%) hands. Medial three fingers are supplied by ulnar artery and lateral two fingers are supplied by superficial palmar branch of radial artery. (Fig. 5)

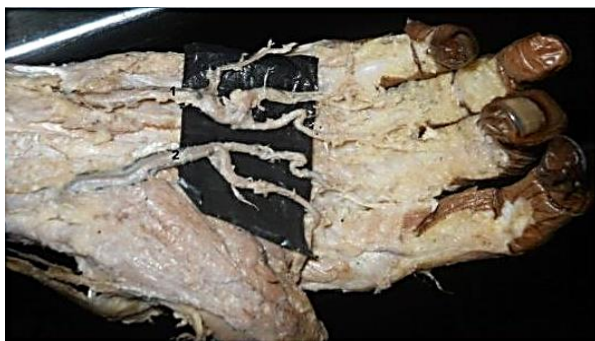

Fig. 5: Type 2 incomplete arch: Ulnar artery (1) & superficial palmar branch of radial artery (2) without anastomosis (Right)

Discussion

Formation and branching pattern superficial palmar arch is one of the interesting area in a human body showing high level of variation.⁽⁸⁾ These variations were the center of attraction for many anatomists and many studies have been conducted on them from centuries.⁽⁹⁾

The variations were studied as early as 1753, by Albert Von Haller, a Swiss anatomist and poet. Notable variations were explained by Tiedmann (1831) which were explained later on ontogenic basis by Meyer and Singer(1933). Later on several studies of arches were made by different authors and each author classified it into different pattern depending on the variation.

Jaschtschinski divided the superficial palmar arches into complete and incomplete types. This was later modified by Adachi by classifying the arches into 3 types.

Type 1: ulnar type with minimal or absence of contribution by radial artery seen in 59% of hands.

Type 2: Classical radioulnar type seen in 32% of hands.

Type 3: Medianoulnar type seen in 9% of hands.

Heuber and his colleague's classification of arches were of two type. In the first type an additional branches from the forearm participated in the formation of arch and it replaced the classical type. In the second type in which there is no true arch, the arteries which should participate in its formation and in some cases the additional ones also failing to anastomose and giving rise independently to a certain number of branches in a somewhat fan like manner.⁽¹⁰⁾

Loukas dissected 200 hands derived from formalin fixed cadavers. 90% of hands showed complete arches and 10% incomplete arches. Five different patterns of arches were found and they proposed a new classification of these arches as S1 to S5. Among the five types, the classical type was most common with 40% occurrence(S1). Arch completed by ulnar artery (S2) solely was seen in 35% of cases followed by media no ulnar type in 15% (S3). S4 type was unique pattern which showed the anastomosis between radial, ulnar and median artery seen in 6.1% of hands. In 3.5% of cases also had arch completed by branch from deep palmar artery (S5).⁽¹¹⁾

In the present study arches are broadly classified into complete and incomplete types which in turn divided into subtypes depending on the arteries involved in the formation of arches. Hence in the present study arches formed by the anastomosis between the ulnar artery and superficial palmar branch of radial artery, princeps pollicis artery and median artery are the complete arches and superficial palmar arch formed by ulnar artery alone and ulnar artery and superficial palmar branch of radial artery without anastomosis is considered as incomplete type.

In the present study out of 40 hands 31(77.5%) hands were complete and 9(22.5%) hands were incomplete. (Table 1) The complete arch findings of our study correlates with the similar observation of Coleman and Anson (78.5%/650), Patnaik (78%/50) and Suleyman (75%/20) whereas, Gellman observed 84.4% in 45 hands And Loukas observed 90% in 120 hands. Similarly incomplete arch observations correlate with Coleman and Anson (21.5%) and Suleyman Tagil (25%) and Patnaik (22%) whereas Gellman observed 15.6% of incomplete arches in 45 hands, Ottone 42% in 86 hands, Loukas 10% in 120 hands, Moraes 40% in 30 hands.

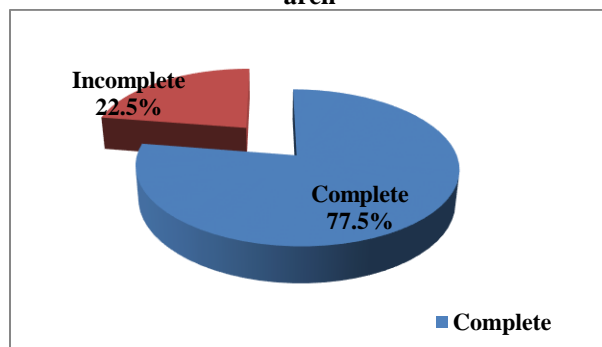
Table 1: Type of superficial palmar arch: In comparison with other studies

Types	Complete arch (%)	Incomplete arch (%)
Coleman and Anson(650 hands) ⁽¹⁰⁾	78.5	21.5
Patnaik(50 hands) ⁽¹¹⁾	78	22
Gellman(45 hands) ⁽¹²⁾	84.4	15.6
Ottone(86 hands) ⁽¹³⁾	58	42
Loukas(120 hands) ⁽⁹⁾	90	10
Suleyman(20hands) ⁽¹⁴⁾	75	25
Moraes(30hands) ⁽¹⁵⁾	60	40
Present study	77.5	22.5

Table 2: Different subtypes of superficial palmar arch: in comparison with other studies

	Ulnar artery + Superficial palmar branch of radial artery (%)	Ulnar artery + Median artery (%)	Ulnar artery + Deep branch of radial artery (%)	Ulnar artery alone(%)	Ulnar artery + Superficial palmar branch of radial artery (%)
Coleman and Anson (650 hands) ⁽¹⁰⁾	34.5	3.8	2	13.4	3.2
Pataink (50 hands) ⁽⁸⁾	76	0	-	-	12.0
Gellman (45) ⁽¹¹⁾	35.5	13.3	-	11.2	4.4
Ottone (86 hands) ⁽¹²⁾	22.1	-	8	23.2	8.3
Loukas (120 hands) ⁽¹⁰⁾	40	15	-	10	-
Suleyman (20hands) ⁽¹³⁾	40	38	1.2	20	-
Moraes (30) ⁽¹⁴⁾	36.67	10	13.33	23	13.33
Present Study	65	5	7.5	17.5	5

The classical type of arch formed by ulnar artery and superficial palmar branch of radial artery is the predominant type seen in the present study correlating with the findings of Patnaik(76%). Since there is a good anastomosis between the contributing vessels this type of arches confirms the collateral supply in the hand so that in the absence of any vascular disease, radial artery can be safely used for harvesting in coronary bypass surgeries as there is a collateral supply by ulnar artery which prevent the ischemic changes in the hand. But it is always mandatory to screen the patient preoperatively to assure the presence of healthy collateral supply in the hand.⁽¹⁷⁾

Pie chart showing the types of superficial palmar arch

The second type of complete arch is seen in 7.5% of cases correlating with study by Ottone et al showing 8%. In case of any occlusion of radial artery or surgical manipulation of princeps pollicis artery will lead to pain, paraesthesia and gangrene of thumb and index finger.⁽¹⁸⁾

Type 3 complete arch is seen in 5% cases similar to Coleman and Anson (3.8%) and Jaschtschinski (4%). During embryonic life distal part of axis artery of upper

limb bud persists as anterior interosseous artery which give rise to median artery.⁽¹⁹⁾ Median artery usually undergoes regression in the 2nd month of intra uterine life. Its persists in the human adult in two different patterns: Palmar type reaching the palm and Antebrachial type which ends in the forearm itself.⁽¹⁸⁾ The palmar type of median artery passes through the carpal tunnel along with median nerve and it may compresses the median nerve leading to carpal tunnels syndrome. While considering radial artery as a graft for coronary artery bypass the least number of complications may be expected in these types of arches.⁽²⁰⁾

Arch completed entirely by ulnar artery is seen in 7 hands (17.5%). It correlates with findings of Coleman and Anson (13.4%) and Suleyman (20%). The greatest risk associated with radial artery as a graft for coronary artery bypass surgery is ischemia of the soft tissues of the hand. But in patients where ulnar artery is the main blood supply to the first web space the least number of complications may be expected. In these cases potential hazards could exist to the digit including index and thumb in the event of injury to ulnar artery. In ulnar skin flaps, damage to ulnar artery may lead to inefficient movements of fingers.⁽²¹⁾

In the present study Type 2 incomplete arches are seen 5% of hands correlating with the findings of Coleman and Anson (3.2%), Gellman (4.4%). These types of arches are associated high risk of digital ischemic changes following a trauma to radial artery trauma or interventions.⁽⁴⁾

Conclusion

The present study had provided details of variant patterns of superficial palmar arch along with its clinical importance which may be useful for operating surgeons,

radiologists and orthopaedicians in their day to day practice.

References

1. Sudha Seshayyan. Inderbir Singh's Text book of anatomy Upper extremity and lower extremity. 6th edition, Jaypee publication; 2016. p 203-204.
2. Datta AK. Essentials of human anatomy superior and inferior extremities. 4th Edn., Kolkata: Current Books International; 2004. p 93-94.
3. Standring S. Gray's anatomy. The anatomical basis of clinical practice. 40th edn., Edinburgh: Elsevier Churchill Livingstone; 2005.p 894.
4. Mookambika RV, Nair V, Nair R, Somayaji SN, Pamidi N, Vollala VR. Incomplete superficial palmar arch. International Journal of Anatomical Variation 2010;3:85-88.
5. Lakshmi Prabha R, Murthy NH, Komala B, Kumaran S. Bilateral incomplete superficial palmar arch. International Journal of Anatomical Variation 2009;2:86-88.
6. Vollala VR, Nagabooshana S, Rao M, Potu BK, Pamidi N, Bolla SR. Unorthodox superficial palmar arch seen in South Indian cadaver: A case report. Cases J 2009;2:62-63.
7. Mathew LS, Ebby S. Variation of superficial palmar arch: A Case report. WEB MED central anatomy 2012;3(5).
8. Bilge O, Pinar Y, Ozer MA, Govsa F.A morphometric study on the superficial palmar arch. Surgical Radiological Anatomy 2006;28:343-50.
9. Kia ML, Justin S, Yur-Den K, Ronit W, Rubin JP, Lee WP. Anatomical landmarks to the Superficial and deep palmar arches. Plastic and Reconstructive Surgery 2008;121(1):181-85.
10. Patnik VV, Gopichand, Kalsey G, Singla RK. Palmar arterial arches-A morphological study. Journal of Anatomical Society Of India 2001;51(2):187-93.
11. Loukas M, Holdman D, Holdman S. Anatomical variations of the superficial palmar arches, Folia Morphol 2005;64:78-83.10.
12. Coleman SS, Anson BJ. Arterial pattern in the hand based on the study of 650 specimens. Surg Gynaec And Obstet 1961;108:245-61.
13. Coleman SS, Anson BJ. Arterial pattern in the hand based on the study of 650 specimens. Surg Gynaec And Obstet 1961;108:245-61.
14. Gellman H, Botter MJ, Shankwiler J, Gelberman RH. Arterial patterns of deep and superficial palmar arches. Clin Orthop & Related Research 2001;383:41-46.
15. Ottone NE, Prum N, Dominguez M, Medan C, Shinzato, Finkelstein, et al. Analysis and clinical importance of superficial arterial palmar irrigation and its variation over 86 cases. International Journal of Morphology 2010;28(1):157-64.
16. Murat ST, Emine AC, Cevatogun T, Buyukmumcu MS. Variation And Clinical importance Of the Superficial Palmar Arch. S.D.U. Tip FAK. derg 2007;14(2):11-16.
17. Moraes SRA, Arauji TN, Silva AR, Paula AR, Salgado JL. Morphologic variants of the superficial palmar arc. Acta Cirurgica Brasileria 2003;18(3):164-68.
18. Ruengsakulrack P, Eizenberg N, Fahrer C, Fahrer M. Surgical implications of variations in hand collateral circulation: Anatomy revisited. J Thorac and Cardiovasc surg 2001;122(4):685.
19. Vollala VR, Nagabooshana S, Bhat SN, Rodrigues V, Rao M. Rare anatomical variant: an arterial circle in palm and at the base of thumb. Romanian Journal Of Morphology And Embryology 2008;49(4):585-87.
20. Data AK. Essential of human embryology. 5th edn., Kolkata : Current Books International;2007.p 195-96.
21. Rodrigues MN, Sanudo JR, Vazquez T. Median artery revisited. J O Anat. 1999;195:57-63.
22. Suman U, Jayanthi KS.A study of complete superficial palmar arch formed entirely by ulnar artery. J. Anat. Soc. India 2011;60(2):199-01.