

Sexual dimorphism of Lip Prints in South Indian Population

Pushpa NB^{1,*}, Roshini Bajpe²

¹Assistant Professor, JSS Medical College, JSS University, Mysore, ²Professor, Dept. of Anatomy, KIMS, Bangalore

***Corresponding Author:**

Email: nb.pushpa@gmail.com

Abstract

Aim: To study the sexual dimorphism of lip print patterns in south Indian population.

Materials and Method: Dark coloured lip colour, lens to magnify and white paper to take the lip prints. The study group consisted of 100 south Indian individuals from Karnataka, Kerala, Andhra Pradesh, and Tamilnadu aged between 17-60years where Males = females = 50. Individuals with any lip pathology were excluded from the study. On well cleaned lips of individuals, a dark coloured lip colour was applied and lip prints were taken on the pre labelled white paper. Based on Suzuki's classification, Lip prints were categorised into 5 types.

Results: In the present study most common lip print pattern found among the individuals was Type II (45%) and type III was least commonly found. In the males Type II and in the females Type I lip print patterns were widely seen.

Conclusion: Lip prints were unique, differed from person to person. This study is an attempt to throw light on the most prevalent type lip print among south Indian people and see for its sexual dimorphism.

Keywords: Lip print, Common, Predominant, Population

Received: 31st May, 2017

Accepted: 24th June, 2017

Introduction

Lips are fleshy folds lined externally by skin and internally by mucous membrane, which are continuous at the vermilion border. In contrast to this, the inner mucosal surface is covered by thick non keratinized stratified squamous epithelium. The epithelium on its superficial aspect has dead squames and deeper surface is highly folded which interdigitates with dermal papillae. These surfaces are devoid of hairs; their dermis is devoid of sebaceous, sweat and mucous glands. The size and curvature of the external surface varies with individual, gender and ethnicity.⁽¹⁾

The mucous membrane of lips shows many ridges and furrows which form a typical pattern called lip prints and its study is called as Cheiloscopy.⁽²⁾ Tsuchihashi Y called these grooves as sulci labiorum and the pattern formed by them as figura line arum laborium, which means lip prints in Japanese.⁽³⁾ Lip prints differ from person to person. Cheiloscopic techniques have an equal value with respect to other

types of forensic evidences for personal identification.⁽⁴⁾

Materials and Method

Sample size: Study was carried out at the department of Anatomy, KIMS Bengaluru. The study group consisted of 50 males and 50 females (n= 100) of south Indian origin, of age 17-60 years. Subjects with any lip pathology were not considered for the study.

Materials: Brown / pink Lip color, White paper to take lip prints, lens to magnify, tissue paper to clean the lips.

Method: White papers were given to the individuals of the study and were asked to fill their name, age, sex address and occupation. Lips of individuals were cleaned with tissue paper, then lipcolor was uniformly applied. Individuals were instructed to give their lip prints by pressing their lips against the paper as shown in the (Fig. 1). To include the vermilion border paper was folded and pressed between the lips carefully, also to prevent any overlapping of the lip prints.⁽⁵⁾

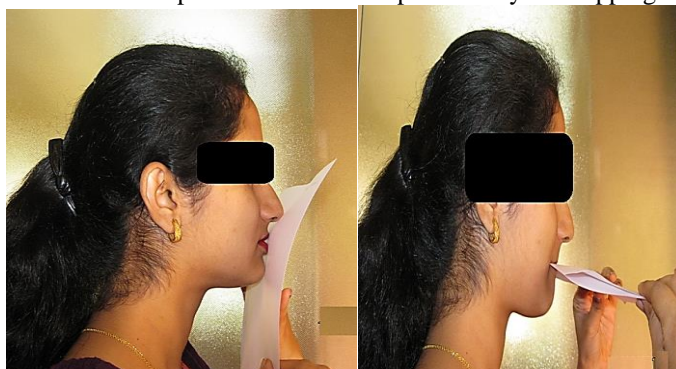

Fig. 1: Showing procedure of taking lip prints

Observations and Results

Lip prints got by the above method was analysed using hand lens. Lip print of each individual was divided into four quadrants – right upper (RU), left upper (LU), right lower (RL) & left lower (LL) as shown in Fig. 2. Lip print pattern in each quadrant was noted. Combination of patterns were seen in each lip print.

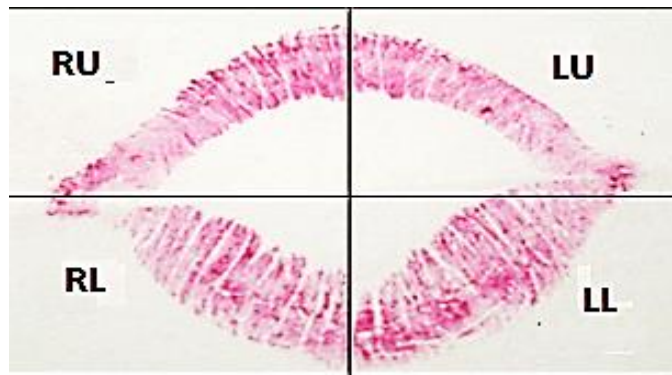


Fig. 2: Lip print pattern divided into four quadrants

Lip prints were categorised with reference to Suzuki’s classification⁽⁶⁾

Type I – Vertical line like , extending from end to end	
Type I’ – vertical line like, but short and extending only half of the lip.	
Type II – ramifying , Y or λ shaped	
Type III- X or Crisscross shaped	
Type IV- mesh like	

Following figures represent samples of Lip print patterns of the present study.

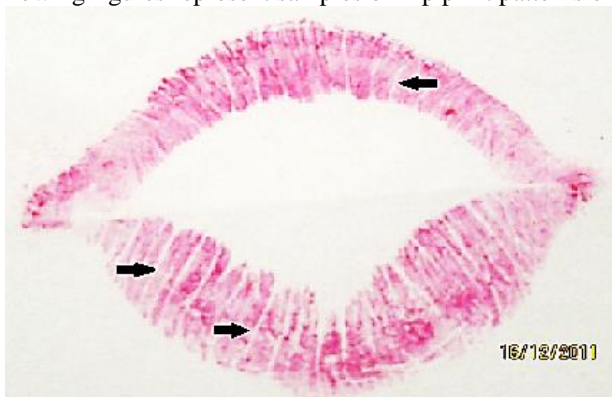

Fig. 3: Type I and type I’ pattern seen in female subject

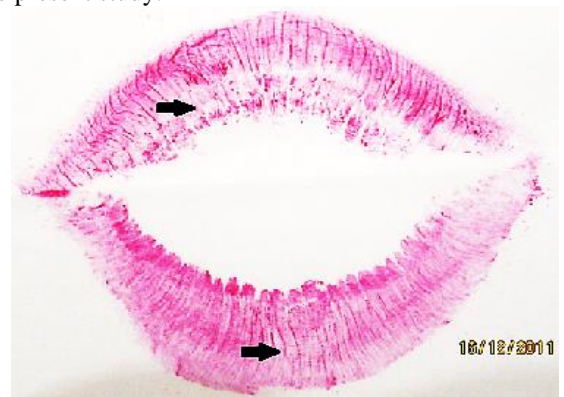


Fig. 4: Type II pattern seen in male subject

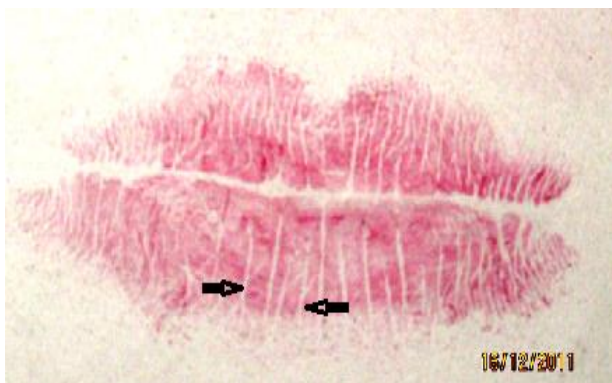


Fig. 5: Lip print of a female with type III pattern

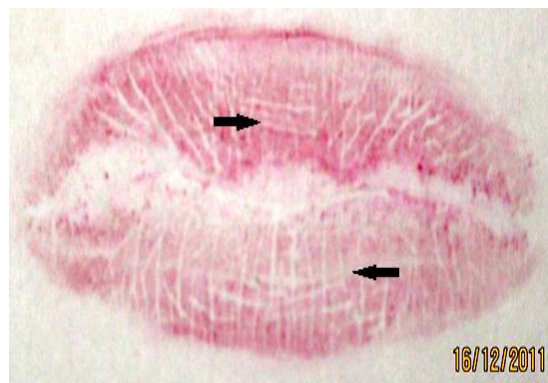

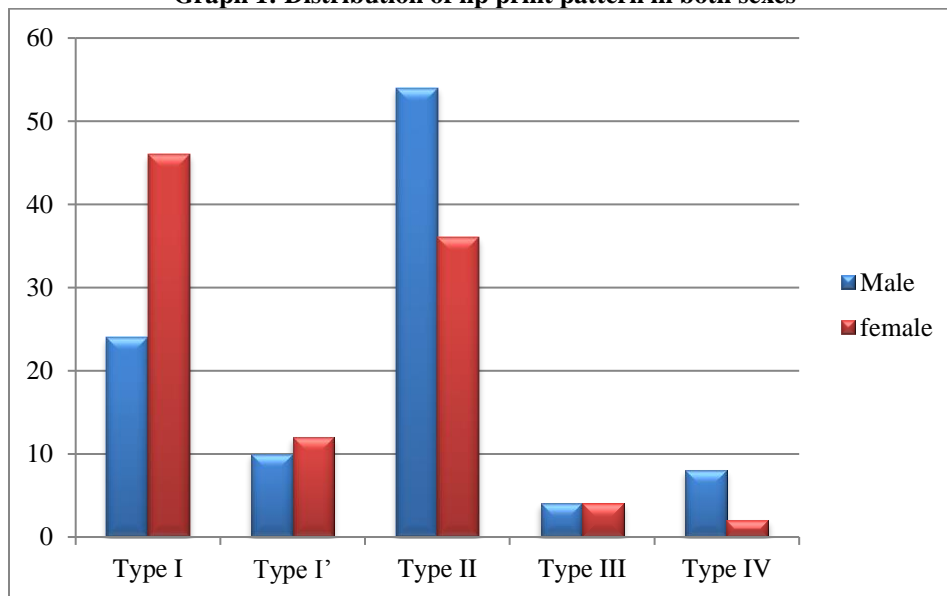
Fig. 6: Lip print of a female with type IV pattern

No two lip prints of the individuals were alike. Total of 400 quadrants were studied among 100 individuals. In each quadrant of the same lip print, combination of patterns were observed. In them the most prominently & clearly visualised pattern was taken into consideration. The results were tabulated (Table 1).

Lip print patterns	Male		Female		Total	
	200 quadrants	Percentage (%)	200 quadrants	Percentage (%)	400 quadrants	Percentage (%)
Type I	48	24	92	46	140	35
Type I'	20	10	24	12	44	11
Type II	108	54	72	36	180	45
Type III	8	4	8	4	16	4
Type IV	16	8	4	2	20	5

T 1 – Types of lip print patterns in the study group.

Graph 1: Distribution of lip print pattern in both sexes



As shown in the table, in the present study most widely seen pattern in all quadrants was type II (54%). Type III was seen only in 4% of study group. Among males – II, I, I', IV, III was the descending order of frequency of lip prints seen. Among females of present study, Type I was most prevalent i.e. 46% and Type IV was less prevalent only in 2% of that group. Pattern in the order of frequency among females – I, II, I', III, IV.

Discussion

Lip prints play an important role in Forensic Medicine for the identification of person. There are instances where the cases have been solved by using lip prints⁽⁷⁾ as they can be obtained up to 30 days from the scene of crime.⁽⁸⁾ Beyond doubt it is been proved by Aggarwal that lip prints are as good as finger prints in

personal identification, when traditional methods are not available.⁽⁹⁾

In a study conducted in Japanese population Suzuki and Tsuchihashi examined lip prints from 280 individuals among them 150 were males & 130 females, using photographic method. By that they came to conclusion that lip prints differs from person to person. In another study on 757 males & 607 female's total of 1364 Japanese, Tsuchihashi advocated that each quadrant of lip pattern contains combination of patterns.^(3,10)

10. Tsuchihashi Y, Suzuki K, Studies on lip print – I. Shikwa Gakuho 1968;68:60-61.
11. Sandhu SV, Bansal H, Monga P, Bhandari R. Study of lip print pattern in Punjabi population. Journal of Forensic Dental Sciences 2012;4(1):24-8.
12. Kapoor N, Badiye A. A study of distribution, sex differences and stability of lip print patterns in an Indian population. Saudi Journal of Biological sciences 2015;1-4.

Region	Most prevalent type of lip print		Least prevalent type of lip print	
	Male	Female	Male	Female
Uttarakhand ⁽³⁾	II	II	III	III
Uttar Pradesh ⁽⁹⁾	III	III	IV	IV
Punjab ⁽¹¹⁾	I	I	IV	IV
Marathi ⁽¹²⁾	I	III	I'	I'
Present study	II	I	III	III

T-2 lip print patterns studied in various regions of India

Table 2 summarises the patterns of lip prints obtained in different studies done on various parts of India. In the present study, among males Type II and among females Type I pattern of lip print was widely seen, least common being Type III pattern in both sexes.

Conclusion

Since no two lip prints are alike and their distribution varies in different region and sex; like finger prints, they can be used as efficient tool in personal identification.

References

1. Standing S, Borley NR, Collins P, Crossman AR, Gatzoulis MA, Healy JC, et al. Gray's Anatomy: The Anatomical Basis Of Clinical Practice. 40th edition, London: Elsevier Ltd; 2008. P 793,795,796.
2. Kasprzak J. Possibilities of cheiloscopy. Forensic Sci Int 1990;46:145-51.
3. Tsuchihashi Y. Studies on personal identification by means of lip prints. Forensic Sci 1974;3:233-48.
4. Reddy LV. Lip prints: An overview in forensic dentistry. J Adv Dent Res. 2011;11:16-20.
5. Bindal U, Jethani SL, Mehrotra N, Rohtagi R.K, Arora M, Sinha P. Lip Prints as a method of identification in Human being. Journal of Anatomical society of India 2009;58(2):152-155.
6. Suzuki K. Forensic odontology and criminal investigation. Acta Crim Japonica 1970;36:88-102.
7. Ball J. The current status of lip prints and their use for identification. J Forensic Odontostomatol.2002;20:43-6.
8. Segui AM Feucht MM, Castello PA, Pascual VF. Persistent lipsticks and their prints: New hidden evidence at the crime scene. Forensic Sci Int 2000;112:41-7.
9. Saraswathi TR, Gauri Mishra, Ranganathan K. Study of lip prints. Journal of Forensic Dental Sciences 2009;1:28-31.