

An anatomical study on various types of suprascapular notch, its relation with glenoid cavity and morphometry of scapula in south Indian population

Chaitra BR¹, Raviprasanna K H^{2*}, Anitha M R³

¹Assistant Professor, ²Associate Professor, ³Professor, Dept. of Anatomy, ^{1,3}Akash Institute of Medical Sciences and Research Center, Bengaluru Rural, Karnataka, ²Mamata Medical College, Khammam, Telangana, India

*Corresponding Author: Raviprasanna K H

Email: pravikh8124@gmail.com

Received: 30th March, 2019

Accepted: 23rd May, 2019

Abstract

Introduction: Superior border of scapula presents a suprascapular notch. Suprascapular nerve entrapment syndrome may be caused due to compression of the nerve at the notch. Previous studies have shown that there are various types of suprascapular notch and clinicians must be aware of these types and their prevalence.

Aim: This study was conducted with the following objectives, a: To know the morphometry and morphological variations of suprascapular notch; b: To measure the safe zone distance necessary to avoid iatrogenic injuries to nerve; c: To correlate the major scapular dimensions with that of suprascapular notch.

Materials and Methods: We collected 100 dried human scapulae from department of Anatomy and medical students of AIMS&RC, Devanahalli, Karnataka and Sri Narayana Institute of Medical Sciences, Ernakulam, Kerala. The Suprascapular notch was classified according to Rengachary's classification. Dimensions of all different class of suprascapular notches, that of scapulae and safe zone distance was measured using digital Vernier calipers.

Results: Majority of scapulae had type II SSN (33%) and least common variety found was type IV (4%). Least surface area in type V notch measured was 36.16mm². Mean safe zone distance between SSN and supraglenoid tubercle (S1) in all 100 scapulae is 30.31+/-3 mm. The mean distance between spinoglenoid notch and posterior rim of glenoid (S2) is 16.82+/-2.19 mm. Mean length of all 100 scapulae is 135.12+/-1 mm. Mean width of scapula is 101.69+/-6.8 mm. Mean length and width of glenoid fossa is 33.83+/- 3.25 mm and 24.2+/-2.34 mm respectively.

Conclusion: Ossified superior transverse scapular ligament can compress the nerve causing entrapment syndrome. Since suprascapular notch presents various shapes, this study is an attempt to add further data to the existing studies about suprascapular notch, its morphometry and safe zone distance to avoid injury to nerve during surgery.

Keywords: Neuropathy, Scapula, Shoulder joint, Suprascapular notch.

Introduction

Separated from the root of coracoid process at its lateral end, superior border of scapula presents a suprascapular notch. Superior transverse scapular ligament bridges the notch and its sometimes ossified. Suprascapular nerve is a large branch of upper trunk of brachial plexus. Nerve enters supraspinous fossa below the ligament through the notch and passes deep to supraspinatus and supplies it. Nerve then reaches infraspinous fossa by passing round the lateral end of scapular spine and supplies infraspinatus. Nerve also give articular rami to shoulder and acromioclavicular joint. Suprascapular nerve entrapment neuropathy may occur in the suprascapular notch often related to degenerate cyst originating from posterior glenoid labrum. Nerve may also get damaged by trauma to scapula causing weakness of supraspinatus, which is an abductor of shoulder and infraspinatus, an external rotator of shoulder.¹

Calcified superior transverse scapular ligament may compress the suprascapular nerve as it passes under the ligament, thus affecting the functions of supraspinatus and infraspinatus.² Suprascapular notch shows variations in its shape. Rengachary et al.³ classified suprascapular notch into six types. Suprascapular notch is an important landmark during arthroscopic procedures to prevent accidental injuries to suprascapular nerve.⁴ Study done by Gumina S et al.⁵

described two safe zone distances which are necessary to avoid iatrogenic injuries of suprascapular nerve during surgeries. One is the distance between supraglenoid tubercle and suprascapular notch and other is the distance between middle of posterior rim of glenoid cavity and base of scapular spine.⁵ So we did this study with the following objectives,

1. To know the occurrence of various types of suprascapular notch, its morphometry and correlate with other studies.
2. To measure the safe zone distance in scapulae and its correlation with different types of suprascapular notches.
3. To correlate the scapular dimensions with various types of SSN.

Materials and Methods

We collected 100 human dried scapulae from the department of Anatomy and medical students, Akash Institute of Medical Sciences and Research Center, Devanahalli, Karnataka and Sree Narayana Institute of Medical Sciences, Ernakulam, Kerala. While collecting the scapulae, age, sex and side were not taken into consideration and broken scapulae were excluded. Suprascapular notches

were carefully observed to classify them into six types based on description given by Rengachary et al.³

Description of various types of SSN is as follows,

Type I: Notch presents as slight indentation at the superior border of scapula (Fig.1A)

Type II: "V"- shaped notch having STL more than MD (Fig.1B)

Type III: "U"- shaped notch having MD more than STL. (Fig.1C)

Type IV: "J"- shaped notch with a groove at its one end. (Fig.1D)

Type V: U shaped notch presenting a partial ossification at its medial end. (Fig.1E)

Type VI: Notch is converted into foramen by the ossified superior transverse scapular ligament. (Fig. 1F)

Measurements taken for morphometric analysis of suprascapular notch were as follows. (Fig. 2)

Superior Transverse Length (STL): It is the horizontal distance between two upper ends of SSN

Maximum Depth (MD): Vertical distance between deepest point of SSN and midpoint of line joining the two upper ends of SSN.

Middle Transverse Length (MTL): It is the horizontal distance between midpoint of two borders of SSN.

Measurements were not taken in the scapulae having type I (slight indentation) and type VI (completely ossified Superior transverse ligament). Area of SSN was calculated by multiplying STL and MD.

To assess the safe zone distance, following measurements were taken,

The distance between supraglenoid tubercle to SSN at its deepest point. (S1). (Fig. 3A)

The distance between spinoglenoid notch to the midpoint of posterior rim of glenoid cavity (S2). (Fig. 3B)

The morphometric analysis of scapula was done using following measurements.

Maximum Length of Scapula (MLS): Vertical length measured from superior angle to inferior angle of scapula. (Fig 4A)

Maximum Width of Scapula (MWS): Horizontal length measured from medial angle of scapula to infraglenoid tubercle. (Fig. 4A)

Maximum Length of Glenoid Cavity (MLG): Vertical length measured from supraglenoid tubercle to infraglenoid tubercle. (Fig. 4B)

Maximum Width of Glenoid Cavity (MWG): Horizontal length measured from midpoint of anterior rim to midpoint of posterior rim of glenoid cavity. (Fig. 4B)

All the measurements were taken by digital Vernier calipers. Data was tabulated and analyzed statistically.

Results

In all 100 scapulae, suprascapular notch was present. Majority of scapulae had Type II SSN (33%) followed by Type I (22%). Least variety was Type V (4%). 10% of scapulae showed type VI variety of SSN where STSL was completely ossified converting the notch into foramen (Type VI). Type III SSN was seen in 18% of scapula and Type IV in 13% of scapulae. Various measurements taken for SSN were tabulated in table 1. Area of SSN was found to be least in Type V (36.16 mm²). Maximum area was measured in Type II variety (106.1 mm²).

One of the mean safe zone distances measured was the distance between SSN and supraglenoid tubercle (S1) in 100 scapulae is 30.31+/-3 mm. The greatest mean distance of S1 was seen in scapulae with Type I and Type VI SSN and the least distance was seen in Type V notch. The other mean safe zone distance measured was the distance between spinoglenoid notch and posterior rim of glenoid (S2) is 16.82+/-2.19 mm. Scapulae with Type V SSN showed greatest S2 distance and the Scapulae with Type II notch showed the least mean distance (Table 2). Scapular dimensions in scapulae with various types of SSN are tabulated in table 3. Mean length of all 100 scapulae is 135.12+/-1 mm. Mean width of scapula is 101.69+/-6.8 mm. Mean length of glenoid fossa is 33.83+/- 3.25 mm. Mean width of glenoid fossa is 24.2+/-2.34 mm.

Table 1: Dimensions of various types of suprascapular notch

Type of SSN	Superior transverse length in mm (STL) Mean +/-SD	Middle Transverse length in mm (MTL) Mean +/- SD	Maximum Depth in mm (MD) Mean +/- SD
Type I	-	-	-
Type II	12.83+/-3.22	9.33+/-2.32	8.27+/-1.58
Type III	9.75+/-3.45	8.09+/-3.34	10.64+/-2.13
Type IV	9.12+/-2.84	6.48+/-2.08	6.64+/-1.96
Type V	4.11+/-1.25	5.25+/-1.57	8.8+/-0.78
Type VI	-	-	-

Table 2: Distance between supraglenoid tubercle and suprascapular notch (S1) and distance between spinoglenoid notch and midpoint of posterior rim of glenoid fossa (S2) in scapulae with various types of SSN

Type of SSN	S1 in mm Mean +/- SD	S2 in mm Mean +/- SD
Type I	31.34+/-3.44	17.28+/-2.46
Type II	30.42+/-2.46	16.25+/-2.42
Type III	28.84+/-2.62	17.13+/-1.96
Type IV	30.76+/-3.18	16.41+/-1.62
Type V	27.01+/-3.25	17.99+/-0.52
Type VI	31.10+/-2.65	17.19+/-1.99

Table 3: Scapular dimensions in scapulae with various types of SSN

Type of SSN	Maximum length of scapula (MLS) in mm Mean +/-SD	Maximum width of scapula (MWS) in mm Mean +/- SD	Maximum length of glenoid cavity (MLG) in mm Mean +/- SD	Maximum width of glenoid cavity (MWG) in mm Mean+/-SD
Type I	135.65+/-11.42	102.01+/-6.64	33.96+/-3.81	23.85+/-2.59
Type II	133.33+/-10.51	102.10+/-6.96	33.79+/-2.99	24.12+/-1.97
Type III	139.99+/-12.27	101.34+/-6.85	33.83+/-3.03	24.51+/-2.39
Type IV	130.83+/-11.66	98.93+/-7.72	33.11+/-3.97	23.83+/-2.59
Type V	126.95+/-12.49	98.43+/-7.68	34.22+/-3.07	23.56+/-3.68
Type VI	139.97+/-5.89	105.13+/-4.4	34.52+/-2.78	25.39+/-2.07

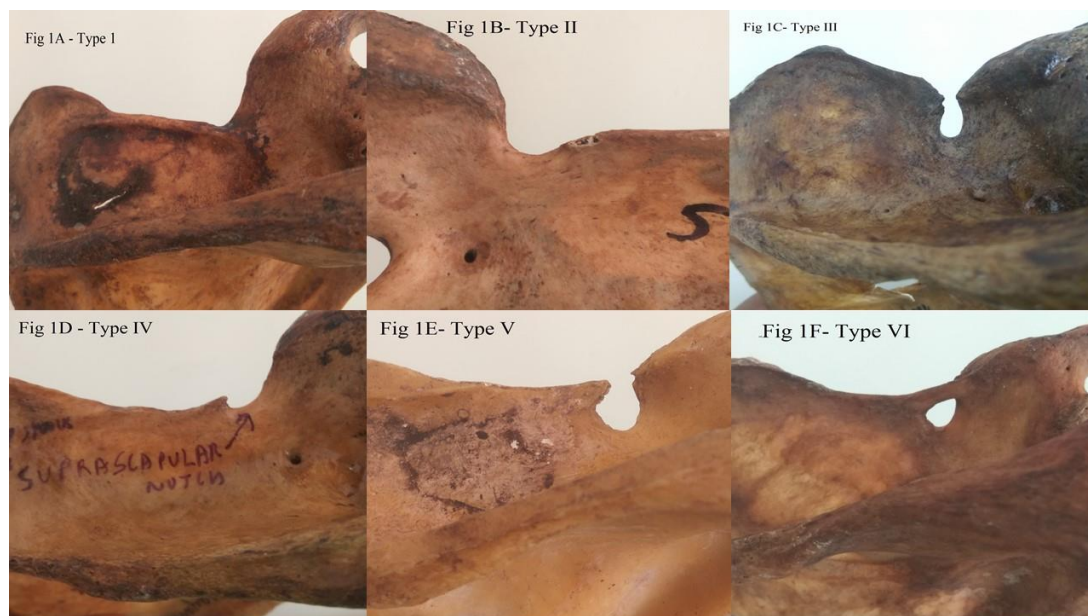


Fig. 1: Various types of suprascapular notches

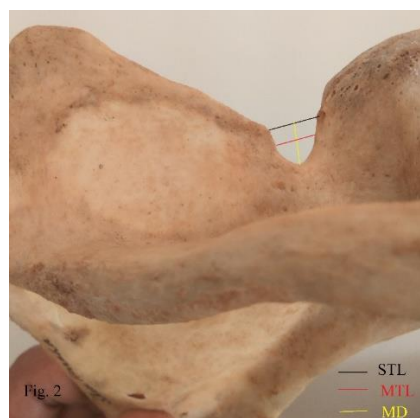


Fig. 2: Measurement of superior transverse length, middle transverse length and maximum depth of SSN

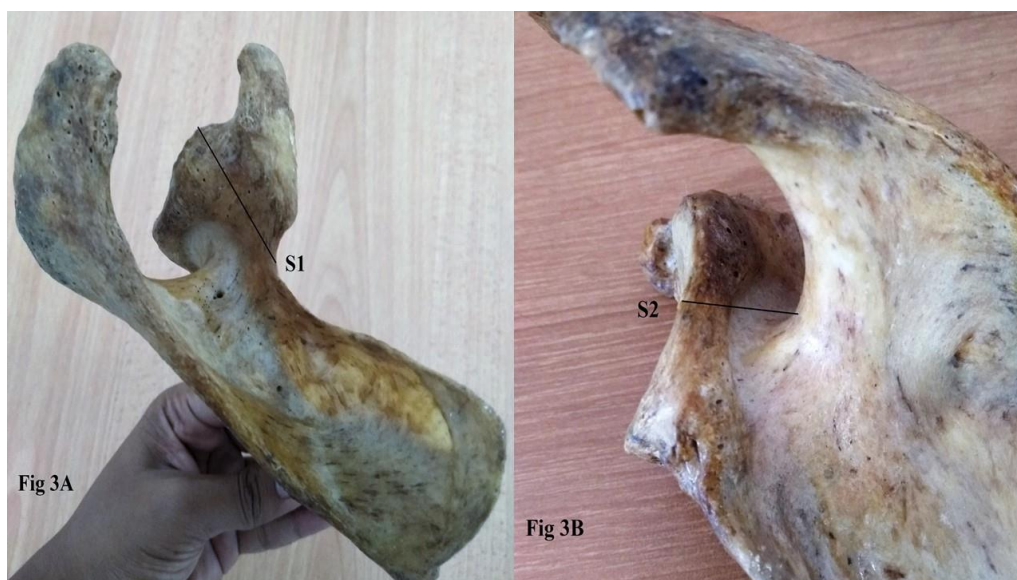

Fig. 3: Measurement of safe zone distance in scapula

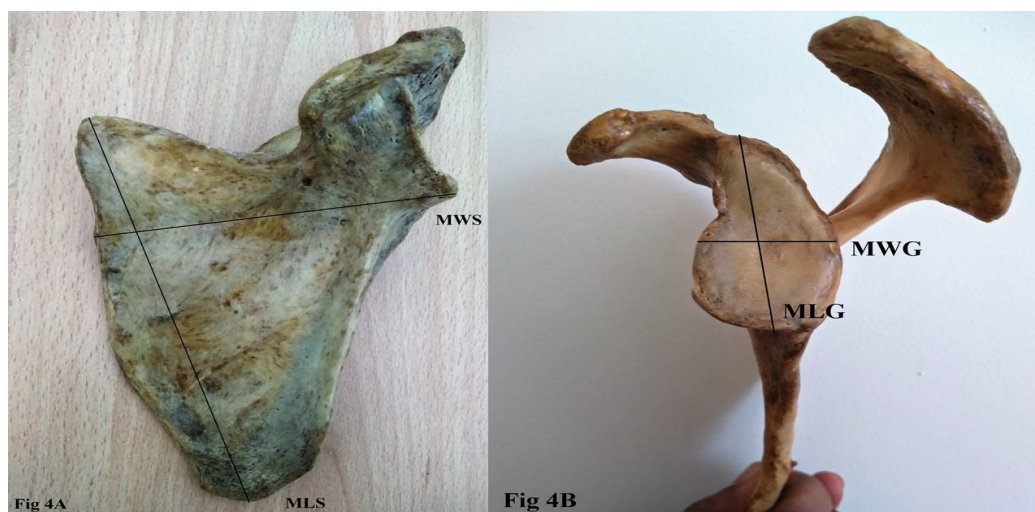

Fig. 4: a) Measurement of maximum length and maximum width of scapula; b): Measurement of maximum length and maximum width of glenoid cavity

Table 4: Comparison of percentage of scapulae falling short of S1 and S2 critical safe zone distances with other studies

Authors	Percentage of scapulae falling short of S1	Percentage of scapulae falling short of S2
Sinkeet et al., 2010 ⁷	5.9%	12%
Sangam MR et al., 2013 ⁸	2.8%	8.6%
Philip SE et al., 2017 ⁹	3%	21%
Present study	1%	10%

Discussion

Rengachary et al.,³ Natsis et al.,⁶ Sinkeet et al.,⁷ Sangam et al.⁸ and Philip et al.⁹ concluded in their study that type III SSN is most common and type VI SSN is least common. Our findings correlate with the findings in the above-mentioned studies in having Type III SSN being most common. But least common variety of SSN found in our study is type V variety (4%). 10% of scapulae showed type VI SSN where STSL is completely ossified converting

notch into foramen. This is a significant number as entrapment is more common in scapulae with type VI variety of SSN.

In order to perform the shoulder arthroscopic surgeries without injuring the suprascapular nerve, there should be a minimum safe zone distance. According to the work done by De Mulder et al.,¹⁰ safe zone distance between supraglenoid tubercle to SSN (S1) should be at least 2.3 cm and safe zone distance between spinoglenoid notch and

posterior rim of glenoid (S2) should be at least 1.4 cm to perform surgeries without injuring the nerve. In the present study, mean distance of S1 and S2 are 30.31±3 mm and 16.82±2.19 mm respectively. But 1 out of 100 scapulae (1%) and 10 out of 100 scapulae (10%) are falling short of above mentioned critical safe zone distances i.e. S1 and S2 respectively. Further, scapulae with type V SSN and type II SSN have least S1 and S2 distance respectively. This shows that the required safe zone distance may be inadequate for the surgeries in those patients having above mentioned types of SSN. This requires an extra caution while performing open surgical procedures to avoid nerve injuries in such individuals.

Length of scapulae was found to be maximum in scapulae with type III SSN and least in scapulae with type V notch. Width of scapulae was maximum in scapulae with type VI notch and minimum in scapulae with type V notch. Length of glenoid cavity was maximum in scapulae with type VI notch and minimum in scapulae with type IV notch. Width of glenoid cavity was maximum in scapulae with VI notch and minimum in scapulae with type V notch.

Surface area of suprascapular notch was found to be least in type V variety. There might be higher incidence of nerve entrapment in scapulae with type V SSN. But Alon M et al.¹¹ concluded in their study that the type of SSN does not correlate directly with entrapment syndrome.

Conclusion

One of the site of compression of suprascapular nerve is the suprascapular notch. This study is an attempt to add further data to the existing studies about SSN and safe zone limit to avoid iatrogenic injuries to suprascapular nerve during surgeries. Further this study gives a correlation between various types of SSN and morphometry of scapulae.

List of Abbreviations

SSN	- Suprascapular notch
STSL	- Superior transverse scapular ligament
STL	- Superior transverse length
MD	- Maximum depth
MTL	- Middle transverse length
MLS	- Maximum length of scapula
MWS	- Maximum width of scapula
MLG	- Maximum length of glenoid cavity
MWG	- Maximum width of glenoid cavity
SD	- Standard deviation
mm	- Millimeter
cm	- Centimeter

Conflict of Interest: None.

References

1. Susan standing. Gray's Anatomy. 40th edition. Churchill Livingstone 2008; 794-795, 820-1.
2. Kyung Wan Chung, Harold M. Chung. Bones and joints. In: Gross Anatomy. 6th ed. Philadelphia: Lippincott Williams & Wilkins; 2008:19.

3. Rengachary SS, Neff JP, Singer PA, Brackett CF. Suprascapular entrapment neuropathy. A clinical, anatomical and comparative study, Part I. *Neurosurg* 1979;4:441-6.
4. Shishido H, Kikuchi S. Injury of suprascapular nerve in shoulder surgery: An anatomic study. *J Shoulder Elbow Surg* 2001;10:372-76.
5. Gumina S, Albino P, Glaracuni M, Vesti AR, Ripani M, Postachini F: Safe zone for avoiding suprascapular nerve injury during shoulder arthroscopy: An anatomical study on 500 dry scapulae. *J Shoulder Wlbow Surg* 2011;20(8):1317-22.
6. Natsis K, Totlis T, Tsikaras P, Appell HT, Skandalakis P, Koebeke J. Proposal for classification of suprascapular notch: a study on 423 dried Scapulas. *Clin Anat* 2007;20:135-9.
7. Sinkeet SR, Awori KO, Odula PO, Ogeng JA, Mwachaka PM. The suprascapular notch: its morphology and distance from the glenoid cavity in Kenyan population. *Folia Morphol* 2010;69(4):241-5.
8. Sangam MR, Sarada Devi SR, Krupadanam K, Anasuya K. A study on the morphology of suprascapular notch and its distance from glenoid cavity. *J Clin Diagn Res* 2013;7(2):189-92.
9. Philip SE, Dakshayani KR. A morphometric study of suprascapular notch and its safe zone. *Int J Ant Res* 2017;5(2.1):3766-70.
10. De Mulder K, Marynissen H, Van Laere C. Arthroscopic transglenoid suture of bankart lesion. *Acta Orthop Belg* 1998;64:160-6.
11. Alon M, Weiss S, Fischel B and Dekel S. Bilateral suprascapular nerve entrapment syndrome due to anomalous transverse scapular ligament. *Clin Orthop* 1998;234:31-3.

How to cite this article: Chaitra BR, Raviprasanna KH, Anitha MR. An anatomical study on various types of suprascapular notch, its relation with glenoid cavity and morphometry of scapula in south Indian population. *Indian J Clin Anat Physiol* 2019;6(2):233-7.