

## A four year journey to success MTA repair

Shalya Raj<sup>1</sup>, Rohit Arora<sup>2</sup>, Vineeta Nikhil<sup>3</sup>, Suhail<sup>4</sup>, Preeti Mishra<sup>5,\*</sup>

<sup>1,2</sup>Reader, <sup>3</sup>Professor & HOD, <sup>4</sup>Professor, <sup>5</sup>Lecturer, Dept. of Conservative Dentistry & Endodontics, Subharti Dental College, Swami Vivekanand Subharti University, Meerut, Uttar Pradesh, India

**\*Corresponding Author:**

Email: preeti.prajesh@gmail.com

### Abstract

**Aim:** This case report presents the healing potential of MTA along with its properties of bone formation and apexification. A cystic lesion was successfully resolved with the use of MTA and the follow up proves success. In cases of combined issues of resorption, abscess, cystic lesion and open apices, MTA seems to be the material of choice.

**Summary:** Access was prepared, biomechanical preparation was done and medicament was placed. Thereafter an MTA plug was made and the canals were obturated. MTA discovery has provided the clinicians with a wonder material which can help to manage multi problem related cases efficiently and successfully.

**Keywords:** Apexification, Mineral Trioxide Aggregate, Non Surgical Healing, Obtura, Periapical Cyst.

### Introduction

In teeth with incomplete root development as a consequence of pulp necrosis through trauma or caries. Endodontic treatment of immature teeth with necrotic pulps and open apices involves induction of apical closure by apexification procedures to create optimal conditions for conventional root canal treatment.<sup>1</sup>

Conventional use of calcium hydroxide apical barrier has been associated with unpredictable apical closure, risk of reinfection, patients compliance, susceptibility to root fracture due to prolong exposure of calcium hydroxide with radicular dentin. With cutting edge researches and advancement in the medical technology newer materials developed In search of a novel one. With the introduction of calcium silicate based Mineral Trioxide Aggregate (MTA) by Torabinejad in 1993 the concept of single step apexification gained popularity. MTA is one such material which has been experimented, used and clinical results proved. Due to its favorable sealing ability, bioactivity and biocompatibility, MTA could serve as a barrier at the apex of the root canal in teeth with necrotic pulps and open apices to permit vertical condensation of warm gutta-percha in the remainder of the canal.<sup>2</sup>

This paper report a case of periradicular cyst of 2.0cm by 2.5cm dimension healed completely owing to the use of MTA hence establishes the osteogenic, antimicrobial and apexification potential of the biomaterial and avoided the surgical morbidity.

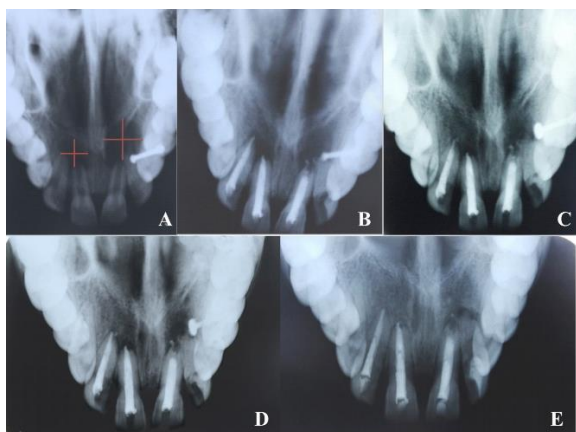
### Case History

A 15 year old female patient reported to the Department of Conservative and Endodontics with the chief complaint of pain in the upper front region of the jaw accompanied with intermittent swelling. History revealed trauma at the age of around 8 years with no

treatment obtained thereafter. The pain was described as intermittent accompanied with swelling every now and then. On clinical examination, the teeth were found tender on percussion associated with vestibular tenderness and grade 1 mobility in relation to 11, 12, 21 and 22. Vitality test was done with electric pulp tester. There was no response on EPT in relation to 11, 12, 21 and 22. Radiograph interpretate a well defined periapical radiolucency with corticated margin in relation to 11 and 12 of 2.0cm \* 2.5cm in dimension while in 21 and 22 periapical radiolucency with hazy margin and open apex of involved teeth was observed with evidence of external root resorption in relation with 21. There was no any other relevant medical or dental history was found.

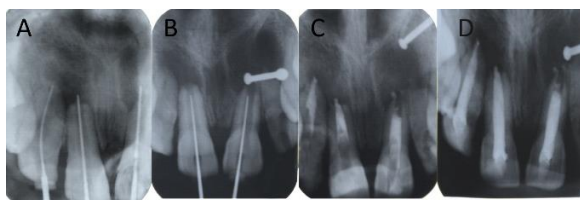
Patient was known allergic to latex therefore rubber dam was not applied. Access cavity preparation was done in 11 12 and 21. The canal of 22 was calcified hence the tooth was left as it is. Working length was determined, biomechanical preparation was done till K file no. 80 for the central incisors, and no.60 for the lateral incisor. Irrigation was done with normal saline owing to the open apices. Canals were filled with metapex (Meta BIOMED), temporary filling with Cavit (3M) was done and patient was recalled after two weeks. The canals were reopened, irrigated, recapitulated and checked for discharge from the canals till two subsequent visit until found dry. An MTA (ProRoot MTA, Dentsply) was made in 11.12 and 21. The material was packed against the bone and was pushed slightly beyond the working length. Any excess material left in the canal was removed using the ISO 140 no. K-File. A radiograph was taken to confirm the placement of the barrier. The plug was covered with moist cotton. Temporary restoration was done with Cavit and patient was recalled after 24 hours. Thereby the temporary filling was removed. Canals were obturated with Obtura (SybronEndo), and coronal seal

was done using Glass Ionomer Cement. (Fig. 1: The series of procedures followed)



**Fig. 1: A: Pre operative OPG showing Periapical radiolucency with 11, 12, 21, 22; B: One year follow up; C: Two year follow up; D: Three year follow up; E: Four year follow up. The Apexification is almost complete, Bone has been reformed. (It may be noted that the bone quality is similar to the unaffected bone.)**

The follow up was done every 3-6 months for a period of 4 years. A complete healing pattern was observed. (Fig. 2: Series Of follow up)



**Fig. 2: A, B: Determination of WL; C: MTA plug; D: Obturation**

## Discussion

Calcium silicate based materials seem to have intrinsic properties suitable for their clinical use, such as good sealing correlated to expansion, and the ability to set in the presence of fluids, bioactivity, the release of ions acting as epigenetic signals, and good biological properties.<sup>3</sup> MTA releases a high concentration of calcium ions into the tissue fluid by dissociation of calcium hydroxide into calcium and hydroxyl ions, thus creating an alkaline environment which assist in the healing of pulp and periapical tissue and increased antimicrobial activity.<sup>4</sup> Many studies have been done, clinical reports presented, follow ups done to prove the anti-microbial and osteogenic potential of MTA.<sup>5,6</sup>

Earlier calcium hydroxide had been the choice of material for apexification to induce the formation of calcific barrier however this involved repeated changes of dressings over the course of 5-20 months.<sup>7</sup> The unpredictable and often lengthy course of this treatment modality presented challenges, like the vulnerability of

the temporary coronal restoration to re-infection<sup>8</sup>, variability of treatment time (average 12.9 months), difficulty of the patients recall management, delay in the treatment and increase in the risk of tooth fracture due to extended periods of calcium hydroxide application.<sup>9</sup>

On the other hand, MTA has several advantages when compared with the calcium hydroxid. These are (1) less treatment time, (2) resistant the tooth to fracture and (3) the patient requires less visits to the dental office.<sup>10</sup>

Many authors have been reported the superior properties of MTA when compared to calcium hydroxide and to the osteogenic protein-1 in terms of antimicrobial property, apical sealing ability and regeneration of periodontium in close vicinity as added advantage of biomaterial.<sup>11-13</sup>

The apex of a tooth should be considered as a dynamic area, capable of self repair<sup>14,15</sup> in line with the same, many researchers have advocated using tricalcium phosphate as an immediate apical barrier against which gutta-percha could be condensed without inducing a natural apical barrier.<sup>16,17,18</sup> In fact, the concept of obturating teeth with immature apices without first inducing a natural apical barrier is not new; several investigators have likewise indicated that success is attainable with this approach.<sup>10,11</sup>

This case report hence once again establishes the miraculous healing properties of success, proclaiming success in conjugation with the criteria defined by Stewart D 1963.

Success treated tooth must meet the following requirements; absence of symptoms, absence of mobility, absence of a radiolucency adjacent to the perforation, thickness of the periodontal ligament adjacent to the obturating material no more than double the thickness of the adjacent ligament.

**Funding:** No funding sources.

**Conflict of interest:** None declared.

## References

1. Kaizer OB, Bonfante G, Filho LD, Cardinal L, Reis KR. Utilization of biological posts to reconstruct weakened roots. *Rev Gaucha Odontol* 2008;56:7-13.
2. Torabinejad M, Chiavian N: Clinical applications of mineral trioxide aggregate. *J Endod* 1993;25:197-205.
3. Koulaouzidou EA., Economides N, Beltes P, Geromichalos G Papazisis K *in vitro* Evaluation of the cytotoxicity of ProRoot MTA and MTA Angelus. *J Oral Sci* 2008;50(4):397-402.
4. FILHO T, Simone WATANABE, Luciano Tavares Angelo CINTRA, NERY M J, Júnior ED, Queiroz IOA. pH and calcium ion release evaluation of pure and calcium hydroxide-containing Epiphany for use in retrograde filling. *J Appl Oral Sci* 2011;19(1):1-5.
5. Lemon RR. Nonsurgical repair of furcal perforations with defects. *Dent Clin North Am* 1992;36(2):439-57.
6. Koh, E.T, Ford P, Torabinejad M, McDonald F. Mineral trioxide aggregate stimulates cytokine production in human osteoblasts. *J Bone Min Res* 1995;10:406-11.

7. Rafter M. Apexification: a review. *Dent Traumatol* 21(1):1-8.
8. Magura ME, Kafrawy AH, Brown CE Jr, Newton C. Human saliva coronal microleakage in obturated root canals: An in vitro study. *J Endod* 1991;17(7):324-31.
9. Andreasen JO, Munksgaard EC, Bakland LK. Comparison of fracture resistance in root canals of immature sheep teeth after filling with calcium hydroxide or MTA. *Dent Traumatol* 2006;22(3):154-6.
10. Duell RC. Conservative endodontic treatment of the open apex in three dimensions. *Dent Clin North Am* 1973;17:125.
11. Adamo HL, Buruiana R, Rosenberg PA., Schertzer L, Kahn FF, Boylan R. Bacterial assay of coronal microleakage: MTA, SuperEBA, composite, amalgam retrofillings. *J Endod* 1996;22:196.
12. Adamo, HL, Buruiana R, Schertzer L, Boylan RJ. A comparison of MTA, SuperEBA, composite and amalgam as root-end filling materials using a bacterial microleakage model. *Int Endod J* 1996;32:197.
13. Bates CF, Carnes DL, Del Rio CE. Longitudinal sealing ability of mineral trioxide aggregate as a root-end filling material. *J Endod* 1996;22:575.
14. Wu MK, Kontakiotis EG, Wesselink PR "Long term seal provided by some root end filling materials. *J Endodo* 2008;24:557.
15. Zeldow, LL. Endodontic treatment of vital and non-vital immature teeth. *New York State Dent J* 1967;33:327.
16. Goodell GG, Mork TO, Hutter JW, Nikoll BK. Linear dye penetration of a calcium phosphate cement apical barrier. *J Endod* 1997;23:174.
17. Stewart D. Root canal therapy in incisor teeth with open apices. *Br Dent J* 1963;114:249-54.
18. Coviello J and Brilliant JD. A preliminary clinical study on the use of tricalcium phosphate as an apical barrier. *J Endod* 1979;5:6.

**How to cite the article:** Raj S., Arora R., Nikhil V., Suhail, Mishra P. A four year journey to success MTA repair. *IP Indian J Conserv Endod* 2018;3(3):98-100.