

Utility of dermoscopy in nail psoriasis: Its correlation with the Nail Psoriasis Severity Index (NAPSI) and psoriatic arthritis

Akbar Ali Shanavaz¹, Amina Asfiya^{2*}, Manjunath Shenoy³, Vishal B⁴

¹Post Graduate, ²Senior Resident, ³HOD, ⁴Professor, ¹⁻⁴Dept. of Dermatology, ¹⁻⁴Yenepoya Medical College Hospital, Derlakatte, Mangalore Karnataka, India

***Corresponding Author: Amina Asfiya**

Email: dr.akbaralishanavaz87@gmail.com

Abstract

Introduction: Nail changes are present in 25-50% of patients with psoriasis with higher frequency in arthritis. Dermoscopy can be a useful tool for better visualization and quantifying the nail defects.

Aim of the Study: To evaluate the dermoscopic findings in nail psoriasis.

Settings and Design: Hospital based cross sectional descriptive study.

Materials and Methods: 110 clinically diagnosed psoriatic fingernails were included in the study. The Nail Psoriasis Severity Index (NAPSI) scores were recorded. Dermoscopic evaluation was conducted and the features were recorded. Comparison of features was done with mild, moderate and high NAPSI groups and arthritic and non-arthritic patients. Statistical analysis included percentages, frequency, chi square test and Fischer's exact test.

Results: The most common dermoscopic findings included subungual hyperkeratosis (90.9%), onycholysis (64.5%) and pitting (62.7%). Pitting, nail plate thickening, transverse grooves, trachyonychia, and onycholysis were associated with higher NAPSI scores ($p < 0.05$). Nails of arthritis patients had significantly higher NAPSI scores ($p = 0.004$). Corresponding dermoscopic evaluation revealed subungual hyperkeratosis, transverse grooves, pitting, onycholysis and trachyonychia to be more frequent in higher NAPSI groups and transverse grooves, nail plate thickening and trachyonychia in arthritic patients.

Conclusion: Dermoscopy coupled with NAPSI scoring in nail psoriasis can serve as a useful guide to assess the nail, cutaneous and arthritic psoriasis.

Keywords: Dermoscopy, Nail psoriasis, NAPSI.

Key Messages: Various specific and non specific dermoscopic features of nail psoriasis can help in early diagnosis and assessment of the disease severity.

Introduction

Psoriasis is a common immune mediated dermatosis which is chronic and seen globally. It has a bimodal age distribution with no sexual predilection.¹ Clinically, it manifests as well demarcated plaques with silvery white scales, with a predilection for the extensor surfaces of the body such as elbows, knees, lower back and scalp.^{1,2} Nail changes are seen in 50% of cases, and maybe considered as a reason for significant morbidity due to the pain and aesthetic appearance.³⁻⁵ In addition to this, nail psoriasis is connected to psoriatic arthritis. It is estimated that 87% of patients with psoriatic arthritis show nail involvement.³ Dermoscopy is a useful and feasible diagnostic technique which helps in *in vivo* evaluation of pigmentary skin lesions.⁶ Recently, dermoscopy has been considered a useful modality for the clinical assessment of nail disease.⁷ The aim of the present study was to evaluate the dermoscopic findings in nail psoriasis.

Materials and Methods

A total of 110 finger nails were studied from patients in all age groups and both sexes with clinical diagnosis of nail psoriasis recruited over a period of 2 months. It was a hospital based cross sectional descriptive study. Only the clinically visible psoriatic fingernails were selected; toe nails were excluded because of anticipated gross nail dystrophies due to trauma and other causes that could

interpret with clinical and dermoscopic evaluation. All the participants gave written informed consent. Patients in remission following the systemic treatment of psoriasis and those who had other associated dermatological and systemic diseases that are likely to cause nail changes were excluded from the study. Relevant demographic and clinical data such as patient's age, sex, duration of disease, joint symptoms, cutaneous and nail changes were noted. Nails were examined clinically; specific and non-specific findings of psoriatic nail were recorded. Nail Psoriasis Severity Index (NAPSI) scores were calculated and graded as mild (0-2), moderate (3-5) and severe (6-8). Only fingernails with a NAPSI score of ≥ 1 were included for the dermoscopic study. Dermoscopic examination was carried out using Heine Delta 20 plus dermatoscope with a magnification of 10X and the findings were noted (table 1). Polarised light and ultrasound gel as interface medium were used to visualize the nail bed features. The collected data was summarized by frequency and percentages. Association of dermoscopic features of nail psoriasis with NAPSI score was assessed. Comparison of NAPSI and dermoscopic findings was also performed. Statistical analysis of the findings by chi square test, Fischer's exact test and Mann-Whitney test was done. Analysis was performed using SPSS -17 software; p value of < 0.05 was considered statistically significant.

Results

These 110 nails included a total of 19 patients, 12 patients were male (63.2%) and 7 were females (36.8%), and they were aged between 26-70 years (mean age 44.2 years). The duration of psoriasis ranged from 2 months to 20 years (mean duration 51.8 months). Joint disease (Psoriatic arthritis) was detected in 3(15.78%) out of the 19 patients; among them 2(10.5%) showed involvement of all 10 fingernails. The mean NAPS I score was 4 (Range 1 - 8).

The dermoscopic features observed have been shown in the table 2. The most common dermoscopic findings of nail psoriasis in our study included subungual hyperkeratosis (90.9%), onycholysis (64.5%) and pitting (62.7%). The other features included nail plate thickening (26.4%), transverse grooves (25.5%), Leukonychia (23.6%), Salmon patch (21.8%), splinter hemorrhages (8.2%) and trachyonychia (7.3%).

We attempted to correlate the nail findings with the severity of nail disease by categorizing them in to 3 NAPS I groups which has been summarized in table 3. Mild NAPS I scores (1-2) were found to be commonly associated with splinter hemorrhages, followed by subungual hyperkeratosis and onycholysis. With respect to moderate NAPS I scores (3-5) we found that Leukonychia was the commonest

finding followed by salmon patch, pitting and subungual hyperkeratosis. Higher NAPS I scores (6-8) were seen in patients have dermoscopic findings of nail plate thickening, transverse grooves and trachyonychia. Among these findings association of splinter hemorrhage with mild and moderate NAPS I, and transverse groove and nail plate thickening with high NAPS I were highly significant. Nail plate thickening, Transverse grooves and trachyonychia were seen at higher frequency with high NAPS I group and Pitting and onycholysis were seen at higher frequency with moderate and high NAPS I groups. These findings were statistically significant. Splinter hemorrhages were seen at higher frequency in the mild and moderate NAPS I groups but these findings were statistically not significant.

We compared the NAPS I scores of patients with and without arthritis. We found a mean NAPS I of 5.39 for the arthritis patients as compared to 3.63 for the non-arthritis patients. The difference in the scores was statistically significant (Mann-Whitney test p value of 0.004). Nail plate thickening, transverse grooves and trachyonychia were found at higher frequency with arthritis group and the finding was statistically significant.

Table 1: Dermoscopic description of the nail findings

Feature	Dermoscopic Appearance
Pitting	Irregular depressions with sharp margins
Leukonychia	Irregular opaque chalky white irregular spots
Onycholysis	Uniform whitish area with longitudinal striations with reddish - orange halo
Salmon patches	Irregular homogenous yellow to orange spots
Splinter hemorrhages	Longitudinal black, purple or brown marks

Table 2: Individual dermoscopic features observed in the study (n=110)

Dermoscopic features	Present	
	Number	%
Subungual hyperkeratosis	100	90.9%
Onycholysis	71	64.5%
Pitting	69	62.7%
Nail plate thickening	29	26.4%
Transverse grooves	28	25.5%
Leukonychia	26	23.6%
Salmon patches	24	21.8%
Splinter Hemorrhages	9	8.2%
Trachyonychia	8	7.3%
Dilated hyponychial capillaries	0	0%
Pseudo fiber sign	0	0%
Lunular red spots	0	0%

Table 3: Correlation of dermoscopic features with grades of NAPS I

Dermoscopic Features		Mild NAPS I		Moderate NAPS I		High NAPS I		P value
		Number	%	Number	%	Number	%	
Subungual hyperkeratosis	Absent	4	40.0%	3	30.0%	3	30.0%	0.708
	Present	30	30.0%	43	43.0%	27	27.0%	
Onycholysis	Absent	20	51.3%	16	41.0%	3	7.7%	0.000
	Present	14	19.7%	30	42.3%	27	38.0%	
Pitting	Absent	24	58.5%	15	36.6%	2	4.9%	0.000

	Present	10	14.5%	31	44.9%	28	40.6%	0.000
Nail plate thickening	Absent	33	40.7%	39	48.1%	9	11.1%	
	Present	1	3.4%	7	24.1%	21	72.4%	
Transverse grooves	Absent	34	41.5%	39	47.6%	9	11.0%	0.000
	Present	0	.0%	7	25.0%	21	75.0%	
Leukonychia	Absent	30	35.7%	32	38.1%	22	26.2%	0.136
	Present	4	15.4%	14	53.8%	8	30.8%	
Salmon patches	Absent	31	36.0%	34	39.5%	21	24.4%	0.081
	Present	3	12.5%	12	50.0%	9	37.5%	
Splinter Hemorrhages	Absent	30	29.7%	42	41.6%	29	28.7%	0.464
	Present	4	44.4%	4	44.4%	1	11.1%	
Trachyonychia	Absent	34	33.3%	43	42.2%	25	24.5%	0.036
	Present	0	.0%	3	37.5%	5	62.5%	

Table 4: Difference between the NAPI in the arthritic and non-arthritic patients

Psoriatic arthritis	Total Nails	Mean NAPI	Mann-Whitney test p value
Absent	87	3.63	0.004
Present	23	5.39	
Total	110	4.00	

Table 5: Comparison of dermoscopic features of arthritis and non-arthritis patients

Dermoscopic Features		Psoriatic Arthritis						P value
		Absent		Present		Total		
		Number	%	Number	%	Number	%	
Subungual hyperkeratosis	Absent	9	10.3%	1	4.3%	10	9.1%	0.374
	Present	78	89.7%	22	95.7%	100	90.9%	
Onycholysis	Absent	33	37.9%	6	26.1%	39	35.5%	0.291
	Present	54	62.1%	17	73.9%	71	64.5%	
Pitting	Absent	34	39.1%	7	30.4%	41	37.3%	0.446
	Present	53	60.9%	16	69.6%	69	62.7%	
Nail plate thickening	Absent	71	81.6%	10	43.5%	81	73.6%	0.000
	Present	16	18.4%	13	56.5%	29	26.4%	
Transverse grooves	Absent	73	83.9%	9	39.1%	82	74.5%	0.000
	Present	14	16.1%	14	60.9%	28	25.5%	
Leukonychia	Absent	65	74.7%	19	82.6%	84	76.4%	0.428
	Present	22	25.3%	4	17.4%	26	23.6%	
Salmon patches	Absent	65	74.7%	21	91.3%	86	78.2%	0.087
	Present	22	25.3%	2	8.7%	24	21.8%	
Splinter hemorrhage	Absent	81	93.1%	20	87.0%	101	91.8%	0.339
	Present	6	6.9%	3	13.0%	9	8.2%	
Trachyonychia	Absent	84	96.6%	18	78.3%	102	92.7%	0.003
	Present	3	3.4%	5	21.7%	8	7.3%	

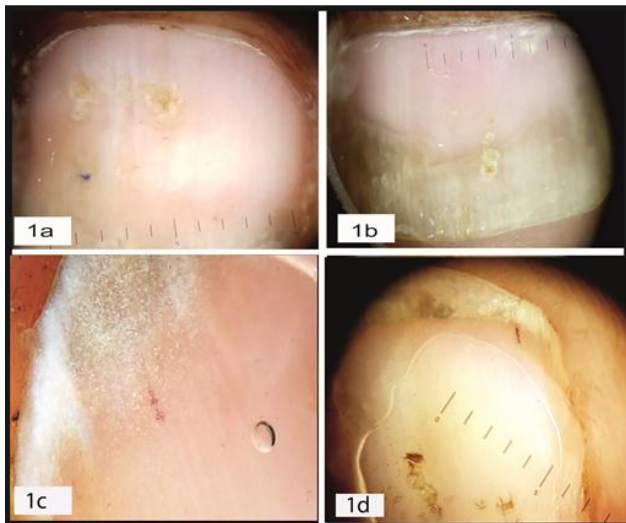


Fig. 1: Leukonychia (a, b) and splinter hemorrhages (c, d)

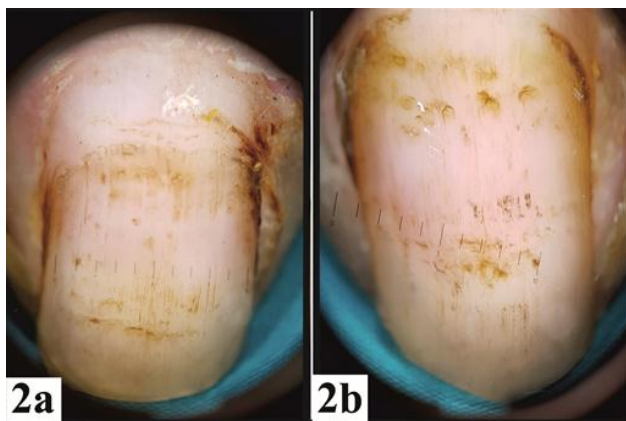


Fig. 2: Nail pitting (a, b)

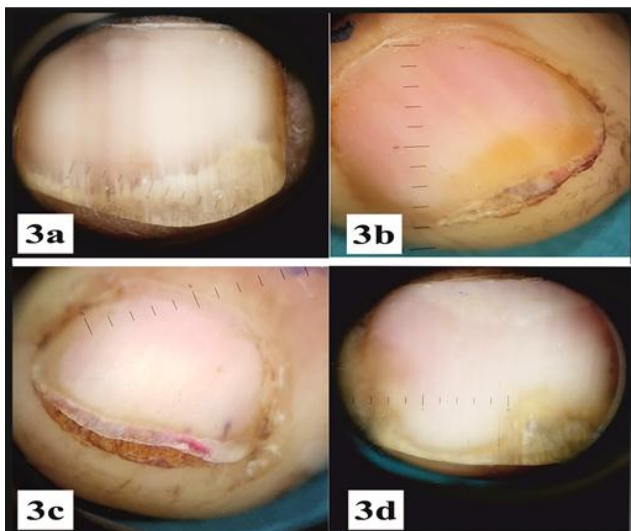

Fig. 3: Onycholysis with subungual hyperkeratosis (a, b, c, d)

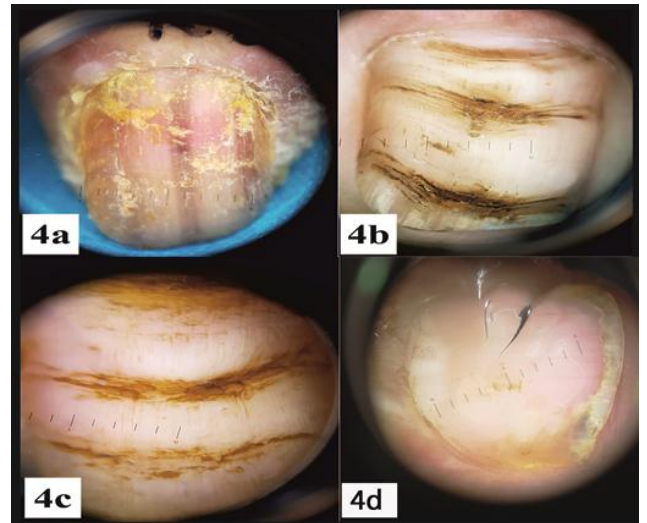


Fig. 4: Nail plate thickening (a), Transverse grooves (b, c) and Salmon patch (d)

Discussion

Nail psoriasis can impact the quality of life of the afflicted patients.^{8,9} Such changes may be more frequent and severe in patients with arthritis.¹⁰ Several scoring systems have been adopted for the nail psoriasis assessment such as Nail Psoriasis Severity Index (NAPSI), modified NAPSI, target NAPSI, Psoriasis Nail Severity Score etc.¹¹ NAPSI was chosen ahead of other scoring systems because it has been widely quoted in scientific literature. Nail involvement includes that of nail bed and nail matrix changes. Nail bed changes include onycholysis, oil drop (salmon patch) sign, splinter hemorrhages, and subungual hyperkeratosis. Nail matrix changes are pitting, Leukonychia, red spots in the lunula and crumbling. NAPSI score evaluates the presence of any of these 8 clinical signs in each quadrant of a fingernail. Nail bed and the matrix change will get 1 score each per quadrant thus totaling to a maximum of 8 score per nail.¹²

Dermoscopy is a user friendly, non-invasive optical tool that has found great utility in the dermatological practice in the recent times. Initially its usage was limited to the pigmented lesions but currently it has been used in variety of disorders like inflammatory, infective, hair and nail disorders.¹³ Nail findings in various diseases such as nail pigmentation, onychomycosis and nail psoriasis also utilizes dermoscopy as a tool of assessment.¹⁴

There is dearth of literature and few studies are available on the dermoscopic features of nail psoriasis.^{7,15,16} A study conducted by Yorulmaz, found that splinter hemorrhages (73.1%), pitting (58.2%), distal onycholysis (55.2%) and salmon patches (22.4%) as the most common dermoscopy features in nail psoriasis.⁷ These findings are similar to our study except for splinter hemorrhages, and we observed subungual hyperkeratosis (90.9%), onycholysis (64.5%), pitting (62.7%) followed by Salmon patch (21.8%) as the most common finding. We did not find the pseudo fiber sign, dilated hyponychial capillaries or lunular red spots as mentioned in this study; these findings may be

visible only on higher magnification of the video dermoscope used in their study.⁷ A study by Yadav et al concluded that pitting, onycholysis and splinter haemorrhages as the most common dermoscopic finding.¹⁶

We grouped the nail disease in 3 categories based on NAPS. Those with mild or moderate disease had association with splinter hemorrhages indicating this could be the earliest manifestation of nail psoriasis. They are caused by the rupture of delicate dilated capillaries between the nail bed and the nail plate, and tracking of blood through the furrows beneath the nail plate.^{9,17} Transverse grooves (Beau's lines) and nail plate thickening are seen with gross nail damage due to psoriasis and hence more frequently seen with high NAPS scores. Transverse grooves occur due to inflammation of the matrix and proximal nail folds.¹⁷ Nail plate thickening is due to the nail bed and hyponychial hyperplasia due to chronic inflammatory process.¹⁸ High NAPS hence may indicate severe cutaneous disease in addition to severe nail disease.

Association of severe nail disease in arthritis patients is known.¹⁹⁻²¹ We attempted to quantify the same by comparing the NAPS of arthritic and non-arthritic patients (5.39 versus 3.63). We found statistically significant difference in the NAPS with higher values in the arthritis group (Mann-Whitney test p value of 0.004). We also attempted to correlate between the dermoscopic features among the two groups and we found that the transverse grooves, nail plate thickening and trachyonychia were significantly more frequent in arthritis patient's nails. Transverse grooves (Beau's lines) are nonspecific that is associated with systemic manifestations of psoriasis like arthritis and many other systemic diseases.^{22,23} Trachyonychia (rough nail) is characterized by brittleness and increased longitudinal ridging. It is also a nonspecific finding that is seen with many dermatological and systemic diseases.²⁴

Current study thus indicates that the NAPS and dermoscopy can be interpreted together to obtain better evaluation of the nail psoriasis. Strength of this study lies in highlighting the dermoscopic and NAPS correlation of common nail changes in psoriasis and psoriatic arthritis. Our study had certain limitations. We used a standard hand held dermoscope however it had low magnification. Our study had a time bound to two months and hence sample size was limited to 110. Higher sample size could have given better insight of these findings.

Conclusion

Dermoscopic examination of nail unit and its components has been termed as onychoscopy.²⁵ Current study on nail psoriasis has highlighted its usefulness as a predictor of severity of cutaneous and joint disease. It can visualize the subtle changes in the nail plate and nail bed thus helping in early diagnosis. Its simplicity and user-friendliness can further be explored to various dermatologic and rheumatologic applications. It can also be used as a tool of prognostication in the psoriasis management.²⁶

Conflict of Interest: None.

References

- Langley RG, Krueger GG, Griffiths CE. Psoriasis: epidemiology, clinical features, and quality of life. *Ann Rheum Dis* 2005; 64 (2): ii18-23.
- Griffiths CE, Barker JN. Pathogenesis and clinical features of psoriasis. *Lancet*. 2007; 370: 263-71.
- Tan ES, Chong WS, Tey HL. Nail psoriasis: a review. *Am J Clin Dermatol* 2012; 13: 375-88.
- Edwards F, de Berker D. Nail psoriasis: clinical presentation and best practice recommendations. *Drugs* 2009;69:2351-61.
- Schons KR, Knob CF, Murussi N, Beber AA, Neumaier W, Monticelo OA et al. Nail psoriasis: a review of the literature. *An Bras Dermatol* 2014; 89: 312-7.
- Zalaudek I, Argenziano G, Di Stefani A, Ferrara G, Marghoob AA, Hofmann-Wellenhof R et al. Dermoscopy in general dermatology. *Dermatol* 2006; 212: 7-18.
- Yorulmaz A, Artuz F. A study of dermoscopic features of nail psoriasis. *Adv Dermatol Allergol* 2017; 34(1):28-35.
- Ortonne JP, Baran R, Corvest M, Schmitt C, Voisard JJ, Taieb C et al. Development and validation of nail psoriasis quality of life scale (NPQ10). *J Eur Acad Dermatol Venereol* 2010;24(1):22-7
- Dogra A, Arora AK. Nail psoriasis: The journey so far. *Indian J Dermatol* 2014;59:319-33
- Zargari O, Leyli EK, Azimi SZ. Nail Involvement in Patients with Psoriatic Arthritis in Northern Iran. *Autoimmune Dis* 2018;15:2018:4608490.
- Klaassen KM, van de Kerkhof PC, Bastiaens MT, Plusjé LG, Baran RL, Pasch MC et al. Scoring nail psoriasis. *J Am Acad Dermatol* 2014;70(6):1061-6.
- Marina EM, Botar-Jid C, Bolboaca SD, Roman II, Senila CS, Miha CM et al. Patterns of clinical nail appearances in patients with cutaneous psoriasis. *Clujul Med* 2017;90(1):22-7
- Errichetti E, Stinco G. Dermoscopy in General Dermatology: A Practical Overview. *Dermatol Ther (Heidelb)* 2016;6(4):471-507
- Alessandrini A, Starace M, Piraccini BM. Dermoscopy in the Evaluation of Nail Disorders. *Skin Appendage Disord* 2017;3(2):70-82.
- Farias DC, Tosti A, Chiacchio ND, Hirata SH. Dermoscopy in nail psoriasis. *An. Bras. Dermatol* 2010;85(1):101-03.
- Yadav TA, Khopkar US. Dermoscopy to detect signs of subclinical nail involvement in chronic plaque psoriasis: A study of 68 patients. *Indian J Dermatol* 2015;60:272-5
- Sobolewski P, Walecka I, Dopytalska K. Nail involvement in psoriatic arthritis. *Reumatologia* 2017;55(3):131-5.
- Schons KR, Knob CF, Murussi N, Beber AA, Neumaier W, Monticelo OA et al. Nail psoriasis: a review of the literature. *An Bras Dermatol* 2014;89(2):312-7.
- Salomon J, Szepietowski JC, Proniewicz A. Psoriatic nails: a prospective clinical study. *J Cutan Med Surg* 2003; 7(4):317-21.
- Williamson L, Dalbeth N, Dockerty JL, Gee BC, Weatherall R, Wordsworth BP. Extended report: nail disease in psoriatic arthritis--clinically important, potentially treatable and often overlooked. *Rheumatol (Oxford)*. 2004; 43(6):790-4.
- Langenbruch A, Radtke MA, Krensel M, Jacobi A, Reich K, Augustin M et al. Nail involvement as a predictor of concomitant psoriatic arthritis in patients with psoriasis. *Br J Dermatol* 2014;171(5):1123-8.
- Singal A, Arora R. Nail as a window of systemic diseases. *Indian Dermatol Online J* 2015;6(2):67-74.
- Pinto M, Shenoy MM, Hegde SP, Amin VB. Psoriasis: Not just skin deep. *Arch Med Health Sci* 2015;3:266-71

24. Gordon KA, Vega JM, Tosti A. Trachyonychia: A comprehensive review. *Indian J Dermatol Venereol Leprol* 2011;77:640-5
25. Grover C, Jakhar D. Onychoscopy: A practical guide. *Indian J Dermatol Venereol Leprol* 2017;83:536-49
26. Hashimoto Y, Uyama M, Takada Y, Yoshida K, Ishiko A. Dermoscopic features of nail psoriasis treated with biologics. *J Dermatol* 2017;44(5):538-41.

How to cite this article: Shanavaz AA, Asfiya A, Shenoy M, Vishal B, Utility of dermoscopy in nail psoriasis: Its correlation with the Nail Psoriasis Severity Index (NAPSI) and psoriatic arthritis. *Indian J Clin Exp Dermatol* 2019;5(2):121-126.