

Managing delayed onset postoperative *Pseudomonas aeruginosa* endophthalmitis

Sikander AK Lodhi^{1,*}, Afia Mirza², P. Ramdas³, Pervaiz Hussain⁴

¹Associate Professor, ²PG Student, ^{3,4}Assistant Professor, Dept. of Ophthalmology, Sarojini Devi Eye Hospital/ Osmania Medical College, Hyderabad, Telangana

***Corresponding Author:**

Email: sikanderlodhi@gmail.com

Abstract

A 58 year old female patient presented with diminution of vision in left eye a week after uneventful manual small incision cataract surgery. Examination showed ciliary congestion, hypopyon and exudative pupillary membrane. AC wash was done and intravitreal antibiotics were given. Vitreous tap revealed *Pseudomonas aeruginosa*, sensitive to ciprofloxacin amikacin, ceftazidime. Endophthalmitis due to a potentially virulent organism improved on appropriate intravitreal antibiotics, not requiring any vitrectomy. Prompt treatment with appropriate intravitreal antibiotics is the most important step in the management of postoperative endophthalmitis.

Keywords: Hypopyon, Intravitreal antibiotics, Postoperative endophthalmitis, *Pseudomonas aeruginosa*.

Introduction

Cataract surgery is the most commonly performed ocular surgery throughout the world. Postoperative endophthalmitis is a rare but the most damaging and distressing complication after cataract surgery causing significant morbidity. The reported incidence of postoperative endophthalmitis worldwide is 0.1% and in Indian scenario it is 0.09%.⁽¹⁾ Several studies have demonstrated that Gram-positive organisms account for nearly 90% of culture positive cases of postoperative endophthalmitis.⁽²⁾

We present a case of acute postoperative endophthalmitis caused by *Pseudomonas Aeruginosa*, a highly virulent Gram negative bacillus.

Case Report

A fifty eight years old lady presented with diminution of vision, redness, and mild pain in her left eye for one day. She had undergone cataract surgery (manual small incision) a week before. Cataract surgery was uneventful and she had a good visual outcome in the immediate postoperative period. Best corrected visual acuity (BCVA) on second postoperative day was 6/9. On examination, her BCVA was Hand Movements. Anterior segment examination showed marked conjunctival and ciliary congestion with corneal epithelial edema, keratic precipitates, marked aqueous flare, 2 mm hypopyon and thick exudative pupillary membrane. Intraocular lens was in position. (Fig. 1) Fundus could not be visualized. Intraocular pressure was 32 mmHg. B-scan ultrasonography showed echo free vitreous cavity with normal RCS complex.

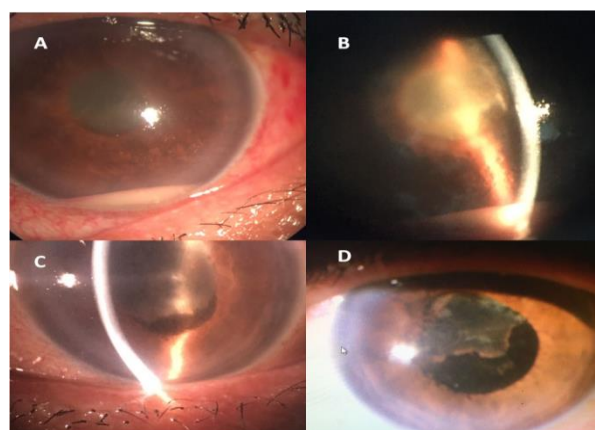


Fig. 1:A. Hypopyon and AC reaction on presentation. B. Exudative pupillary membrane. C, D. Contracting pupillary membrane with clear anterior chamber

The suspicion for endophthalmitis was high, therefore anterior chamber wash with intravitreal antibiotics (vancomycin (1mg/0.1ml), ceftazidime (2.25mg/0.1ml) and dexamethasone(400µg/0.1ml)) was performed. Anterior chamber aspirate along with vitreous tap were sent for culture and sensitivity.

Aqueous tap was subjected to potassium hydroxide (KOH), gram stain and culture/sensitivity. Systemic ciprofloxacin (750 mg twice a day) was started. Twenty four hours later the response was equivocal, therefore intravitreal antibiotics (vancomycin 1mg/0.1ml, and amikacin 200µg/0.1ml) were repeated.

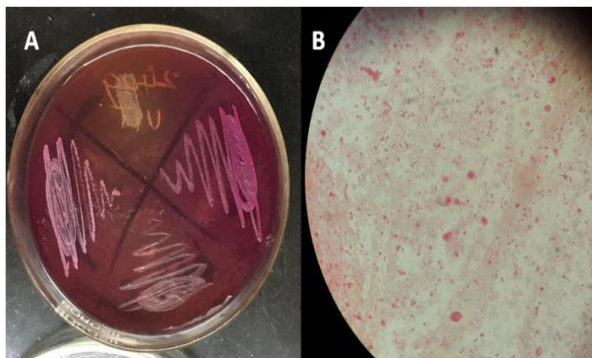


Fig. 2: A. *Pseudomonas* colonies on blood agar. B. Gram-negative bacillus seen on Gram stain

Vitreous tap revealed *Pseudomonas aeruginosa* species sensitive to ciprofloxacin, amikacin, ceftazidime, chloramphenicol, moxifloxacin, gentamycin, tobramycin, gatifloxacin, ofloxacin, cefotaxime, meropenem, cefoperazone sulbactam and co-trimoxazole. (Fig. 2) There was improvement from next day onwards with symptomatic relief, resolution of anterior chamber findings and contraction of the papillary membrane. Fundus was hazily visible and vision was CF 1 meter on fifth day. A week later (almost two weeks after onset), the case had shown a progressive improvement. The cornea was clear, normally reacting pupil with a clear fundus except for some mild vitreous haze and normal details of retina. BCVA was 6/12. (Fig. 3)

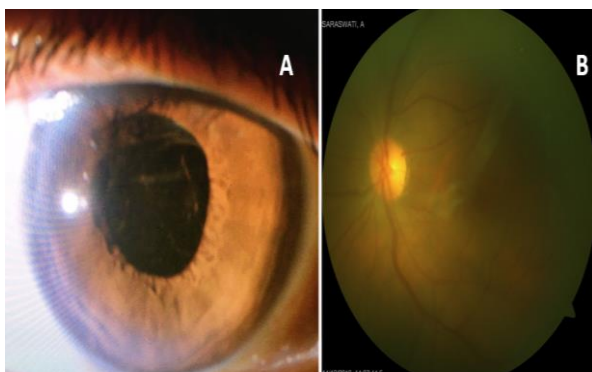


Fig. 3: At 2 weeks follow-up, A. Normal anterior segment. B. Normal fundus

Discussion

Pseudomonas aeruginosa is one of the common Gram negative organisms associated with nosocomial infections.^(3,4) *Pseudomonas* eye infection may be a devastating infection if not treated promptly.⁽⁵⁾ *Pseudomonas* has accounted for approximately 1% of postoperative endophthalmitis cases in Endophthalmitis Vitrectomy Study (EVS).⁽⁶⁾ In large series of acute postoperative endophthalmitis, the incidence of *Pseudomonas* as causative organism ranges from 8 - 34%.^(7,8,9) There are reports of large scale outbreaks of postoperative *Pseudomonas* endophthalmitis due to

contamination. *Pseudomonas* has also been identified in povidone-iodine solution, fluid pathways of a phacoemulsifier and air-conditioning system.⁽³⁾

The visual outcome in *Pseudomonas* postoperative endophthalmitis is usually poor as shown in number of case series and studies.^(3,4,10)

Contrary to the usual poor visual outcome in *Pseudomonas*, this case has shown a very good and prompt response to intravitreal antibiotics. It is our routine protocol to take a tap and promptly give intravitreal antibiotics at the first instance and then to proceed with pars plana vitrectomy depending on the need once the infection is controlled and by then the culture and sensitivity would also be known. There are reports of low-virulence species of *Pseudomonas* causing endophthalmitis. Genomic analysis has shown that the virulence of *Pseudomonas aeruginosa* is both multifactorial and combinatorial.⁽¹¹⁾

References

1. Ravindran RD, Venkatesh R, Chang DF, Sengupta S, Gyatsho J, Talwar B. Incidence of post-cataract endophthalmitis at Aravind Eye Hospital: Outcomes of more than 42,000 consecutive cases using standardized sterilization and prophylaxis protocols. *J Cataract Refract Surg* 2009;35:629-36.
2. Jin A, Choi and Sung Kun Chung. Postoperative Endophthalmitis following Cataract Surgery in Asia. *ISRN Ophthalmol*. 2011;2011:917265.
3. Pinna A, Usai D, Sechi LA, Zanetti S, Jesudasan NC, Thomas PA, et al. An outbreak of post-cataract surgery endophthalmitis caused by *Pseudomonas aeruginosa*. *Ophthalmology*. 2009;116(12):2321-6. Comment in: *Ophthalmology*. 2010;117(8):1657-8;author reply 1658-9.
4. Guerra RL, Freitas Bde P, Parceros CM, et al. An outbreak of forty five cases of *Pseudomonas aeruginosa* acute endophthalmitis after phacoemulsification. *Arq Bras Oftalmol* 2012;75:344-347.
5. Hoffmann KK, Weber DJ, Gergen MF, Rutala WA, Hill C, Tate G, Charlotte. *Pseudomonas aeruginosa*-related postoperative Endophthalmitis linked to a contaminated phacoemulsifier. *Arch Ophthalmol* 2002;120:90-1.
6. Results of the Endophthalmitis Vitrectomy Study. A randomized trial of immediate vitrectomy and of intravenous antibiotics for the treatment of postoperative bacterial endophthalmitis. Endophthalmitis Vitrectomy Study Group. *Arch Ophthalmol* 1995;113:1479-1496.
7. Aaberg TM Jr, Flynn HW Jr, Schiffman J, Newton J. Nosocomial acute-onset postoperative endophthalmitis survey. A 10-year review of incidence and outcomes. *Ophthalmology* 1998;105:1004-1010.
8. Altan T, Acar N, Kapran Z, et al. Acute-onset endophthalmitis after cataract surgery: success of initial therapy, visual outcomes, and related factors. *Retina* 2009;29:606-612.
9. Cheng JH, Chang YH, Chen CL, et al. Acute endophthalmitis after cataract surgery at a referral centre in Northern Taiwan: review of the causative organisms, antibiotic susceptibility, and clinical features. *Eye (Lond)* 2010;24:1359-1365.
10. Sridhar J, Kuriyan AE, Flynn HW, Jr, Miller D. Endophthalmitis caused by *Pseudomonas aeruginosa*: clinical features, antibiotic susceptibilities, and treatment outcomes. *Retina*. 2015 Jun;35:1101-6.

11. Lee DG, Urbach JM, Wu G, Liberati NT, Feinbaum RL, Miyata S, *et al.* Genomic analysis reveals that *Pseudomonas aeruginosa* virulence is combinatorial. *Genome Biol* 2006;7:R90.