

## Microbial keratitis in children-A descriptive study

Elfride Faroich Sanjana<sup>1,\*</sup>, Samuel Cornelius Gnanadurai<sup>3</sup>

<sup>1</sup>Professor, P.I.M.S., Pondicherry, <sup>2</sup>Associate Professor, Dept. of Ophthalmology, Sri Muthukumaran Medical College, Chennai

**\*Corresponding Author:**

Email: elfridesanjana@gmail.com

### Abstract

**Aim:** The purpose of this study is to determine predisposing risk factors, microbiological profile and visual and structural treatment outcome of non viral microbial keratitis in children.

**Materials and Methods:** A prospective case study of 52 eyes with microbial keratitis in a tertiary care teaching institute over a period of two years in children <16 years of age. Data was analyzed for patient demographics, culture data, management trends and visual and structural outcome of treatment.

**Results:** Mean age of patients was 8.22 years ranging from 7 days to 14 years. The most common predisposing risk factor was trauma (57.69%), followed by malnutrition/Vitamin A deficiency (7.69%) unidentified causes accounted for 30.76% of cases. Cultures were taken from all patients. A total of 55.76% of eyes were culture positive. Bacterial isolates were seen in 30.76% of eyes, followed by fungi in 25% of the culture positive isolates. No growth in 44.23% of patients. Gram positive cocci (predominantly *Staphylococcus aureus*) were seen in 11.53% of isolates, and gram negative bacilli (predominantly *Pseudomonas aeruginosa*) in 19.23%. Fungi were identified in 25% of culture positive eyes with equal number of *Aspergillus* and *Fusarium* sp. Monotherapy with broad spectrum antibiotics was the preferred treatment. Final visual acuity on last follow up was < 6/60 in 20 eyes (62.5%) One patient each required therapeutic keratoplasty, conjunctival hooding and cyanoacrylate glue with bandage contact lens.

**Conclusion:** Trauma was the predominant risk factor for microbial keratitis with *Pseudomonas aeruginosa* being the most common microorganism isolated. Majority of the cases responded to medical management.

**Keywords:** Etiology, Bacteria, Fungi, Keratitis, Management, Visual outcome

### Introduction

Cataract and Corneal Blindness is a major public health problem in less developed countries like India.<sup>(1,2)</sup> Corneal blindness is third after cataract and glaucoma among the major causes of vision loss and blindness in the world today.

An estimated 6.8 million people in India have vision less than 6/60, about a million have bilateral involvement.<sup>(3,4)</sup> and this number is estimated to increase to 10.6 million by the year 2020.<sup>(4)</sup> The National Programme for Control of Blindness(NPCB) estimates 120,000 corneal blind persons in the country with a addition of 25,000-30,000 new cases every year<sup>(5)</sup> with ocular trauma and corneal ulceration being the major causes in developing countries.<sup>(6)</sup>

Most corneal blindness is preventable and includes measles infection, Vitamin A deficiency, trachoma, ophthalmia neonatorum, ocular trauma, congenital rubella syndrome and native traditional medications.<sup>(7)</sup> Incidentally these are the most common causes of corneal blindness in children. Institution of preventive or prophylactic measures at the community level can bring down the prevalence of corneal blindness in children.

The causes again vary with age. Corneal scars (28.1%) and active ulcers (12.2%) were the most common indication for keratoplasty in adults in developing nations.<sup>(1)</sup>

In pediatric age group acquired non-traumatic scars (71.32%) were the most common indication for

keratoplasty.<sup>(8,9)</sup> Xerophthalmia, ophthalmia neonatorum, are other important preventable causes of childhood blindness in India.<sup>(10,11)</sup>

Microbial keratitis in children is a challenge to diagnose and treat. Children and their families are frequently unable to provide a complete history of important risk factors such as previous trauma, duration of symptoms. It is difficult to obtain an exact history from older children as they tend to hide factual evidence due to fear of possible parental reprisal. Poor patient cooperation is another factor for the delay in proper diagnosis. It is important to note that corneal infection is particularly relevant to children who by virtue of their young age have a great number of potential seeing years that can be saved and are also at risk for sensory amblyopia.

### Aim

The objective of the study was to determine the etiological agents, predisposing factors and outcome of treatment in terms of structure and visual acuity of microbial keratitis in children.

### Materials and Methods

The study design was a prospective case study of 52 children (16 years and younger) who were treated for non viral microbial keratitis over a period of two years in a tertiary care teaching center. Patients who met the following criteria were included in the study,

1. Corneal stromal infiltrate present with a clinical picture consistent with infectious non-viral ulcer,
2. A corneal scraping was taken at the time of examination for suspected microbial keratitis. Initial examination was performed on those who met the eligibility criteria. The infiltrate location and size were obtained by slit lamp examination using the length and width of the slit to measure the dimensions of the infiltrate with overlying epithelial defect in those patients who were able to cooperate for slit lamp biomicroscopic examination. Ulcers with a midpoint within 2 mm of the geometric center of the cornea were characterized as central, midpoints between 2-4mm of the geometric center were considered paracentral and the remainder was categorized as peripheral. The degree of anterior chamber cells, flare and hypopyon if present was documented. With the use of standard technique corneal scrapings obtained with a sterile blade were inoculated directly into blood, chocolate, non – nutrient agar, Sabarouds dextrose after incubation at 25°C to enhance the growth of fungi and the remainder were incubated at 37°C. Smears were stained by Grams stain and Lactophenol cotton blue. A culture was considered positive when there was growth of the same organism on two or more media, confluent growth at the site of inoculation on one solid medium, growth in one medium with consistent direct microscopic findings, growth of the same organism on repeated scrapings if performed.

All children were examined using topical anesthesia and oral sedation.

The treatment protocol was as follows: for bacterial keratitis Ciprofloxacin (3mg/ml) eye drops was

administered hourly for the first 24-48 hours, then tapered based on the clinical response. Topical tobramycin (14mg/ml) eye drops was instilled hourly if gram negative bacilli were obtained on smear studies. For fungal keratitis 5% Natamycin suspension was administered hourly and tapered based on clinical response to treatment. For deep ulcers regular epithelial debridement was performed to increase drug penetration. Tablet Ketoconazole (3.3mg/kg body weight) was administered in patients in whom the ulcers was greater than 6mm in diameter, deeper than anterior half of the stroma, or if anterior chamber exudate was present. Vitamin A supplementation orally was administered when indicated based on WHO recommendations of 100000 IU once in infants < 1 year, 200000 IU in children older than one year, repeated very 6 months.

### Results

Fifty two children met the inclusion criteria of this study of which 29 (55.76%) were males and 23 (44.23%) were females. There were 31(59.61%) right eyes and 21(40.38%) left eyes involved. Average age group was 8.22 years ranging from 7 days to 14 years.

The predominant predisposing factors for infectious keratitis in the study population is shown in Fig. 1 Trauma associated with 30(57.69%) of cases, amongst which trauma caused by vegetable matter accounted for 11(21.15%) of cases. Other predisposing factors included malnutrition and Vitamin A deficiency in 4 (7.69%) cases. Previous penetrating keratoplasty in the same eye 1(1.92%) and unidentified factors for 16(30.76%) cases. Exposure keratitis with secondary infections was seen in one child with retrobulbar hemorrhage following precipitate labour.

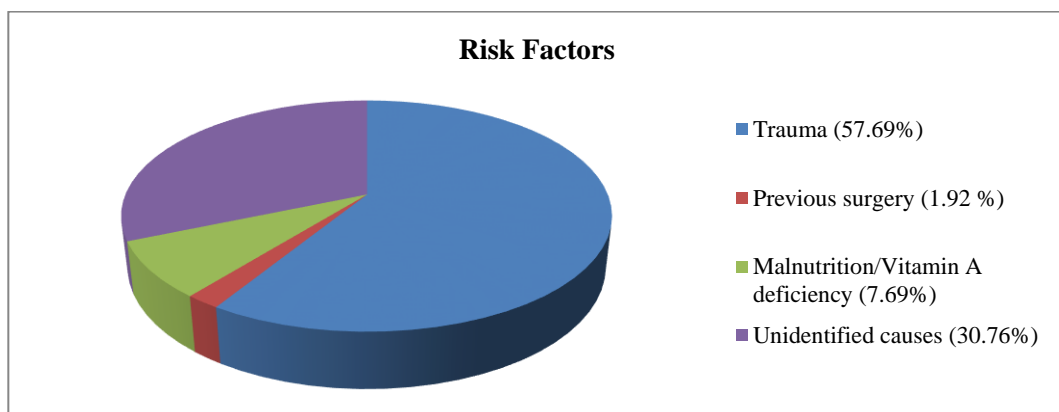
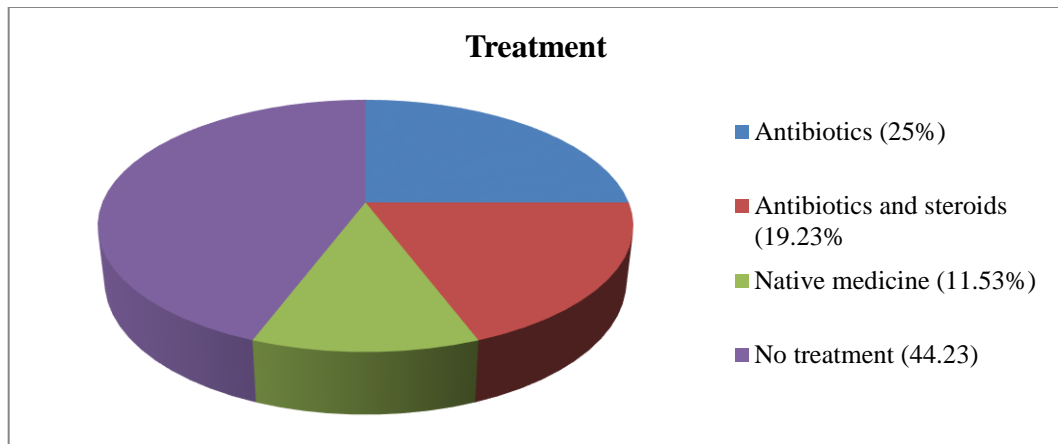


Fig. 1: Risk Factors

Fig. 2: Previous medications applied on presentation showed an indiscriminate use of native medicine and topical steroids.



**Fig. 2: Treatment on presentation**

The location of the supportive infiltrate was central in 29(55.76%) eye, paracentral in 15 (28.89%), peripheral in 5 (61%) and total in 3 (5.76%) eyes. The area of infiltrate was small (<2mm) in 10 (19.23%) eye, medium (2-6mm) in 31(59.61%) and large (>6mm) in 11(21.15%) eyes. Microbiological analysis showed 29(55.76%) of eyes were culture positive. No polymicrobial isolates were identified. Eleven (47.82%) of the 23 culture negative eyes had received previous antibiotic treatment and 14 (48.27%) of the 29 culture positive eyes had received prior antibiotic treatment. Of the 29 culture positive cases 16(30.76%) were positive for bacterial isolates and 13(25%) were positive for fungal isolates. no growth was detected in 23 (44.23%) of cases. Table 1: Microbiological analysis. Of the culture positive group *Staphylococcus aureus* 3 (5.76%), *Streptococcus epidermidis* 1(1.76%) and *Pneumococci* 2(3.84%) were the gram positive cocci isolated. Gram positive cocci accounted for 6(11.53%) cases, Gram negative bacilli for 10 (19.23%) cases, of which *Pseudomonas aeruginosa* accounted for 7 (13.46%) cases. Filamentous fungi accounted for 13(25%) cases with equal number of isolates of *Aspergillus Sp.* And *Fusarium* -5 (9.61%), remaining three being unidentified isolates. Table 2: Treatment outcome. All patients were given topical antimicrobial therapy. One (1.92%) patient required therapeutic penetrating keratoplasty, conjunctival hooding and cyanoacrylate glue with bandage contact lens each. Visual acuity on presentation was as follows: 12 (37.5%) eyes had visual acuity of <1/60, 19(59.37%) eyes had visual acuity ranging between 1/60-6/60. Fig. 3: Visual acuity at last follow up. Visual acuity was estimated in 32 eyes at last follow up. In the remaining 20 eyes, 7 were lost to follow up, and visual acuity could not be assessed in 13 eyes because of inability to co-operate. At last follow up 20 (62.50%) eyes had visual acuity between 1/60-6/60 and 8(25%) eyes achieved visual acuity between 6/36-6/18, one

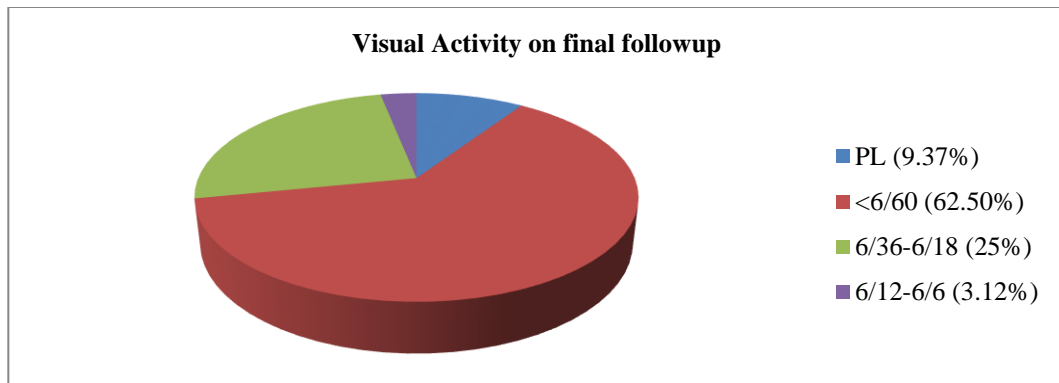
eye(3.12%) had visual acuity >6/12, and 3(9.37%) had visual acuity of perception of light at last follow up. Treatment outcome in terms of structural measures was as follows: Fig. 4: predominant structural outcome at last follow up which ranged between 2days to one year was corneal scar with or without vascularization in 41 (78.84%) cases. Adherent leucoma in 2 (3.84%) cases, disorganized globe in 1(1.92%), opaque graft on 1(1.92%) and 7(13.46%) of patients were lost to follow up.

**Table 1: Microbiological Analysis**

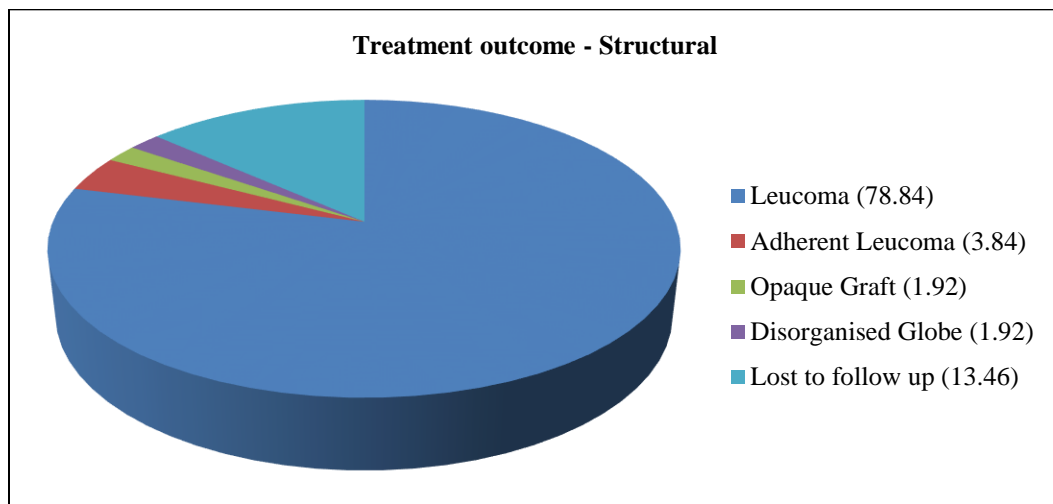
Organism	Number of isolates N=29	Percentage
<b>Gram positive cocci</b>	6	11.53%
<i>Staph. aureus</i>	3	5.76%
<i>Staph. Epidermidis</i>	1	1.92%
<i>Strept. pneumoniae</i>	2	3.84%
<b>Gram negative bacilli</b>	10	19.23%
<i>Pseudomonas aeruginosa</i>	7	13.46%
Unidentified	3	5.76%
<b>Filamentous fungi</b>	13	25%
<i>Aspergillus flavus</i>	4	7.62%
<i>Aspergillus fumigatus</i>	1	1.92%
<i>Fusarium sp.</i>	5	9.61%
Unidentified	3	5.76%

**Table 2: Treatment Outcome**

Treatment method	Number of eyes N=52	Percentage
Medications	52	100%
Therapeutic keratoplasty	1	1.92%
Conjunctival hooding	1	1.92%
Glue with BCL	1	1.92%



**Fig. 3: Visual Activity on final follow-up**



**Fig. 4: Treatment Outcome – Structural**

## Discussion

A population based assessment in children less than 16 years of age, with a large sample size of 1, 13, 514 children in West Godavaru district of Andhra Pradesh revealed corneal opacity was responsible for 11.1% of total burden of blindness in children.<sup>(12)</sup> In another study amongst blind schools across nine states in the country showed that 26% of the blindness in children was due to corneal disease.<sup>(13)</sup> The causes were Vitamin A deficiency 19%, measles 3%, ophthalmianeonatorum 1%, harmful traditional eye medicines 1% and trauma and keratitis in 3%.<sup>(13)</sup> Our study had the limitation of a small sample size, and in contrast to population based studies trauma accounted for the most common risk factor 57.69% with malnutrition associated with Vitamin A deficiency occurring in 7.69% of children. Our study had no case of ophthalmianeonatorum. A significant number of patients gave a history of previous native home remedies 6(11.53%). In a study of blind schools in Maharashtra of the 22.2% of children who had corneal blindness, and one third of the causes of blindness were preventable or from treatable causes.<sup>(14)</sup> This is again in agreement with our study where with trauma and Vitamin A deficiency were the most common

predisposing factors for keratitis. A significant amount of existing data indicates corneal scarring due to Vitamin A deficiency is a major cause of preventable childhood blindness in our country.<sup>(15,16,17,18,19)</sup>

A comparison of predisposing factors shows a significant variation amongst western literature and our country. A recent study by Rossetto JD et al showed contact lens wear (77.6%) as the most common associated risk factor followed by ocular trauma (8.4%) and systemic factors (4.7%).<sup>(20)</sup> Another study by Kunimoto DY et al in an Indian scenario showed results consistent with the findings of our study.<sup>(21)</sup> Trauma accounted for 21.2%, ocular disease for 17.7% and systemic disease for 15.9% of cases of microbial keratitis in children. Vitamin A deficiency was an important cause under systemic diseases and no contact lens was not identified as a risk factor in their study. Yet again in another study by Noureddin GS et al, contact lens was the most common 35% predisposing factor consistent with the rest of western world literature.<sup>(22)</sup> The other causes reported in this study were blepharitis and Steven Johnson syndrome in 18% each. Young et al in their analysis of microbial keratitis of children in Hong Kong identified contact lens wear

as the prevalent predisposing factor in 83.3% of cases and only 5.3% of cases due to trauma.<sup>(23)</sup>

In our study trauma was the most common predisposing factor in 30(57.69%) of eyes followed by unidentified causes in 16(30.76%), and malnutrition with Vitamin A deficiency in 4 (7.69%) of eyes. A stark contrast on the predisposing factors based on the geographic location where the study is conducted exists.

A comparison of microbial analysis was in agreement with most previous studies. Culture positivity was obtained in 29 (55.76%) of eyes with no polymicrobial isolates. Gram negative bacilli *Pseudomonas aeruginosa* was the most common bacterial isolate in 7(13.46%) of eyes followed by *Staphylococcus aureus* in 3(5.76%) of eyes. The predominance of *Pseudomonas* as a causative organism is consistent with the fore mentioned studies by Rosetto JD et al, (46.2%) followed by *Stenotrophomonas maltophilia* (19.2%) and *Fusarium* (13.5%).<sup>(20)</sup> In the study by Nouredin GS et al *Staphylococcus epidermidis* and *Acanthamoeba* and lastly *Pseudomonas* in the contact lens wearers were the most common isolates.<sup>(22)</sup> Young AL et al also published a predominance of *pseudomonas* isolates (62.5%) followed by coagulase negative *Staphylococcus* (31.2%) and *Corynebacterium* sp.(12.5%).<sup>(23)</sup> However Kunimoto et al found a predominance of *Staphylococcus* species in 43.7%, *Streptococci pneumonia* in 18.8% and fungi in 17.2%.<sup>(21)</sup> Our study identified equal number of *Fusarium* and *Aspergillus* isolates but constituted to the predominate microbiological isolate accounting for 13(25%) of culture positive isolates. The higher rates of filamentous fungi may be attributed to the presence of increased fungi in southern climate, higher rate of agriculturally basal livelihood or trauma by organic matter.

Treatment outcome in our study revealed response to topical medication. Systemic antibiotics were indicated in those eyes with corneal thinning /impending perforation(7.69%). Two eyes required surgical intervention, one conjunctival hooding and another cyanoacrylate glue with bandage contact lens. In the study by Rosetto JD et al no patients required keratoplasty.<sup>(20)</sup> Nouredin GS had three patients that needed surgical intervention.<sup>(22)</sup> The requirement of surgical intervention was higher in the study by Kunimoto et al(15.9%).<sup>(21)</sup> Only one patient from the study by Young AL et al required tectonic penetrating keratoplasty.<sup>(23)</sup> The fact that most patients' responded to medical intervention alone is consistent with the results of similar studies on microbial keratitis in children.

Final visual acuity was better than 6/18 in 56% of eyes in the study by Nouredin GS et al.<sup>(22)</sup> Kunimoto et al had 36.4% of eyes improving to 6/18 at last follow up.<sup>(21)</sup> Young AL et al had the best visual outcome in

our comparison with 76.5% of patients having visual acuity of 6/12 on last follow up.<sup>(23)</sup> Prognosis in our study was poorer in comparison with 20 eyes (62.50%) having visual acuity of <6/60 on last follow up and only 8 (25.12%) of eyes having visual acuity between 6/36-6/18. Only one eye had visual acuity of 6/12 amongst the 32 eye that were followed up. Bacterial ulcers had better visual outcome compared to fungal ulcers in our study. Singh G et al in their multivariate analysis of microbial keratitis in south India concluded 69% of the eyes had trauma with organic matter as the most common predisposing cause similar to our study.<sup>(24)</sup> In this study 65.9% of eyes had pure bacterial culture and 38.1% had pure fungal growth. Four (4.1%) eyes had mixed growth. Chirinos, Saldana P et al in their study identified ocular trauma as the most common cause (25%) and *Staphylococcus epidermidis* the most common microorganism isolated.<sup>(25)</sup>

### Conclusion

Trauma was the most common predisposing factor for microbial keratitis in children. A significant proportion of patients' reported indiscriminate use of steroids and native medicine. Medical intervention was successful in treating all except three eyes. A significant variation in the predisposing factors, microbiological profile and visual outcome exists between western world and our literature. Since corneal blindness is preventable emphasis on preventive measures at the community level will reduce the impact of the burden of socioeconomic blindness in these children who have many seeing years ahead.

### References

1. Garg P, Krishna PV, Stratis AK, Gopinathan U. The value of corneal transplantation in reducing blindness. *Eye (Lond)* 2005;19:1106-14.
2. Causes of blindness and visual impairment. [Last accessed on 2011 October 30]. Available from: <http://www.who.int/blindness/causes/en>.
3. National Programme for Control of Blindness. Report of National Programme for Control of Blindness, India and World Health Organization. 1986-89.
4. Dandona R, Dandona L. Corneal blindness in a southern Indian population: Need for health promotion strategies. *Br J Ophthalmol*.2003;87:133-41.
5. National Programme for Control of Blindness. [Last accessed on 2011 October 30]. Available from: <http://pbhealth.gov.in/pdf/Blindness.pdf>.
6. Whitcher JP, Srinivasan M, Upadhyay MP. Corneal blindness: A global perspective. *Bull World Health Organ*. 2001;79:214-21.
7. Noopur Gupta, Radhika Tandon, Sanjeev K Gupta, V Sreenivas, Praveen Vashist. Burden of corneal blindness in India. *Indian J Community Med*.2013 Oct-Dec;38(4):198-206.
8. Dada T, Sharma N, Vajpayee RB. Indications for pediatric keratoplasty in India. *Cornea*. 1999;18:296-8.
9. Aasuri MK, Garg P, Gokhale N, Gupta S. Penetrating keratoplasty in children. *Cornea*. 2000;19:140-44.
10. Thyelfors B, Négrel AD, Pararajasegaram R, Dadzie KY. Global data on blindness. *Bull World Health Organ*.

- 1995;73:115–21.
11. Dandona R, Dandona L. Childhood blindness in India: A population based perspective. *Br J Ophthalmol*.2003;87:263–5.
  12. Dandona L, Williams JD, Williams BC, Rao GN. Population-based assessment of childhood blindness in southern India. *Arch Ophthalmol*. 1998;116:545–6.
  13. Rahi JS, Sripathi S, Gilbert CE, Foster A. Childhood blindness due to vitamin A deficiency in India: Regional variations. *Arch Dis Child*. 1995;72:330–33.
  14. Gogate P, Deshpande M, Sudrik S, Taras S, Kishore H, Gilbert C. Changing pattern of childhood blindness in Maharashtra, India. *Br J Ophthalmol*. 2007;91:8–12.
  15. Gogate P, Kishore H, Dole K, Shetty J, Gilbert C, Ranade S, et al. The pattern of childhood blindness in Karnataka, South India. *Ophthalmic Epidemiol*. 2009;16:212–7.
  16. Titiyal JS, Pal N, Murthy GV, Gupta SK, Tandon R, Vajpayee RB, et al. Causes and temporal trends of blindness and severe visual impairment in children in schools for the blind in North India. *Br J Ophthalmol*.2003;87:941–5.
  17. Hornby SJ, Adolph S, Gothwal VK, Gilbert CE, Dandona L, Foster A. Evaluation of children in six blind schools of Andhra Pradesh. *Indian J Ophthalmol*.2000;48:195–200.
  18. Gilbert CE, Canovas R, Hagan M, Rao S, Foster A. Causes of childhood blindness: Results from West Africa, south India and Chile. *Eye (Lond)* 1993;7:184–8.
  19. Rahi JS, Sripathi S, and Gilbert CE, Foster A. Childhood blindness in India: Causes in 1318 blind school students in nine states. *Eye (Lond)* 1995;9:545–50.
  20. Julia Dutra Rossetto, Kara M Cavuoto, Carla J Osigian, Ta Chen Chang, Darlene Miller, Hilda Capo, Oriol Spierer. Paediatric infectious keratitis: a case series of 107 children presenting to a tertiary referral centre. *Br J Ophthalmol*.2017, March (epub ahead of print).
  21. Kunimoto DY, Sharma S, Reddy MK, Gopinathan U, Jyotji J, Miller D, Rao GN. Microbial keratitis in children. *Ophthalmology* Feb;105(2):252-7.
  22. Nouredin GS, Sasaki S, Butler AL, Tilley P, Roscoe D Lyons CJ, Holland SP, Yeung SN. Paediatric Infectious keratitis at tertiary referral centres in Vancouver, Canada. *Br J Ophthalmol* 2016 Dec;100(12):1714-18.
  23. Young AL, Leung KS, Tsim N, Hui M, Jhanji V. Risk factors, microbiological profile and treatment outcomes of pediatric microbial keratitis in a tertiary care hospital in Hong Kong. *Am J Ophthal* 2013 Nov;156(5):1040-44.
  24. Singh G, Palaniswamy M, Madhavan B, Rajaram R, Narendran K, Kaur A, Venkatapathy N. Multivariate analysis of childhood microbial keratitis in south India. *Ann Acad Med Singapore* 2006 March;35(3):185-9.
  25. Chirinos Saldana P, Bautistade Lucio VM, Herandez JC. Clinical and microbiological profile of infectious keratitis in children. *BMC Ophthalmol* 2013.Oct16;13:54.