

A curious case of Purtscher's-like retinopathy

Ankit G. Rathod

Ex-PG Resident, Dept. of Ophthalmology, Lokmanya Tilak Municipal Medical College & General Hospital, Mumbai, Maharashtra, India

*Corresponding Author:

Email: anks266@gmail.com

Abstract

Purtscher's retinopathy is a retinal manifestation of head, chest and lower limb compressive injuries. Purtscher's-like retinopathy includes cases that mimic Purtscher's retinopathy but are not associated with trauma. The reported case is that of a 15yr-old male admitted to the general male medical ward after an episode of fever, cough, cold, abdominal pain and weight loss since 10 days. The treating physician considered an infective etiology as the primary differential and empirical treatment was started upon admission as for a case of acute febrile illness. However an ophthalmic consult was sought for in view of the visual loss. On ophthalmic examination the retina in both eyes showed white retinal patches distributed around the disc with superficial hemorrhages together with vascular sheathing and papillitis.

Keywords: Hemorrhage, Retinopathy, Retinal white patch, Systemic lupus erythematosus, Visual loss.

Introduction

The term Purtscher's retinopathy and Purtscher's-like retinopathy are distinct retinal entities used synonymously with retinal leukoembolization-a term that describes the pathogenesis behind the disease. The first case of Purtscher's retinopathy was reported by Dr Othmar Purtscher, in 1912 as a syndrome of sudden vision loss coupled with a typical retinal picture of peripapillary white retinal patches, superficial hemorrhages and papillitis in 5 patients of head trauma.¹ Purtscher's retinopathy is a retinal manifestation of head, chest and lower limb compressive injuries. Purtscher's-like retinopathy includes cases that mimic Purtscher's retinopathy but are not associated with trauma. These include patients with acute pancreatitis,² collagen vascular diseases,^{3,4} hemodialysis,⁵ chronic renal failure,⁶ hemolytic uremic syndrome,⁷ during plasmapheresis for Thrombotic thrombocytopenic purpura (TTP) or TTP per se,⁸ Still's disease,⁸ in normotensive obstetric patients after a precipitous delivery induced by intravenous oxytocin (Pitocin),⁹ following delivery by Caesarian-section,⁹ amniotic fluid¹⁰ and fat embolism,¹¹ HELLP syndrome,¹² cardiac aneurysm,¹³ ophthalmic artery occlusion¹⁴, hypereosinophilia syndrome,¹⁵ post bone marrow transplantation¹⁶, cytotoxic drug therapy,¹⁷ retro bulbar¹⁸ and peribulbar anesthesia.¹⁹

Case Report

The reported case is that of a 15 year-old male who presented to the male general medical ward with sudden diminution of vision since 7 days post fever, cough, cold, abdominal pain and weight loss. He was fully conscious but complained of slight neck stiffness. There was no history of long bone fracture, bone marrow transplantation, no signs and symptoms of any connective tissue disorder or acute pancreatitis. Observing the current clinical appearance the physician made a primary differential diagnosis of acute febrile illness (AFI) keeping in mind the possibility of pulmonary tuberculosis with probable hematogenous spread to the abdomen and eye. Simultaneously a chest X ray, CBC, Mantoux, VDRL, RBS, HBsAg and HIV were ordered and patient started on intravenous piperacillin-tazobactam combination, intravenous paracetamol, intravenous pantoprazole 40mg and necessary intravenous fluids. In view of the visual loss an ophthalmic reference was requested for. The Ophthalmic findings are summed up in the Table 1. An Optical Coherence Tomography of both eyes revealed inner retinal layer edema and hyper reflectivity of nerve fibre layer corresponding to the areas of retinal whitening (Fig 2).

Table 1: Ophthalmic findings of both the eyes

Eye	OD(Oculus Dexter)	OS (Oculus Sinister)
1) Visual Acuity	FCCF	FCCF
1) LIDS	Normal	Normal
2) Conjunctiva	Normal	Normal
3) Cornea	Clear	Clear
4) Anterior Chamber	Normal depth quiet	Normal depth quiet
5) Iris Color, Pattern	Normal color pattern	Normal color pattern
6) Pupil	Sluggishly reacting to light	Sluggishly reacting to light

7) Fundus Examination	White retinal patches and superficial hemorrhages in a peripapillary fashion together with vascular sheathing and papillitis (Fig 1a)	White retinal patches and superficial hemorrhages in a peripapillary fashion together with vascular sheathing and papillitis (Fig 1b)
-----------------------	---	---

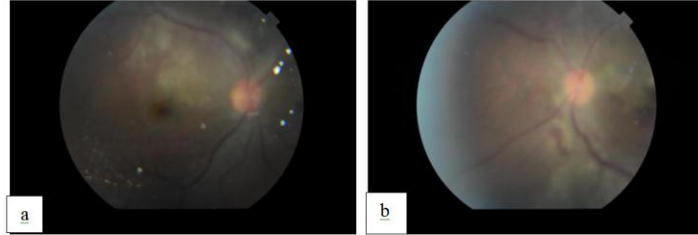


Fig 1: Fundus photograph showing peripapillary patches of retinal whitening with superficial hemorrhages at initial presentation Fig 1a: Oculus Dexter Fig 1b: Oculus Sinister

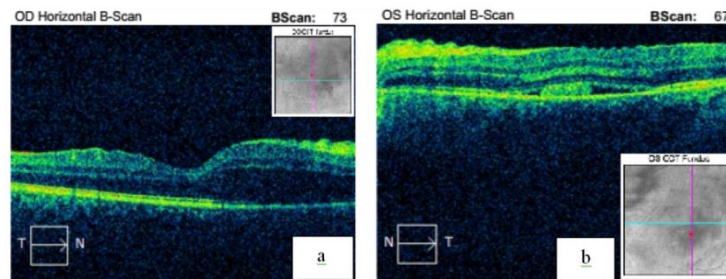


Fig 2: Optical Coherence Tomography shows inner retinal layer edema with hyperelectivity of the nerve fibre layer corresponding to the areas of retinal whitening at initial presentation Fig 2a: OD; Fig 2b: OS

Strangely the previously ordered chest X ray and Mantoux were negative for a tubercular focus as the etiology as previously considered. The PSMP and Routine blood investigations that were also initially ordered provided no significant information which ruled out hemolytic uremic syndrome and thrombotic thrombocytopenic purpura as the etiological causes. Also the available clinical features clubbed with the available blood investigations were not pointing towards a particular connective tissue disorder as the etiology either. Considering the ophthalmic findings of retinal vascular sheathing a search for a systemic vasculitic disorder was considered. After a Rheumatologic consultation at our institute an Abdominal + Pelvic USG was ordered concurrently with specific blood investigations to rule out a vasculitic cause. Blood investigations for Anti-DNA, ANA and Anti-Smith antibodies were found to be positive. The Abdominal+ Pelvic USG showed evidence of panserositis with a normal pancreas ruling out pancreatitis as the probable cause of the patients plight. The diagnosis now pointed towards a Connective Tissue Disorder most likely SLE in view of the panserositis, positive ANA, positive ds DNA and Anti-Smith antibodies but still the necessary criteria laid down by the American College of Rheumatology for the definite diagnosis of SLE was lacking. However as tuberculosis and infective causes were ruled out the physician decided to start the patient on 3 pulsed doses

of intravenous methyl-prednisolone 1 gram/day for 3 days after consulting the ophthalmic and rheumatologic departments, with an aim to treat the systemic as well as the ocular condition of the patient. The patient responded with an improvement in the visual acuity to FC 4M in the right eye and FC 3M in the Left eye together with improvement in malaise and resolution of the fever after the third IVMP pulse. Still the patient was receiving treatment on an empirical basis without being diagnosed with a definite disorder and a week had elapsed at the hospital. The patient was kept admitted in the ward under close observation for 2 more days but on the third day developed a rash over the upper chest and a typical butterfly rash over the malar area. A dermatological opinion described the rash as a maculopapular rash and together with malar rash provided missing pieces of this SLE jigsaw puzzle. 2 more cycles of IVMP were given and was started on a maintenance dose of oral prednisolone which resulted in resolution of the rash and further systemic improvement, however the vision did not improve further. The patient was later discharged and asked to follow-up as advised by the physician.

Discussion

Purtscher retinopathy was first reported by Dr Othmar Purtscher an Austrian Ophthalmologist as a traumatic retinal angiopathy in the year 1912 with the distinct retinal picture characterized by multiple patches

of retinal whitening and superficial haemorrhages surrounding the optic disc and papillitis in patients with head trauma.¹ Purtscher like retinopathy is a term given to describe a similar fundoscopic abnormalities with non traumatic etiology. Various etiological factors associated with Purtscher like retinopathy are acute pancreatitis,² collagen vascular diseases,³⁻⁴ hemodialysis,⁵ chronic renal failure,⁵ hemolytic uremic syndrome,⁷ during plasmapheresis for TTP or TTP per se,⁸ Still's disease,⁸ in normotensive obstetric patients after a precipitous delivery induced by intravenous oxytocin (Pitocin),⁹ following delivery by C-section,⁹ amniotic fluid¹⁰ and fat embolism,¹¹ HELLP syndrome,¹² cardiac aneurysm,¹³ ophthalmic artery occlusion,¹⁴ hypereosinophilia syndrome,¹⁵ post bone marrow transplantation,¹⁶ cytotoxic drug therapy,¹⁷ retro bulbar¹⁸ and peribulbar anesthesia.¹⁹

The pathogenesis of Purtscher's and Purtscher-like retinopathy involves intravascular aggregation of leukocytes in response to unusual activation of complement C5a as the possible cause of retinal arterial embolization that produce this distinct fundoscopic picture.

As far as the treatment of Purtscher & Purtscher-like retinopathy is concerned no definite guidelines exist. Apart from the treatment of the underlying systemic disease isolated case reports of treatment with high dose intravenous steroids have shown favourable results.²⁰ In this case report IVMPs was administered in a dose of 1 gram in 3 divided doses per day for a total of 5 days with blood pressure monitoring. We noted a modest improvement in the visual acuity after the first 3 doses but subsequently there was no improvement in vision after the 4th and 5th dose of IVMPs.

SLE is a systemic autoimmune disorder with unknown etiology and complex pathogenesis. Median age of onset in india is 24.5 years with F:M ratio of 11:1. A prevalence study in India (carried on a rural population near Delhi) showed a point prevalence of 3 per 100,000²¹ a figure much lower than the west. Copcord Bhigwan study (prospective population study from Pune) found a crude incidence rate of 1 per 25000 person years i.e. 4 per 100,000 population years. SLE was diagnosed in our case by criteria laid down by the ACR 1997 update as given below.

Table 2: 1997 Update of the 1982 American College of Rheumatology revised criteria for classification of systemic lupus erythematosus (At least 4 of the 11 criteria are required to make a definite diagnosis of SLE).⁶

Criterion	Definition
1. Malar rash	Fixed erythema, flat or raised, over the malar eminences, tending to spare the nasolabial folds
2. Discoid rash	Erythematous raised patches with adherent keratotic scaling and follicular plugging; atrophic scarring may occur in older lesions
3. Photosensitivity	Skin rash as a result of unusual reaction to sunlight by patient history or physician observation
4. Oral ulcers	Oral or nasopharyngeal ulceration, usually painless, observed by physician
5. Nonerosive arthritis	Involving two or more peripheral joints, characterized by tenderness, swelling, or effusion
6. Pleuritis or pericarditis	1. Pleuritis—convincing history of pleuritic pain or rubbing heard by a physician, or evidence of pleural effusion OR 2. Pericarditis—documented by electrocardiogram (ECG) or rub or evidence of pericardial effusion
7. Renal disorder	1. Persistent proteinuria >0.5 g/day, or >3+ if quantitation not performed OR 2. Cellular casts—may be red cell, hemoglobin, granular, tubular, or mixed
8. Neurologic disorder	1. Seizures—in the absence of offending drugs or known metabolic derangements (e.g., uremia, ketoacidosis, electrolyte imbalance) OR 2. Psychosis—in the absence of offending drugs or known metabolic derangements (e.g., uremia, ketoacidosis, electrolyte imbalance)
9. Hematologic disorder	1. Hemolytic anemia—with reticulocytosis OR 2. Leukopenia—<4000/mm ³ total on two or more occasions OR 3. Lymphopenia—<1500/mm ³ on two or more occasions OR 4. Thrombocytopenia—<100,000/mm ³ in the absence of offending drugs

10. Immunologic disorder	1. Anti-DNA—antibody to native DNA in abnormal titer <i>OR</i> 2. Anti-Sm—presence of antibody to Sm nuclear antigen <i>OR</i> 3. Positive finding of antiphospholipid antibodies on: 1. An abnormal serum level of IgG or IgM anticardiolipin antibodies 2. A positive test result for lupus anticoagulant using a standard method 3. A false-positive test result for at least 6 mo and confirmed by <i>Treponema pallidum</i> immobilization or fluorescent treponemal antibody absorption test Standard methods should be used in testing for the presence of antiphospholipids.
11. Positive antinuclear antibody (ANA)	An abnormal titer of antinuclear antibody by immunofluorescence or an equivalent assay at any point in time and in the absence of drugs known to be associated with drug-induced lupus syndrome

We report this case for several reasons. First, a rare presentation of a rare disease (SLE is rare in India) uncommon in males. A previous case report shows that a rare and severe ophthalmic complication of SLE, Purtscher-like retinopathy was associated with highly active disease and that visual acuity recovery was usually poor despite prompt treatment,²² however in our case report and in the case reported by Atabay et al²⁰ high dose steroids in the form of intravenous IVMPs was found to improve the vision modestly and we suggest should be tried in all such patients. Secondly the late presentation of signs of SLE perplexed the physicians and the ophthalmologists as to the etiology of the condition which made the initial diagnosis difficult and treatment empirical. Thirdly it highlights the importance of an ophthalmologist in the early diagnosis of a systemic life and sight threatening vascular disorder.

References

- Purtscher O. Unknown findings after head trauma. *Ber Dtsch Ophthalmol Ges.* 1910;36:294–301.
- Nema, Nitin et al. "Purtscher-like Retinopathy in Acute Alcoholic Pancreatitis." *Oman Journal of Ophthalmology* 9.2 (2016):110–112.
- Farmer SG, Kinyoun JL, Nelson JL, Wener MH. Retinal vasculitis associated with autoantibodies to Sjögren's syndrome A antigen. *Am J Ophthalmol.* 1985 Dec 15;100(6):814–821.
- Sellami D, Ben Zina Z, Jelliti B, Abid D, Feki, Chaabouni M. Purtscher-like retinopathy in systemic lupus erythematosus. Two cases]. *J Fr Ophthalmol* 2002;25(1):52–55.
- Stoumbos, Vasiliki D. et al. Purtscher's-like Retinopathy in Chronic Renal Failure *Ophthalmology*, Volume 99, Issue 12, 1833– 1839.
- Yu C, Gershwin ME, Chang C. Diagnostic criteria for systemic lupus erythematosus: A critical review. *Journal of Autoimmunity* 2014;1-4.
- Lauer AK, Klein ML, Kovarik WD, Palmer EA. Hemolytic Uremic Syndrome Associated with Purtscher-like retinopathy. *Arch Ophthalmol.* 1998;116(8):1119–1120.
- Okwuosa, T. M., Lee, E. W., Starosta, M., Chohan, S., Volkov, S., Flicker, M., Curran, J., Rezaei, K. A. and Sweiss, N. J. (2007), Purtscher-like retinopathy in a patient with Adult-onset Still's disease and concurrent thrombotic thrombocytopenic purpura. *Arthritis & Rheumatism*, 57:182–185.
- Blodi BA, Johnson MW, Gass JD, et al: Purtscher's-like retinopathy after childbirth. *Ophthalmology* 97:1654-9,1990.
- Chang M, Herbert WNP. Retinal arteriolar occlusions following amniotic fluid embolism. *Ophthalmology* 1984;91:1634-7.
- Roden D, Fitzprick G, O' Donoghue H, Phelan D. Purtscher's Retinopathy and fat embolism. *Br J Ophthalmol.* 1989;73:677-9.
- Stewart MW, Brazis PW, Guier CP, Thota SH, Wilson SD. Purtscher-like retinopathy in a patient with the HELLP syndrome. *Am J Ophthalmol* 2007;143(5):886-887.
- Kozlowski J, Peters AL. Purtscher's-like Retinopathy Associated with a Cardiac Aneurysm. *Arch Ophthalmol.* 1992;110(6):880–881.
- Kurimoto T, Okamoto N, Oku H, et al. Central retinal artery occlusion resembling Purtscher-like retinopathy. *Clinical Ophthalmology (Auckland, NZ).* 2011;5:1083-1088.
- Coban-Karatas M, Turunc T, Yaycioglu RA. Purtscher-like Retinopathy Related to Drug-induced Hypersensitivity Syndrome; *Ocular Immunology and Inflammation* Vol. 20, Iss. 6, 2012.
- Parc C., Purtscher-like retinopathy as an initial presentation of a thrombotic microangiopathy associated with antineoplastic therapy. *Am. J. Hematol.* 2007, 82:486–488.
- Sheyman, Alan T. MD; Wald, Kenneth J. MD; Pahk, Patricia J. MD; Freund, K. Bailey MD. Gemcitabine associated retinopathy and nephropathy *Retinal Cases and Brief Reports: April 2014-Volume 8-Issue 2 – p.107–109.*
- J. Lemagne M, Michiels X, Causenbroeck SV, Snyers B. Purtscher-like retinopathy after retrobulbar anesthesia. *Ophthalmology.* 1990 Jul;97(7):859–861.
- Narendran, Siddharth, Saravanan VR, and Pereira M. "Purtscher-like Retinopathy: A Rare Complication of Peribulbar Anesthesia." *Indian Journal of Ophthalmology* 64.6 (2016):464–466.
- Atabay C, Kansu T, Nurlu G: Late visual recovery after intravenous methylprednisolone treatment of Purtscher's retinopathy. *Ann Ophthalmol* 25:330-3,1993.
- Malaviya AN, Singh RR, Singh YN, Kapoor SK, Kumar A. Prevalence of systemic lupus erythematosus in India. *Lupus.* 1993 Apr; 2(2):115-8.
- Wu C, Dai R, Dong F, Wang Q. Purtscher-like Retinopathy in Systemic Lupus Erythematosus. *American J of Ophthalmol.* 2014 ;158:1335-41.