

# A Study on the Visual Outcomes and Complications of Cataract Surgery in the Rural Population of Indian Patients with Pseudo exfoliation

Chevuturu Madhavi<sup>1,\*</sup>, YJ Santhi Latha<sup>2</sup>, Divya Pyaraka<sup>3</sup>, M. Ashok Kumar<sup>4</sup>

Dept. of Ophthalmology, Medciti Institute of Medical Sciences, Ghanpur, Medchal, Hyderabad, Telangana- 501401

**\*Corresponding Author:**

Email: drmadhavi28@gmail.com

## ABSTRACT

**Aim:** To analyze the visual outcomes and the intra and postoperative complications of manual small incision cataract surgery (MSICS) in patients with Pseudo exfoliation (PXF).

**Materials and Methods:** The study included 76 eyes of 76 patients of the rural population in India with cataract and PXF who underwent MSICS surgery. The effect of the parameters like the dilatation of pupil during surgery, nuclear grading at baseline was studied with respect to the final visual outcomes and intra operative and postoperative complications of cataract surgery. The best corrected visual acuity (BCVA) at 4 weeks and 6 weeks after surgery were reported.

**Results:** The mean age of the patients was 64.9 years and there were 44 males and 32 females. The BCVA ranging from 6/6 to 6/9 was seen in 44 (58.1%) eyes at 4 weeks and 46 (60.6%) eyes at 6 weeks. The visual outcomes were lower in patients with higher nuclear sclerosis (NS) of grade IV-V, poor pupil size ( $\leq 6$  mm) compared to patients with NS I-III and good pupil size ( $> 6$  mm). Iris prolapsed 8 (10.9%) and posterior capsular rent 7 (9.2%) intra operatively and corneal edema 34 (44.7%) postoperatively that subsided within 1-2 days were the most commonly reported complications.

**Conclusion:** MSICS technique in cataract patients with PXF is cost effective and is associated with good visual outcomes. Early diagnosis, proper preoperative and postoperative planning, knowledge and surgical skills of handling the possible complications can increase the success rate of cataract surgery in patients with PXF.

**Keywords:** Best corrected visual acuity (BCVA), Nuclear grading, Pupil size, Pseudo exfoliation

Access this article online	
Quick Response Code:	Website: www.innovativepublication.com
	DOI: 10.5958/2395-1451.2015.00009.8

## INTRODUCTION

Cataract is clouding of the lens in the eye that commonly occurs due to increasing age and is removed by a surgery. Manual small incision cataract surgery (MSICS) involves removing the cataract us lens from the eye through a small incision by various methods of nucleus delivery. As per the World Health Organization (WHO) estimates there are 37 million people worldwide who were blind in 2002<sup>1,2</sup> and the age-related cataract is the leading cause of blindness globally<sup>3</sup>. Pseudo exfoliation (PXF) is a pathologic accumulation of abnormal fibrillar deposits on various ocular structures and extraocular tissues and is an age-related disorder that may affect up to 20% of people over the age of 60. The specific synthesis and pathogenesis of PXF are still unknown. Deposition of exfoliative material results in predictable alterations of tissues in the anterior segment making cataract operation potentially challenging in PXF patients<sup>4</sup>. The problems are mainly initiated by zonular instability and insufficient pupillary dilatation<sup>5</sup>. Other factors associated with

zonular instability are age, shallow anterior chamber depth, cataract density, pupil size, IOP / glaucoma status, atrophy of pupillary ruff and pigment in the angle. Interestingly, the degree of PXF material visible in the eye does not seem to correlate with the degree of zonular weakness<sup>4</sup>. Zonular instability was reported to possess a significantly higher risk for intraoperative complications<sup>6</sup>. Phacodonesis is a result of zonular instability. In this study we assessed the distribution of pseudo exfoliation in relation to nuclear grading of cataract, pupil size, phacodonesis, in terms of final visual outcomes of MSICS and assessment of intraoperative and early postoperative complications.

## MATERIALS AND METHODS

This prospective, non-randomized, case series study was conducted in patients attending an out-patient Ophthalmology department of a rural medical college and hospital (Medciti Institute of Medical Sciences, Ghanpur) from December 2012 to May 2014. The sample size includes 76 eyes of 76 patients of either sex, aged above 50 years and diagnosed to have cataract with pseudo exfoliation on the basis of slit lamp examination before and after pupillary dilatation. The exclusion criteria included patients below 50 years of age, patients with raised intraocular pressure (IOP), with traumatic cataract, patients with lens dislocation or subluxation without pseudo exfoliation and patients diagnosed with uveitis. Also excluded were patients with

uncontrolled diabetes, hypertension and or other severe systemic disorders like cardiovascular diseases. Institutional ethics committee clearance was obtained before the start of the study. Written informed consent was obtained from all patients included in the study after explaining the procedure and the associated risk. The demographic parameters, the complete ophthalmic history and relevant personal medical history as well as family history were collected for all patients. The ophthalmic history included diminution of vision, its onset, duration and progress, redness of eyes, pain, watering or any discharge from eyes, intolerance to light, ocular surgery etc. The medical history included trauma, steroid exposure or drug intake, diabetes mellitus, asthma, hypertension, tuberculosis, past history of any other surgery etc.

A comprehensive ocular examination was performed in patients prior to surgery. Best corrected visual acuity (BCVA) was measured using Snellen's visual acuity chart. IOP was measured by application tonometer. Gonioscopy was done and the angle was graded by Shaffer's system of grading. Detailed slit lamp examination was done before and after pupillary dilatation to grade the nucleus and to look for the pseudo exfoliative deposits on the cornea, iris, pupillary margin and on the anterior capsule of the lens. Intraoperative maximum pupillary dilatation was obtained and its diameter was measured with the help of calipers and graded as poor ( $\leq 6$  mm) and good ( $> 6$  mm). Intraocular lens (IOL) power calculation was done on the basis of keratometry reading and axial length assessment by A scan and applying the SRK II formula.

All patients were admitted one day prior to surgery and were started on systemic and topical antibiotic ciprofloxacin. Eyelashes of the eye to be operated were trimmed in the morning on the day of surgery. Preoperatively mydriasis was achieved with instillations of tropic amide (1%) and phenylephrine (10%) combination. Flurbiprofen eye drops were used to sustain the mydriasis achieved. MSICS with posterior chamber intraocular lens (PCIOL) implantation was performed in all the patients by the same surgeon with good years of experience. In cases of poor pupillary dilatation with difficulty in nucleus prolapse into anterior chamber, sphincterotomy was performed. After an adequate sized capsulorhexis careful hydro dissection was carried out with minimal stress on the zonules. In cases of posterior capsular rent, a good anterior vitrectomy was done and PCIOL was placed in the sulcus. In cases of capsular bag dialysis and a large posterior capsular rent, where PCIOL could not be implanted an anterior chamber intraocular lens (ACIOL) was placed. The patients were monitored for one to two days for any post-operative complications and were discharged if there were not any. Postoperatively systemic antibiotic was

given for 3 days and a topical antibiotic-steroid preparation was given for 6 weeks in tapering doses. The patients were asked to follow up after one week, 2 weeks, 4 weeks and 6 weeks. On each follow up, visual acuity testing and anterior segment examination was performed on slit lamp. Uncorrected visual acuity (UCVA) was measured after one and two weeks and BCVA was measured at 4 and 6 weeks. If patients were lost to follow up, the two weeks data was carried forward for 4 weeks and 6 weeks analysis.

## RESULTS

The age of the patients was in the range of 50- 85 years. Maximum patients were in the age group of 65 – 70 years. The total number of males in the study was 44 (58%) (Figure 1). The preoperative visual acuity was less than 6/60 in most of the patients (Figure 2). When the cataract grading was done 3 (4 %) patients had NS I, 16 (21%) had NS II, 13 (17%) had NS III, 43 (57%) had NS IV and 1 (1%) patient had NS V. Out of 76 patients, 27 (35.5 %) had poor pupillary dilatation ( $\leq 6$  mm).

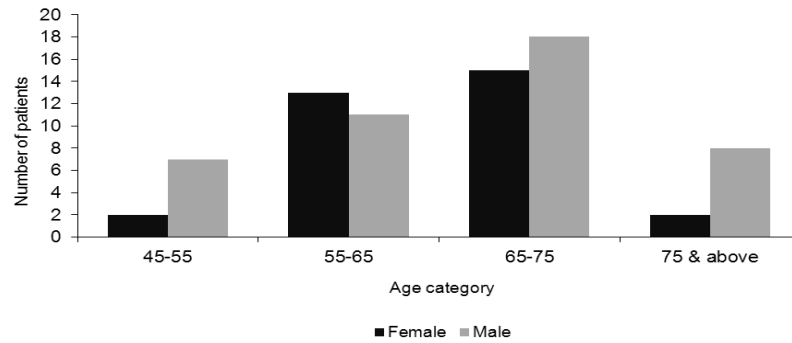
PCIOL was placed in 70 eyes. However IOL was placed in sulcus in 2 patients (because of posterior capsular rent) and in anterior chamber in 4 patients (1 patient had capsular bag dialysis with zonular dehiscence, 3 patients had a large posterior capsular rent with vitreous loss). The most common intraoperative complication observed in our study was iris prolapse and posterior capsular (PC) rent. PC rent with vitreous loss was seen in 4 (5.3%) patients and without vitreous loss was seen in 3 (3.9%) patients. Of the 76 patients, 34 (44.7%) patients had corneal edema on the first postoperative day either in the form of epithelial edema or striate keratopathy, which subsided within one to two days after treatment except in 2 (2.6%) patients where it took one week for the corneal edema to subside. No prolonged inflammation or IOL related complications were reported in any of the patients (Table 1).

Postoperatively after one week the UCVA in the range of 6/6 to 6/18 was seen in 36 (47.4 %) eyes (Table 1). At the end of 6 weeks, all the patients had BCVA  $\geq 6/24$  except for seven patients [lost to follow up (n=3), 6/36 (n=1), 6/60 (n=2), CF (n=1)] (Table 2). The incidence of postoperative complications was higher in patients with nuclear sclerosis grade IV-V compared with grade I-III (Figure 3). The incidence of both the intra and postoperative complications were higher in patients with poor pupil size ( $\leq 6$  mm). We did not see any effect on the incidence of postoperative complications with the presence or absence of phacodonesis. The incidence of intraoperative complications were slightly higher in patients with the presence of phacodonesis 3 (33.3%) compared to patients without any, 18 (26.9%) (Table 3).

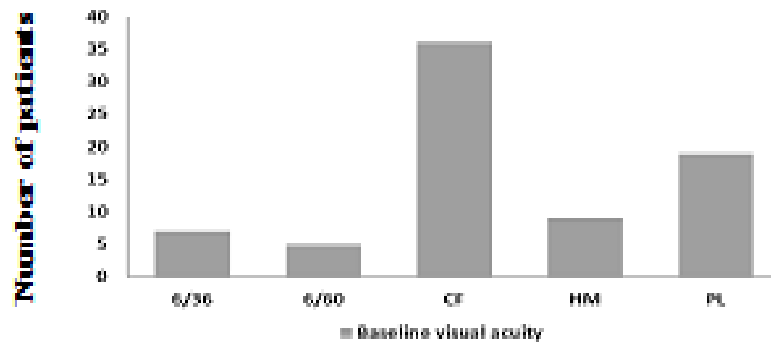
Good visual outcomes in the range of 6/6 - 6/12 were higher in the eyes of patients with less nuclear sclerosis of grade I-III (n=29, 90.6%) compared with the patients having NS IV-V (n=29, 65.9%). Similarly in patients with good pupil dilatation the visual acuity in the range of 6/6 - 6/12 was seen in 40 (81.6%) eyes compared to 19 (70.4%) eyes in patients with poor pupil dilatation. The least

visual acuity (counting fingers) or no improvement was seen in 1 (1.3%) eye of the patient with higher nuclear sclerosis of grade IV-V at baseline and with poor pupillary dilatation. This patient was found to have age related macular degeneration on postoperative fundus examination. Three patients lost to follow up for the reasons unknown (Table 4).

**Fig. 1: Age and Sex Distribution**

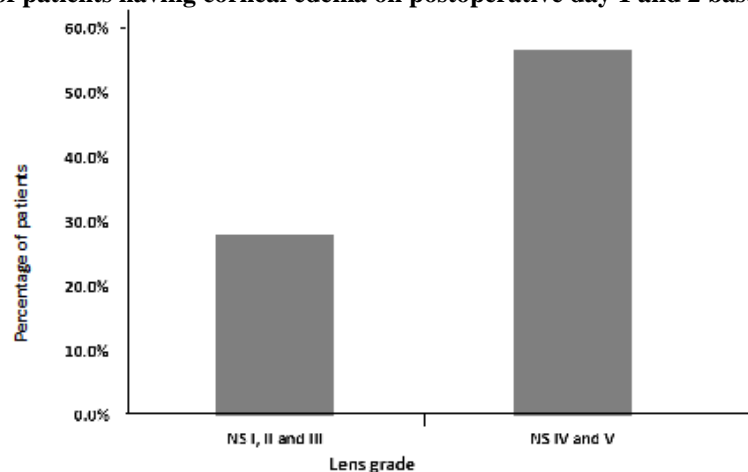


**Fig. 2: Baseline visual acuity**



CF: Counting fingers; HM: hand movements; PL: perception of light

**Fig. 3: Percentage of patients having corneal edema on postoperative day 1 and 2 based on nuclear sclerosis**



**Table 1: Intra operative and postoperative complications of cataract surgery in patients with pseudo exfoliation**

Complications	N=76 No. of cases, n (%)
<b>Intra operative Complications</b>	
Iris prolapse	8 (10.5)
Posterior capsule rent with vitreous loss	4 (5.3)
Posterior capsule rent without vitreous loss	3 (3.9)
Difficulty during nucleus delivery	3 (3.9)
Zonular dialysis	1 (1.3)
Iridodialysis	1 (1.3)
<b>Postoperative Complications</b>	
Corneal edema	34 (44.7)
Pigment dispersion on intraocular lens	3 (3.9)
Updrawn pupil	3 (3.9)
Optic capture	1 (1.3)

**Table 2: Visual acuity scores at 1 week, 4 weeks and 6 weeks after cataract surgery in patients with pseudo exfoliation**

Visual acuity	Baseline visual acuity, n (%)	UCVA at 1 week, n (%)	BCVA at 4 weeks, n (%)	BCVA at 6 weeks, n (%)
6/6	0 (0.0)	0 (0.0)	8 (10.5)	9 (11.8)
6/9	0 (0.0)	4 (5.3)	36 (47.6)	37 (48.8)
6/12	0 (0.0)	12 (15.8)	12 (15.8)	13 (17.1)
6/18	0 (0.0)	20 (26.3)	10 (13.1)	8 (10.6)
6/24	0 (0.0)	18 (23.7)	3 (3.9)	2 (2.6)
6/36	7 (9.2)	12 (15.8)	1 (1.3)	1 (1.3)
6/60	5 (6.5)	4 (5.3)	1 (1.3)	2 (2.6)
CF	36 (47.5)	6 (7.8)	2 (2.6)	1 (1.3)
HM/PL	28 (36.8)	0 (0.0)	0 (0.0)	0 (0.0)
Lost to follow-up	0 (0.0)	0 (0.0)	3 (3.9)	3 (3.9)

UCVA: uncorrected visual acuity; BCVA: best corrected visual acuity

**Table 3: Effect of phacodonesis, pupil size and nuclear sclerosis on the incidence of intra and postoperative complications in cataract eyes with PXF**

Variable	(N=76), n (%)	Any intra operative complication, n (%)	Any postoperative complication, n (%)
<b>Phacodonesis</b>			
Yes	9 (11.8)	3 (33.3)	4 (44.4)
No	67 (88.2)	18 (26.9)	31 (46.3)
<b>Pupil size</b>			
Good (>6 mm)	49 (64.5)	9 (18.4)	15 (30.6)
Poor (≤6 mm)	27 (35.5)	12 (44.4)	20 (74.1)
<b>Nuclear sclerosis grading</b>			
I-III	32 (42.1)	8 (25.0)	9 (28.1)
IV-V	44 (57.9)	13 (29.5)	26 (59.1)

Intra operative and postoperative percentages are calculated based on total number of patients in that particular group.

**Table 4: Change in visual acuity scores at 1 week, 4 weeks and 6 weeks based on nuclear sclerosis and pupil size**

	UCVA at 1 week	BCVA at 4 weeks	BCVA at 6 weeks
<b>Nuclear sclerosis grading</b>			
<b>I-III (n=32)</b>			
6/6 – 6/12	12 (37.5%)	29 (90.6%)	29 (90.6%)
6/18–6/24	8 (25.0%)	2 (6.3%)	2 (6.3%)
6/36	9 (28.1%)	1 (3.1%)	1 (3.1%)
6/60	3 (9.4%)	0 (0.0%)	0 (0.0%)
CF	0 (0.0%)	0 (0.0%)	0 (0.0%)
<b>IV-V (n=44)</b>			
6/6 – 6/12	11 (25.0%)	27 (61.4%)	29 (65.8%)
6/18–6/24	17 (38.6%)	9 (20.5%)	8 (18.3%)
6/36	6 (13.6%)	1 (2.3%)	1 (2.3%)
6/60	4 (9.1%)	1 (2.3%)	2 (4.5%)
CF	6 (13.6%)	3 (6.8%)	3 (6.8%)
Lost to Follow-up	0 (0.0%)	3 (6.8%)	1 (2.3%)
<b>Pupillary dilatation</b>			
<b>Good (&gt;6 mm) (n=49)</b>			
6/6 – 6/12	11 (22.4%)	37 (75.5%)	40 (81.6%)
6/18–6/24	26 (53.1%)	8 (16.5%)	5 (10.2%)
6/36	5 (10.2%)	1 (2.0%)	1 (2.0%)
6/60	3 (6.1%)	1 (2.0%)	2 (4.2%)
CF	4 (8.2%)	1 (2.0%)	0 (0.0%)
Lost to Follow-up	0 (0.0%)	1 (2.0%)	1 (2.0%)
<b>Poor (≤6 mm) (n=27)</b>			
6/6 – 6/12	5 (18.5%)	19 (70.4%)	19 (70.4%)
6/18–6/24	12 (44.4%)	5 (18.5%)	5 (18.5%)
6/36	7 (26.0%)	0 (0.0%)	0 (0.0%)
6/60	1 (3.7%)	0 (0.0%)	0 (0.0%)
CF	2 (7.4%)	1 (3.7%)	1 (3.7%)
Lost to Follow-up	0 (0.0%)	2 (4.2%)	2 (4.2%)

UCVA: Uncorrected visual acuity, BCVA: Best corrected visual acuity. The percentages were calculated based on the total number of patients in that particular group.

## DISCUSSION

Pseudo exfoliation is a relatively common condition that coexists in elderly patients with age related cataracts. The prevalence of PXF varies from race to race and 6% prevalence with male preponderance was reported in the rural population of south India<sup>7</sup>. In our study the prevalence was comparable between both genders with slightly higher prevalence in males (58%). In PXF patients the small pupillary diameter and zonular instability are presumed to be the most important risk factors for capsular rupture and vitreous loss during cataract surgery<sup>8-11</sup>. Vitreous loss was shown to be five times more common in PXF compared to patients without this disorder<sup>11,12</sup>. It was reported that there is a ten times increase in the risk of lens subluxation, zonular dialysis or vitreous loss with zonular instability<sup>11,13</sup>. In our study poor pupil dilatation was seen in 35.5%

of patients which was consistent with that reported in similar type of study<sup>14,15</sup>. Some studies reported a higher incidence of poor pupillary dilatation to be 48.4% and 94.1%<sup>15,16</sup>. In our study sphincterotomy was done in patients with non-dilating pupil with difficulty in nucleus prolapse. The use of intraoperative highly cohesive viscoelastics, pupil expansion devices and capsule tension rings might also increase the margin of safety. Iris prolapse and posterior capsular rent were the commonly reported intraoperative complications. Corneal edema that subsided within one to two days after surgery was the most frequently reported postoperative complication, the incidence of which is high with higher grades of nuclear sclerosis and inadequate pupil dilatation. In our study the number of patients with phacodonesis was very less 9 (11.8%) and hence we could not see any major effect on the incidence of complications

with the presence of phacodonesis. Our study results also show that operating cataract eyes with PXF at early stages of nuclear sclerosis will reduce the intraoperative and postoperative complications and provide good visual outcomes. Unimproved visual acuity was seen in 1 (1.3%) patient who had higher nuclear sclerosis grading of IV-V at baseline and poor pupillary dilation. This patient also had coexisting age related macular degeneration. Most of the patients in our study achieved good visual acuity by the end of 4 weeks.

In our study we observed that the preoperative use of non-steroidal anti-inflammatory drugs maintained good pupillary dilatation. Depending on the grading of the nucleus an adequate or slightly large size capsulorrhexis with relaxing cuts minimized the stress on the zonules and the capsular bag. Meticulous hydro dissection achieved gentle decompression of capsular bag and minimized the stress on the zonules. Further the tissue handling during nucleus delivery was minimized by selecting the appropriate nucleus delivery method on an individual basis.

Treating cataract blindness worldwide continues to be a formidable challenge. It is important to increase the awareness of PXF condition in the detection and preoperative determination of patients inclined to be at greater risk for complications during cataract surgery. Significant barriers include cost, lack of population awareness, shortage of trained personnel and poor surgical outcomes. The MSICS is faster, less expensive and less technology dependent and provides excellent visual outcomes with lower complication rates and might be the preferred technique for cataract surgery in the developing world where high volume surgery is a priority<sup>3,7,18</sup>. Early diagnosis, detailed examination, anticipation of the possible complications during surgery, knowledge and surgical skills to manage such complications and meticulous postoperative follow up in cataracts with PXF can increase the success rate of the surgical outcome.

## CONCLUSIONS

Pseudo exfoliation is a risk factor in cataract surgery because of the increased weakness of zonular apparatus and reduced pupillary dilatation (5). Good visual acuity was observed in our study with MSICS technique in patients with PXF though it required an optimized surgery. Intra operatively iris prolapse and posterior capsule rent and post operatively corneal edema was the most commonly reported complications. Early detection and conduction of cataract surgery in the PXF patients with less nuclear sclerosis and use of highly cohesive viscoelastics, pupil expansion devices and capsule tension rings can increase the margin of safety and bring out good

visual outcomes. Proper preoperative evaluation and postoperative follow up and the knowledge and surgical skills of handling the possible complications might help in minimizing the risk and providing a very favorable outcome in cataract surgery even in patients with PXF.

## LIMITATIONS

The study is limited as the control was not available for comparison. The follow up period was only 6 weeks and late post-operative complications such as posterior capsular opacification and IOL related complications were not evaluated.

## REFERENCES

1. Pascolini D, Mariotti SP, Pokharel GP, Pararajasegaram R, Etya'ale D, Négrel AD, Resnik off S. 2002 global update of available data on visual impairment: a compilation of population-based prevalence studies. *Ophthalmic Epidemiol.* 2004;11(2):67-115.
2. Resnikoff S, Pascolini D, Etya'ale D, Kocur I, Pararajasegaram R, Pokharel GP, Mariotti SP. Global data on visual impairment in the year 2002. *Bull World Health Organ.* 2004;82(11):844-513.
3. Riaz Y, de Silva SR, Evans JR. Manual small incision cataract surgery (MSICS) with posterior chamber intraocular lens versus phacoemulsification with posterior chamber intraocular lens for age-related cataract. *Cochrane Database Syst Rev.* 2013;10:CD008813.
4. Jawad M, Nadeem AU, Khan Au, Aftab M. Complications of cataract surgery in patients with pseudo exfoliation syndrome. *J Ayub Med Coll Abbottabad.* 2009;21(2):33-6.
5. Drolsum L, Ringvold A, Nicolaisen B. Cataract and glaucoma surgery in pseudo exfoliation syndrome: a review. *Acta Ophthalmol Scand.* 2007;85(8):810-21.
6. Kühle M, Viestenz A, Martus P, Händel A, Jünemann A, Naumann GO. Anterior chamber depth and complications during cataract surgery in eyes with pseudo exfoliation syndrome. *Am J Ophthalmol.* 2000;129(3):281-5
7. Krishnadas R, Nirmalan PK, Ramakrishnan R, Thulasiraj RD, Katz J, Tielsch JM, Friedman DS, Robin AL. Pseudoexfoliation in a rural population of southern India: the Aravind Comprehensive Eye Survey. *Am J Ophthalmol.* 2003 Jun;135(6):830-7.
8. Busić M, Kastelan S. Pseudo exfoliation syndrome and cataract surgery by phacoemulsification. *Coll Antropol.* 2005;29(S1):163-6.
9. Kaštelan S, Bušić M. Pseudo exfoliation syndrome and cataract surgery. *Ophthalmologia Croatica* 2003; 11: 37-40.
10. Tyagi AK MP. Pseudo exfoliation syndrome and spontaneous lens dislocation. *Eye (Lond).*1998;12:1033-1034.
11. Snježana Kaštelan MT, Rajko Kordić, Miro Kalauz and Jasminka Salopek-Rabatić. Cataract Surgery in Eyes with Pseudo exfoliation (PEX) Syndrome. *J Clinic Experiment Ophthalmol.*2013;S1:009.
12. Naumann GO. Exfoliation syndrome as a risk factor for vitreous loss in extra capsular cataract surgery (preliminary report). Erlanger-Augenblätter-Group. *Acta Ophthalmol.*1988;Suppl 184:129-131.
13. Zetterstrom C, Olivestedt G, Lundvall A. Exfoliation syndrome and extra capsular cataract extraction with implantation of posterior chamber lens. *Acta Ophthalmologica.* 1992;70:85-90.

14. Garima Rai, P Shinga, Vinita Gupta, Zarrin. S. A Comparative Study of Outcome of Small Incision Cataract Surgery in Eyes with and without Pseudo exfoliation Syndrome. *Int J Sci Study*.2014;2:78-81.
15. Carpel EF. Pupillary dilation in eyes with pseudo exfoliation syndrome. *Am J Ophthalmo*. 1988;105:692-694.
16. Alfaiate M, Leite E, Mira J, Cunha-Vaz JG. Prevalence and surgical complications of pseudo exfoliation syndrome in Portuguese patients with senile cataract. *J Cataract Refract Surg*. 1996;22:972-976.
17. Venkatesh R, Tan CS, Sengupta S, Ravindran RD, Krishnan KT, Chang DF. Phacoemulsification versus manual small-incision cataract surgery for white cataract. *J Cataract Refract Surg*..2010;36:1849-1854.
18. Tabin G, Chen M, Espandar L. Cataract surgery for the developing world. *Curr Opin Ophthalmol*.2008;19:55-59.