

Partial anodontia in permanent dentition: A case report

Shilpa P. H.^{1,*}, Abhishek Jairaj², Deepthi N. G.³, Prashant Pareek⁴, Kritika Sehrawat⁵

^{1,2}Senior Lecturer, AIMST University, Jalan Bedong-Semeling, Kedah, Malaysia, ³⁻⁵PG Student, ³Dept. of Pedodontics, Sibar Institute of Dental Sciences, Guntur, Andhra Pradesh, ^{4,5}Dept. of Oral and Maxillofacial Surgery, Sudha Rustagi Dental College & Research Centre, Faridabad, Haryana, India

***Corresponding Author:**

Email: shilpaph@gmail.com

Abstract

Anodontia is a genetic disorder characterized by absence of all primary or permanent teeth. It can occur in some teeth or all the teeth. Partial anodontia also called as anodontia involves two dentitions or only teeth of permanent dentition. partial anodontia, hypodontia, oligodontia, bilateral aplasia, congenital absence are the various terminologies used for the same. Congenital absence of at least one permanent tooth is the most common dental anomaly which affects esthetic, mastication, speech and cause malocclusion. This case report presents a female child of 12 years with partial anodontia or oligodontia with numerous permanent missing teeth.

Keywords: Anodontia, Hypodontia, Oligodontia, Missing teeth.

Introduction

Occurrence of anodontia is less than hypodontia. Literature reports prevalence of 0.1% to 0.7% in primary teeth and 3 to 7.5% in permanent teeth.¹ Approximately 1% of the population has oligodontia.² More than 70 syndromes and genetic disorders are associated with hypodontia and anodontia. Most common are Rieger's, Robinson's and Focal dermal hypoplasia. Most often mesoectodermal dysplasia, ectodermal dysplasia and occulomandibulodyscephaly are associated with anodontia and consists anodontia, oligodontia and missing permanent but presences of deciduous dentition respectively. Absence of lateral incisor is commonest.³ Ectodermal dysplasia is seen in early stages of development and transmitted by X linked disorder.⁴ The current implicated gene include the PAX9, MSX1, AXIN2 and He- Zhao deficiency, which is associated with an unknown gene that maps to chromosome 10q11.2.⁵

Case Report

A 12 year 6 months old female child reported with complaint of missing teeth in both arches. Bystanders does not reveal any medical history or any systemic condition associated with no history of prior hospitalization. Patient is not having any drug allergy and has not taken any medication for major illness. According to her age she had adequate height and weight. Gait was normal and her built was average. The hereditary background revealed no known consanguinity in the family or history of anodontia or ectodermal dysplasia is either of the maternal or paternal lineages. Mother and father had complete primary and permanent dentition. She had two siblings. Younger brother 10-year-old and younger sister 7-year-old. Both the sibling had a normal compliment of primary and permanent teeth. On extra oral examination no abnormality was

detected. Intraoral examination revealed healthy gingivae, normal mucosal, palatal and periodontal tissue. Speech was proper. Maxillary central incisors were present. Lateral incisors were absent. Canines were erupting, premolars were in occlusion and complete absence of maxillary molars were seen. Mandibular lateral incisors and canines were present. On the right side first premolar and on the left side second premolar was present. Bilateral first molar was present. The canines were in erupting positions. Mandibular primary central incisors were not exfoliated and permanent second molars were missing. (Fig. 1) By standers were confused regarding the exfoliation of primary and permanent teeth and revealed the history that there were some exfoliations few years before. Patient was using removable partial dentures for some of the missing teeth. Patient was already having a Panoramic radiograph, orthopantomography (Fig. 2) which they took a year before including a lateral cephalogram (Fig. 3). Because there was a time lag between the clinical evaluation and radiographs taken it is difficult to correlate both the entities. Orthopantomogram showed open apex with all the permanent teeth. Loss of enamel and dentin thickness with maxillary central incisors. Root caries was seen in permanent mandibular first molar on the left side. Mesial drift of both the mandibular first molars were present die to the space present medially. Alveolar ridge was present below cementoenamel junction which shows some sort of alveolar compromise. According to the situation present the treatment plan was in various phases. First includes restoring the carious teeth with crowns to reduce further chances of infection and tooth fracture. For esthetic improvement a modified lingual arch need to be fabricated to replace the missing teeth. The child and bystanders were demonstrated with excellent home care habits, meticulously brushing with the soft tooth brush and consumption of a healthy diet. Professionally applied fluoride and vigilant monitoring of the dentition

was advised at six months interval. A daily mouth rinse was prescribed and added importance of daily tooth brushing and flossing was emphasized to the child and parent to minimize the possibility caries and periodontal disease. As the age advances permanent prosthesis with implant was advised for rehabilitation and replacement of missing teeth.

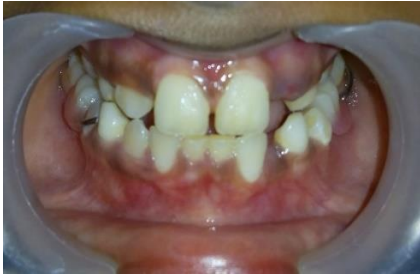

Fig 1: Picture showing intra oral occlusion and condition

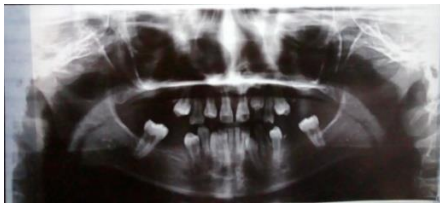


Fig. 2: Orthopantomogram of patient

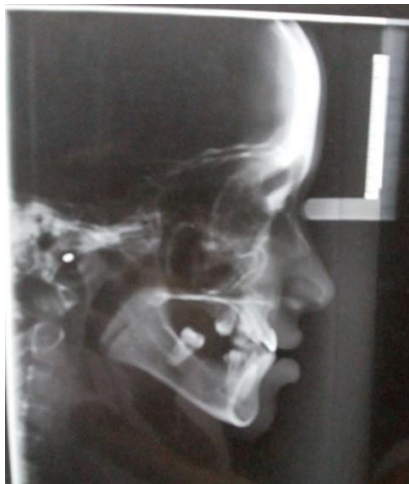

Fig. 3: Lateral cephalogram of patient

Discussion

Complete anodontia and ectodermal dysplasia is rare in females and very cases have been reported. Fourteen cases of complete anodontia and three cases of primary teeth presence and permanent teeth absence was reported.⁶ Eight cases of anodontia in permanent dentition was reported.⁷ Life time preservation of

primary teeth and alveolar ridge is a problem rarely encountered by the clinicians.⁸ Preservation of what is left is a golden fact before restoration of what is lost. The aims, objectives and goals of the treatment is to achieve the function first and then esthetics. Preserving the primary and permanent teeth in such situation is important to restore function and also preserve the alveolar ridge for the future prosthesis.

Conclusion

As seen in the literature many cases have been reported for different types of anodontia still every case keeps up a challenging scenario to identify the etiology, conclude a diagnosis and plan the best management. Such cases need delicate handling of the hard and soft tissues in the oral region for the betterment and quality of life of patients.

Funding: No funding sources.

Conflict of interest: None declared.

References

1. <https://books.google.co.uk/books?id=NqGUsPThOH8C&pg=PA12&dq=anodontia&hl=en&sa=X&ved=0ahUKEwjCILmm9KZAhWM66QKHW1gBFYQ6AEIzAA#v=onepage&q=osteonecrosis&f=false>
2. Vahid-Dastjerdi E, Borzabadi-Farahani A, Mahdian M, Amini N. "Non-syndromic hypodontia in an Iranian orthodontic population *J Oral Sci* 2010;52(3):455-61. doi:10.2334/josnusd.52.455 (https://doi.org/10.2334/josnusd.52.455.) PMID 20881340 (https://www.ncbi.nlm.nih.gov/pubmed/20881340).
3. Shaw, W. The influence of children's dentofacial appearance on their social attractiveness as judged by peers and lay adults* 1, *Am J Orthod* 1981;79(4):399-415. Dorland. Dorland's Medical Dictionary. y1998
4. Chaitra T R et al. ANODONTIA OF PERMANENT TEETH — A CASE REPORT. *Pakistan Oral & Dental J* 2010;30(1):165-67.
5. Brad W. Neville, Douglas D. Damm, Carl M. Allen, Jerry E. Bouquot. *Oral Maxillofac Pathol* 3rd edition. Saunders Elsevier;77-78.
6. Beierle L E, Jorgenson R J. Anodontia in a child: report of case; *ASDC J Dent Child* 1978;45(6):483-87.
7. Clare P. T. Correspondence. *Dental Dig.* 1922, 28: 731-32.
8. Clare McNamara, Tim Foley, Catherine M. McNamara. Multidisciplinary Management of Hypodontian Adolescents: Case Report. *J Can Dent Assoc* 2006;72(8):740-46.

How to cite the article: H. Shilpa, Jairaj A, G. Deepthi, Pareek P, Sehrawat K. Partial anodontia in permanent dentition: A case report. *IP Int J Med Paediatr Oncol* 2018;4(3):125-126.