

## Idiopathic Intracranial Hypertension (IIH) in a tertiary referral teaching centre in Central India

Ayush Dubey<sup>1,\*</sup>, Sunil Athale<sup>2</sup>

<sup>1</sup>Senior Resident, <sup>2</sup>Associate Professor, Dept. of Neurology, SAIMS Medical College, Indore, Madhya Pradesh

**\*Corresponding Author:**

Email: ayushdubey2@yahoo.co.in

### Abstract

Idiopathic Intracranial Hypertension (IIH) is mainly a disease affecting women of child bearing age. It is characterized by increased intracranial pressure in the absence of any tumor or other structural brain abnormality. The main symptoms include headache, blurring of vision, diplopia and pulsatile tinnitus. This condition has a strong correlation with obesity. It is diagnosed in accordance with Modified Dandy's Criteria which include signs and symptoms of raised intracranial pressure, absence of localizing signs on neurological examination except lateral rectus palsy, absence of structural abnormality on brain imaging, absence of CSF abnormalities except raised opening pressure and awake and alert patient. Fundus abnormalities include papilloedema of varying grades. To date, there has been no study to correlate opening pressure on lumbar puncture with fundus abnormalities. This study was done to correlate grades of papilloedema with opening pressures on lumbar puncture study and thus to estimate prognosis in these patients.

**Keyword:** Idiopathic Intracranial Hypertension, IIH, Fundus, Papilloedema

### Introduction

Idiopathic intracranial hypertension is mainly a disease of women in the childbearing age, and its prevalence is increasing due to the worldwide obesity epidemic. There are many risk factors that have been associated with IIH, many of which appear to be chance associations.<sup>(1)</sup> The association between obesity and IIH has not been satisfactorily explained and speculation regarding the role of centrally distributed adiposity and co-existing obstructive sleep apnoea remain unsubstantiated.<sup>(2,3)</sup>

Idiopathic intracranial hypertension (IIH), earlier also known as benign intracranial hypertension (BIH) or pseudotumor cerebri (PTC), is a neurological disorder that is characterized by increased intracranial pressure in the absence of a tumor or other diseases. The main symptoms are stroke-like headache, nausea, and vomiting, as well as pulsatile tinnitus (sounds perceived in the ears, with the sound occurring in the same rhythm as the pulse), double vision and other visual symptoms. If untreated, it may lead to swelling of the optic disc in the eye, which can progress to vision loss.<sup>(4)</sup> With regards to symptomology, headaches are the most common symptoms reported. The associated headaches are directly correlated to the increased intracranial pressure, hence they are worse upon awaking and exacerbated by maneuvers that increase intra-cranial pressure. These are holocranial, involving the entire cerebrum. The headaches are described as gradually increasing in intensity and commonly depicted as pulsating in nature. Improvement of headaches is often noted with a decrease in intracranial pressure.<sup>(5-8)</sup> IIH is diagnosed with a brain scan and a lumbar puncture; lumbar puncture may also provide temporary and sometimes permanent relief from the symptoms. Some

respond to medication (with the drug acetazolamide), but others require surgery to relieve the pressure. The condition may occur in all age groups, but is most common in women aged 20–40. Recognizing and understanding the risk factors that truly contribute to intracranial hypertension is important in both diagnosing and understanding the pathophysiology of the disease.<sup>(9)</sup> There are also many diseases that cause intracranial hypertension that mimic IIH, which are important to recognize because the outcome and treatment are different depending on the etiology. The whole world's annual incidence of IIH is about 0.9/100,000 persons but its higher [3.5/100,000] in females 15 to 44 years of age.<sup>(10)</sup>

The original criteria for IIH were described by Dandy in 1937.

Dandy criteria

1. Signs & symptoms of increased ICP – CSF pressure >25 cmH<sub>2</sub>O.
2. No localizing signs with the exception of abducens nerve palsy
3. Normal CSF composition.
4. Normal to small (slit) ventricles on imaging with no intracranial mass

They were modified by Smith in 1985 to become the "modified Dandy criteria". Smith included the use of more advanced imaging: Dandy had required ventriculography, but Smith replaced this with computed tomography. In a 2001 paper, Digre and Corbett amended Dandy's criteria further. They added the requirement that the patient is awake and alert, as coma precludes adequate neurological assessment, and require exclusion of venous sinus thrombosis as an underlying cause. Furthermore, they added the

requirement that no other cause for the raised ICP is found.<sup>(11)</sup>

#### Modified Dandy criteria

1. Symptoms of raised intracranial pressure (headache, nausea, vomiting, transient visual obscurations, or papilloedema)
2. No localizing signs with the exception of abducens (sixth) nerve palsy.
3. The patient is awake and alert.
4. Normal CT/MRI findings without evidence of thrombosis.
5. LP opening pressure of >25 cmH<sub>2</sub>O and normal biochemical and cytological composition of CSF.
6. No other explanation for the raised intracranial pressure

In a 2002 review, Friedman and Jacobson propose an alternative set of criteria, derived from Smith's. These require the absence of symptoms that could not be explained by a diagnosis of IIH, but do not require the actual presence of any symptoms (such as headache) attributable to IIH. These criteria also require that the lumbar puncture is performed with patient lying sideways, as a lumbar puncture performed in the upright sitting position can lead to artificially high pressure measurements. Friedman and Jacobson also do not insist on MR venography for every patient; rather, this is only required in atypical cases.<sup>(12)</sup>

This study was performed to study the clinical profile of IIH and to correlate the opening pressure of CSF with the fundus abnormalities.

#### Aims and Objectives

- To study the clinical profile of IIH.
- To correlate the opening pressure of CSF with the fundus abnormalities.

#### Methodology

This was a prospective observational study done in one year from 1<sup>st</sup> June, 2014 to 31<sup>st</sup> December, 2015

##### Inclusion Criteria

- All patients of headache presenting to Neurology department as clinically suspected cases of IIH.
- Patient ready to give consent for lumbar puncture and imaging studies.
- Age > 12 years

##### Exclusion criteria

- Other causes of Intracranial hypertension
- Abnormal MRI brain or venogram as per imaging protocol of department of Radiology.
- Any contraindication for MRI/CSF.

All the patients who presented to the Department of Neurology and who were diagnosed to have IIH as per the Headache Society Criteria were included in the study and their fundus picture was correlated with the CSF opening pressure.

#### Results & Observations

This study was conducted on the 14 patients who presented to the Department of Neurology and who were diagnosed to have IIH as per the Headache Society Criteria, their fundus picture was correlated with the CSF opening pressure.

Majority of the cases were 21-30 years of age 5 [35.7%] followed by 4 [28.6%] of 31-40 years age, 3 [21.4%] were below 20 years age and only 2 [14.3%] were above 40 years of age. The mean age of the patients was 30.2 ± 2.8 years, ranging from 13 to 52 years.

Among all the cases, headache was the most common presenting complaint found in 13 [92.9%] cases, followed by blurring of vision in 11 [78.6%] cases, diplopia was found in 8 [57.1%] cases and 7 [50%] cases complained pulsatile tinnitus. Lateral rectus palsy was found in 6 [42.8%] cases, three were bilateral and 3 were unilateral. Visual field defects were found in 7 [50%] of the cases. Majority 4 [28.6%] of the cases had papilloedema of grade 2, followed by 3 [21.4%] cases had grade 1, 3 and 4 grade papilloedema each and only one [7.1%] case had papilloedema of grade 5. MRI Brain and venogram finding showed normal findings in majority of the cases 12 [85.7%], one [7.1%] case had empty sella and one [7.1%] also had distended optic nerve sheath. The mean CSF opening pressure was directly proportional to the grade of papilloedema. Pearson correlation coefficient [ $r = 0.91$ ,  $p < 0.001$ ]. The time from onset of symptom of headache to diagnosis of IIH was more than one month in most of the cases 8 [57.1%] and in 6 [42.9%] cases it was less than one month.

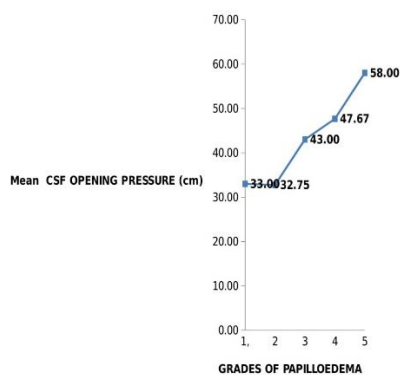
There was no significant correlation between grades of papilloedema and the time from onset of headache. There was no significant correlation between CSF opening pressure and the time from onset of headache to diagnosis of IIH, [ $P = 0.14$ ].

The time from onset of blurred vision symptom to diagnosis of IIH was more than one month in most of the cases 8 [57.1%] and in 6 [42.9%] cases it was less than one month. There was no significant correlation between grades of papilloedema and the time from onset of blurring of vision to diagnosis of IIH, [ $P = 0.17$ ]. There was no significant correlation between CSF opening pressure and the time from onset of blurred vision to diagnosis of IIH, [ $P = 0.64$ ].

**Table: Correlation of grades of papilloedema & CSF opening pressure**

Grades of Papilloedema	Mean CSF Opening Pressure (cm)	±Std. Deviation
1	33.00	4.58
2	32.75	6.29
3	43.00	3.61
4	47.67	4.51
5	58.00	NA

Correlation of GRADES OF PAPILOEDEMA and CSF OPENING PRESSURE



## Discussion

This study was conducted on the 14 patients who presented to the Department of Neurology and who were diagnosed to have IIH as per the Headache Society Criteria, their fundus picture was correlated with the CSF opening pressure.

In this study all the 14 cases were females. IIH is a disease mostly affecting females and there is a clear female preponderance in almost all studies done yet.<sup>(13,14,16,17)</sup>

In this study, out of 14 cases, 5 (35.7%) patients were overweight with BMI ranging from 25 - 29.9 and 9 (64.3%) were obese with BMI more than 30. Johnson et al.<sup>(18)</sup> studied 15 female patients with mean weight of 110.5±28.7 kg and mean body mass index of 40.7±13.0 kg/m<sup>2</sup>. Szewka et al.<sup>(19)</sup> in their study of 414 patients of IIH, saw that 158 had BMI ≥40 (World Health Organization Obese Class III) and 172 had BMI 30-39.9. Patients with BMI ≥40 were more likely to have severe papilledema at first neuro-ophthalmology encounter than those with a lower BMI (P = 0.02). In their study, Rowe et al.<sup>(20)</sup> studied 34 patients (31 female and 3 male) and 70.5% of patients were obese (BMI of ≥30 kg/m<sup>2</sup>)

In this study among all the cases, headache was the most common presenting complaint found in 13 [92.9%] cases, followed by blurring of vision in 11 [78.6%] cases, diplopia was found in 8 [57.1%] cases and 7 [50%] cases complained pulsatile tinnitus. Lateral rectus palsy was found in 6 [42.8%] cases, three were bilateral and 3 were unilateral. Visual field defects were found in 7 [50%] of the cases. Contreras-Martin et al found in their study that Fifty-two (85.25%) of the 61 patients with IIH presented headache. Abnormal visual field test results, visual disturbances —phosphenes— or decreased visual acuity were observed in 33 (59.01%) subjects. Ophthalmoparesis of the sixth cranial nerve was identified in 7 (11.5%) patients. Afonso et al observed that headache was present in 80% of patients and visual symptoms in 92%, including diplopia, and blurred vision. Most patients (68%) had moderate or severe visual loss at presentation. Visual function improved in 28 patients, worsened in five, and remained unchanged in 17. Incecik et al detected that the most common symptom was headache, recorded in 93.8% of the

patients. And Sencer et al found that visual impairment was the main symptom in this patient group, whereas headache was a secondary complaint. Pai et al<sup>(21)</sup> in their study had all their eighteen patients presenting as headache whereas blurring of vision in sixteen cases.

In this study Majority 4 [28.6%] of the cases had papilloedema of grade 2, followed by 3 [21.4%] cases had grade 1, 3 and 4 grade papilloedema each. Only one [7.1%] case had papilloedema of grade 5. Contreras-Martin et al on their ophthalmological examinations found that 81.96% of the patients presented bilateral papilloedema. Pai et al found bilateral papilloedema in seventeen out of eighteen patients. Roy et al<sup>(22)</sup> found papilloedema in 72% cases. Bilateral disc edema was seen in 46 (92%) patients and unilateral disc edema in 4 (8%) patients in the study done by Ambika et al.<sup>(23)</sup>

MRI Brain and venogram finding showed normal findings in majority of the cases 12 [85.7%], one [7.1%] case had empty sella and one [7.1%] also had distended optic nerve sheath. In the study of Contreras-Martin et al Cranial computed tomography was performed for all patients, and no lesions justifying IIH were observed. Magnetic resonance was performed for 59 (96.72%) patients. Pai et al found normal MRI and venogram in all 18 of their patients. Ambika et al did MRI in 42 patients out of which 25 were normal and the remaining 17 showed features of IIH in the form of perioptic space widening and empty sella.

In our study the mean CSF opening pressure was directly proportional to the grade of papilloedema. Pearson correlation coefficient [r =0.91, p<0.001] In the study of Contreras-Martin et al CSF opening pressure was measured with patients in the lateral decubitus position, and the mean pressure value (meanP) was 33.05 cm H<sub>2</sub>O. Thirty nine patients had opening pressure of 250–350 mm H<sub>2</sub>O and 11 patients had opening pressure > 350 mmH<sub>2</sub>O in the study done by Ambika et al. In the study by Pai et al, lumbar puncture revealed a CSF opening pressure of more than 40 cm of H<sub>2</sub>O in 6 patients, 25-40 cm of H<sub>2</sub>O in 12 patients.

In this study the time from onset of symptom to diagnosis of headache was more than one month in most of the cases 8 [57.1%] and in 6 [42.9%] cases it was less than one month. Afonso et al observed that time from symptom onset to diagnosis of IIH was <1 month in 21, 1-6 months in 14, and >6 months in 14 patients.

The limitation of this study was small sample size of the patients.

## Conclusions

Idiopathic Intracranial Hypertension (IIH) is a disease primarily affecting women of child bearing age. Incidence is more in patients with increased body mass index. The most common presenting symptom is headache followed by blurring of vision and pulsatile tinnitus. Neurodeficits on examination include sixth nerve palsy which can be unilateral or bilateral. MRI can be absolutely normal in these cases or may show findings

such as distended optic nerve sheath. Increased opening pressure on lumbar puncture is proportional to the grades of papilloedema seen on fundus examination and thus to worse visual prognosis.

## References

1. Raoof N, Sharrack B, Pepper IM, et al. The incidence and prevalence of idiopathic intracranial hypertension in Sheffield, UK. *European journal of neurology: the official journal of the European Federation of Neurological Societies*. 2011;18:1266–8. [PubMed: 21426442]
2. Jennum P, Borgesen SE. Intracranial pressure and obstructive sleep apnea. *Chest* 1989;95(2):279-83.
3. Sugerman HJ, Felton WL, 3rd, Salvant JB, Jr., Sismanis A, Kellum JM. Effects of surgically induced weight loss on idiopathic intracranial hypertension in morbid obesity. *Neurology* 1995;45(9):1655-9.
4. Kesler A, Gadoth N. Epidemiology of idiopathic intracranial hypertension in Israel. *Journal of neuro-ophthalmology: the official journal of the North American Neuro-Ophthalmology Society*. 2001;21:124.
5. Wall M. The headache profile of idiopathic intracranial hypertension. *Cephalalgia*.1990;10: 331-335.
6. Friedman DI, Rausch EA. Headache diagnoses in patients with treated idiopathic intracranial hypertension. *Neurology*.2002;58:1551-1553.
7. Kahle KT, Walcott BP, Staley KJ. Resolution of headache and papilledema in idiopathic intracranial hypertension associated with inhibition of Na<sup>+</sup>-K<sup>+</sup>-2Cl<sup>-</sup>-cotransport. *J Child Neurol*. 2011;26:205-208.
8. Friedman DI, Jacobson DM. Diagnostic criteria for idiopathic intracranial hypertension. *Neurology*.2002;59:1492-1495.
9. Durcan FJ, Corbett JJ, Wall M. The incidence of pseudotumor cerebri. Population studies in Iowa and Louisiana. *Arch Neurol*. 1988;45:875–7.
10. John Chen, Michael Wall, Epidemiology and Risk Factors for Idiopathic Intracranial Hypertension, *Int Ophthalmol Clin*. 2014;54(1): doi:10.1097/HIO.0b013e3182aabf11.
11. Craig JJ, Mulholland DA, Gibson JM. Idiopathic intracranial hypertension; incidence, presenting features and outcome in Northern Ireland (1991–1995). *Ulster Medical Journal*.2001;70:31–5.
12. Radhakrishnan K, Thacker AK, Bohlaga NH, et al. Epidemiology of idiopathic intracranial hypertension: a prospective and case-control study. *Journal of the Neurological Sciences*.2003;116:1828.
13. Contreras-Martin, J.H. Bueno-Perdomo Idiopathic intracranial hypertension: descriptive analysis in our setting, *Neurología*. 2015;30(2):106—110.
14. Afonso CL, Talans A, Monteiro ML. Factors affecting visual loss and visual recovery in patients with pseudotumor cerebri syndrome. *Arq Bras Oftalmol*. 2015 May-Jun;78(3):175-9. doi: 10.5935/0004-2749.20150045.
15. J. Alexander Fraser, Beau B. Bruce, Janet Rucker, Lisa-Ann Fraser, MD, Edward J. Atkins, MD, Nancy J. Newman, MD, and Valérie Biousse, MD Risk factors for idiopathic intracranial hypertension in men: a case-control study, *J Neurol Sci*. 2010 March 15;290(1-2): 86. doi:10.1016/j.jns.2009.11.001.
16. Incecik F, Hergüner MO, Altunbaşak S. Evaluation of sixteen children with pseudotumor cerebri. *Turk J Pediatr*. 2011 Jan-Feb;53(1):55-8.
17. Sencer A, Akcakaya MO, Basaran B, Yorukoglu AG, Aydoseli A, Aras Y, Sencan F, Satana B, Aslan I, Unal OF, Izgi N, Canbolat A. Unilateral endoscopic optic nerve decompression for idiopathic intracranial hypertension: a series of 10 patients. *World Neurosurg*. 2014 Nov;82(5):745-50. doi: 10.1016/j.wneu.2014.03.045.
18. Johnson LN, Krohel GB, Madsen RW, March GA Jr. The role of weight loss and acetazolamide in the treatment of idiopathic intracranial hypertension (pseudotumor cerebri) *Ophthalmology*. 1998 Dec;105(12):2313-7.
19. Szewka AJ, Bruce BB, Newman NJ, Biousse V. Idiopathic intracranial hypertension: relation between obesity and visual outcomes. *J Neuroophthalmol*. 2013 Mar;33(1):4-8.
20. Rowe FJ, Sarkies NJ. The relationship between obesity and idiopathic intracranial hypertension. *International Journal of Obesity January 1999, Volume 23, Number 1*
21. Pai SG, Sharma T, Gupta R. Idiopathic intracranial hypertension: Clinical profile and outcome. *J Clin Ophthalmol Res* 2016;4:25-9.
22. Roy Arun Grace, Kollencheri Puthenveetil Vinayan, Anand Kumar. Idiopathic intracranial hypertension in pediatric population: Case series from India. *Neurology India | Sep-Oct 2013 | Vol 61 | Issue 5*.
23. S. Ambika, Deepak Arjundas, Veena Noronha, Anshuman. Clinical profile, evaluation, management and visual outcome of idiopathic intracranial hypertension in a neuro-ophthalmology clinic of a tertiary referral ophthalmic center in India. *Ann Indian Acad Neurol*, January-March 2010, Vol 13, Issue 1.