

Lipomyelomeningocele: Controversies in management

Abhishek Singh^{1*}, Samarendra Nath Ghosh², Anup Kumar Chaudhuri³, S.I. Sadique⁴,
Subhamitra Chaudhuri⁵

¹Senior Resident, ²Professor and Head, ³Professor, ⁴Assistant Professor, ⁵Senior Resident, Dept. of Neurosurgery, IPGME&R Bangur Institute of Neuroscience, Kolkata, West Bengal, India

***Corresponding Author:**

Email: drabhiz447@gmail.com

Abstract

Management of lipomyelomeningocele is one of the most discussed and controversial topic in recent years. Till date, there is no consensus on most appropriate mode of management for lipomyelomeningocele, particularly in asymptomatic patients. This paper tries to sort out controversies associated with lipomyelomeningocele based upon various literatures and also taking into account patient profile of a developing country.

Keywords: Lipomyelomeningocele, Conservative, Surgery, Controversy, Management.

Introduction

Even though our knowledge on various types of spinal dysraphism has gone a long way, courtesy improvement in our understanding on etiopathogenesis and moreover embryological aspect associated with spinal dysraphism, still, controversies persists regarding its most appropriate mode of management. Controversy is even higher in certain closed form of spinal dysraphism such as lipomyelomeningocele specially when the patient is asymptomatic. This paper tries to sort out controversies associated with lipomyelomeningocele based upon various literatures and also taking into account patient profile of a developing country.

Johnson first described a lipomyelomeningocele in 1857,¹ but Rogers and colleagues are credited with introducing the term lipomyelomeningocele in 1971.² Incidence of lipomyelomeningocele is 1 in 4000 live births with slight female preponderance. Not only the management but when we go through available literatures we find that definition of lipomyelomeningocele itself is controversial. Lipomyelomeningocele may be defined as a defect in the spine through which the lipomatous substance arising from subcutaneous tissue is inserted into spinal canal. Now, the controversial point here is that whether there is any neural tissue outside the spinal canal in case of lipomyelomeningocele? If we go through the embryology, we find that lipomyelomeningocele is due to defect during secondary neurulation at the stage of dysjunction.^{3,4} Dysjunction is the process by which neural ectoderm gets separated from the cutaneous ectoderm and if somehow premature dysjunction occurs, a dorsal cleft is left, as a result of which paraaxial mesenchyma gets access to the developing neural tube, prevents its closure, and induces the totipotent mesenchymal cells to differentiate into adipocytes. Spina bifida and hydrocephalus association of Canada very simply defines lipomyelomeningocele as an abnormal fat accumulation that starts below the skin

and extends through an opening in the spine to the spinal cord. This clearly states that defect starts from outside and is extending into the spinal canal and not vice versa so there should not be any neural component outside the canal. However in some cases we may find neural tissue outside the spinal canal and that is probably due to the expansion of subarachnoid space.

Classification: There are various classification system of lipomyelomeningocele based upon lipoma-cord interface, of which, Chapman classification system is well known. According to Chapman, lipomyelomeningocele is classified mainly into three types:⁵

- 1. Dorsal:** In dorsal type of lipomyelomeningocele, lipoma is attached to the dorsal aspect of conus medullaris and there is no neural tissue within the substance so from surgical point of view, this type is easier to dissect and complete removal of lipomatous tissue can be attempted.
- 2. Caudal or Terminal:** In this type, lipoma is attached to the terminal part of conus medullaris and unlike dorsal type we may find neural tissue within the lipomatous substance, so, it is difficult to remove surgically and a temptation to completely remove lipoma may result in damage to the neural tissues.⁶
- 3. Transitional:** This may be considered to be a subtype of dorsal variety where the lipoma starts from conus medullaris and extends upto the filum terminale.

As far as diagnosis is concerned, Ultrasonography and MRI is supposed to substantially aid in diagnosis as well as planning of treatment, both prenatally and postnatally.

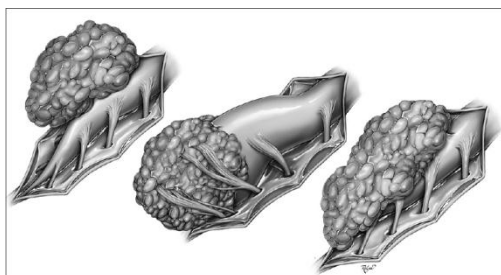


Fig.1: Showing different types of lipomyelomeningocele

Management: Management of lipomyelomeningocele is one of the most discussed and controversial topic in recent years. Till date, there is no consensus on most appropriate mode of management for lipomyelomeningocele, particularly in asymptomatic patients. In various studies from different groups, it is suggested that there is progressive neurological, urological and orthopaedic deficits in patients with lipomyelomeningocele if they are left untreated. Keating and co. reported that more than 92% of older children presented with urinary incontinence in comparison to 26% in infants.^{7,8} Kanev and Bierbrauer demonstrated that most of the children younger than 6 months who were asymptomatic gradually presented with neurological & urological dysfunction on follow up for longer time⁹. Similar findings were reported by Hoffman & colleagues who demonstrated an 85% deterioration in children who were left untreated.¹⁰ However study from Paris and Osaka group reported progressive neuro-urological deficits in patients who were operated prophylactically too. So, in an endeavour to minimize the controversy, we have tried to individualise the treatment and divided the patients into three specific groups:

1. Patients Expected to have Poor Surgical Outcome:¹¹

- Patients with major associated congenital defects of other system
- Megalencephaly at birth
- Patients with poor general condition
- Patients with total paralysis of limbs

This group of patients are poor surgical candidate not only due to associated comorbidities & poor general condition but also due to poor neuro-urological outcome following surgery. So, surgery should be avoided in these patients and conservative management should be considered a reasonable option.

2. Symptomatic Patients

Even though there is lot of controversy regarding most appropriate mode of treatment for lipomyelomeningocele, it is certain that earliest the intervention, better is the prognosis in symptomatic patients. Even if an asymptomatic patient is on conservative management, there should be no doubt that surgical intervention should be contemplated as soon as the symptom arises. Most common symptom in

lipomyelomeningocele is urological dysfunction which appear prior to motor and sensory loss and patient should be asked to report as soon as such symptom arises.

3. Asymptomatic Patients

Management of this group of patient is most controversial. There are two school of thoughts regarding management in asymptomatic patients. One favouring the conservative approach suggests that if we operate on an asymptomatic patient there are chances that the asymptomatic patient will be rendered symptomatic and second, chances of UTI, hydronephrosis and other urological complications are more in patients operated for lipomyelomeningocele than other cases of closed spinal dysraphism.¹² However the group favouring surgical approach advocates that there is progressive neurological, urological and orthopaedic deficiency in almost all patients who are left untreated¹³ and second, with advancement in paediatric anaesthesia, electrophysiological monitoring and perioperative care, these patients can be operated safely.

Now, we are of the view that even though there is lot of controversy regarding the most appropriate mode of management of lipomyelomeningocele in literatures, they uniformly agree in two points. First, if the patient is left untreated, progressive neuro-urological deficit is a rule rather than an exception and second, preoperative neuro-urological status is a prognostic factor in determining the postoperative outcome. Most of the available literatures while documenting the efficacy of conservative management in asymptomatic patients have probably failed to analyze association of lipomyelomeningocele with tethered cord. Patients with lipomyelomeningocele may be asymptomatic in early childhood but its association with tethered cord will eventually lead to symptoms which may be difficult to treat on a later stage when the symptoms have already progressed.

Conclusion

Given the natural history of disease, congenital lipomyelomeningocele if left untreated will eventually lead to progressive neuro-urologic deficits and with advances in operative techniques, electrophysiological monitoring and our understanding of disease process, surgery should be considered as early as possible regardless of presence or absence of symptoms to prevent neuro-urologic deteriorations.

References

- Johnson A. Fatty tumor from the sacrum of a child, connected with the spinal membranes. *Trans pathol soc London.* 1857;8:16-18.
- Rogers HM, Long DM, Chou SN, et al. Lipomas of the spinal cord and cauda equina. *J Neurosurg.* 1971;34:349-354
- McLone DG, Naidich TP. Terminal myelocystocele. *Neurosurgery.* 1985;16:36-43.

4. Naidich TP, McLone DG. Spinal dysraphism. Newton TH, Potts DG. Modern Neuroradiology. Clavadel press: San Francisco; 1983:299-315. Computed Tomography of the spine and spinal cord. Vol.1.
5. Chapman PH. Congenital intraspinal lipomas: anatomic considerations and surgical treatment. Childs Brain. 1982;9:37-47.
6. McLone DG, Mutluer S, Naidich TP. Lipomeningoceles of the conus medullaris. S. Karger: Basel; 1983:170-177. Raimondi AJ. Concepts in Pediatric Neurosurgery. Vol.3.
7. Sutton LN. Lipomyelomeningocele. Neurosurg Clin N Am. 1995;6:325-328.
8. Keating MA, Rink RC, Bauer SB, et al. Neurological implications of the changing approach in management of occult spinal lesions. J Urol. 1988;140(5 pt 2):1299-1301.
9. Kanev PM, Bierbrauer KS. Reflections on the natural history of lipomyelomeningocele. Pediatr Neurosurg. 1995;22:137-140.
10. Hoffman HJ, Taecholarn C, Hendrick EB, et al. Management of lipomyelomeningoceles. Experience at the hospital for sick children, Toronto. J Neurosurg. 1985;62:1-8.
11. Ramamurthi B. Problems in spina bifida in developing countries. J Ind Med Assn. 1990;88:6.
12. Macejko AM, Cheng EY, Yerkes EB, Meyer T, Bowman R M, Kaplan WE: Clinical urological outcomes following primary tethered cord release in children younger than 3 years. J Urol 178:1738-1743, 2007.
13. Chocrane DD, Finley C, Kestle J, et al. The patterns of late deterioration in patients with transitional lipomyelomeningocele. Eur J Paediatr Surg. 2000;10(suppl 1):13-7.