

Evaluation and assessment of maxillary lateral incisor in cases of palatally impacted canines- A CBCT Study

Santosh Ramegowda¹, Nikita Khillon^{2*}

¹Professor & Head, ²MDS Student, Department of Orthodontics and Dentofacial Orthopedics, Vokkaligara Sangha Dental College and Hospital Bangalore

***Corresponding Author**

Email: dr.nikitakhillon.orthod@gmail.com

Abstract

In cases involving palatally impacted maxillary canines, it is essential to properly identify the location of the impacted tooth. In addition, estimating treatment duration is important to the orthodontist and patient.

Purpose: This study uses three-dimensional cone beam computed tomography (CBCT) to evaluate and assess accurately the relationship between the palatally impacted canine and maxillary lateral incisor on the same or the opposite side and relate this position to treatment duration.

Methods: A sample of 30 cases involving palatally impacted canines with pretreatment CBCT scans was identified. After registration to a standardized coordinate system, the initial position and angulation of the impacted tooth was measured, along with the morphological variation observed in the adjacent lateral incisor.

Results: In this study the maxillary lateral incisors in the palatally displaced canine group tended to be more upright in the sagittal and coronal plane. The sagittal angulation of the canine and the coronal angulation of the canine were highly correlated with each other.

Conclusion: The impacted maxillary canine has a significant effect on the morphology of adjacent lateral incisor.

Keywords: Impacted CBCT, KPO

Introduction

Impacted maxillary canine is a common finding in orthodontics, with an incidence of approximately 1 to 3 percent in caucasians and more impactions are found in females than males and palatal impactions are twice or more as likely as buccal impactions in causation populations.

The identification of an impacted canine is only the first step in the proper diagnosis of such a case. After examining complicating factors such as pathologic findings and possible root resorption of adjacent teeth, the orthodontist's focus quickly turns to the localization of the impacted tooth. Visualization of the correct location and orientation is essential in determining appropriate surgical strategies as well as the feasibility and Mechanotherapy estimate of treatment time and cost is of significant importance to the orthodontist and patient.

The localization of impacted maxillary canines has traditionally been accomplished using a variety of intraoral and extraoral radiographic techniques. Several studies have attempted to correlate the morphology of maxillary lateral incisor adjacent to palatally impacted canine. Unfortunately, the weaknesses of these methods have been shown by studies which demonstrate the distortions present in panoramic radiographs.

In recent years, cone beam computed tomography (CBCT) has been used in orthodontic treatment planning, especially in cases involving impacted teeth. The distortion-free, three-dimensional data this technology provides has greatly improved the ability of clinicians to precisely localize impacted canines and

plan treatment accordingly. The aim of the present study is to evaluate the relationship between palatally impacted canine and morphology of maxillary lateral incisor on the same or the opposite side.

Materials and Methods

Source of Data: This study was carried out in the Department of Orthodontics and Dentofacial Orthopedics, V.S. Dental College and Hospital, Bangalore, Karnataka.

An experimental group (palatally displaced canines) of 30 patients with 36 palatally displaced canines (18 from boys, 12 from girls), was selected from the records of patients referred to a radiology practice specializing in cone-beam computed tomography imaging. The palatally displaced canine group was matched with a control group comprising 30 normal subjects with 60 canines.

The Cone Beam Volumetric tomography digital imaging files were imported into imaging software. The volumetric images were reoriented as if the head was looking straight out of the computer screen, with the occlusal plane horizontal, touching the incisal edge of the maxillary central incisors and the mesio-buccal cusp tips of the maxillary first molars. Radiographic images of the canine and the lateral incisor in the coronal and sagittal sections were reconstructed from the volumetric image. The angular and linear measurements were made with the software measurement tools and images were magnified by 200% to allow a better view.

Angular Measurements

1. Sagittal angulation was measured relative to a vertical line that was drawn perpendicular to the occlusal plane on the reconstructed sagittal image: CAN_SAG
2. Coronal angulation was measured relative to a facial line that was drawn perpendicular to the occlusal plane on the reconstructed coronal image: CAN_COR
3. The sagittal and coronal angulations of the lateral incisor were measured similarly to those for the canines: LAT_COR , LAT_SAG

The angle values were recorded positive if the crown was tipping mesially in the sagittal view or buccally in the coronal view, and as negative if the crown was tipping distally or palatally.

Linear Measurements

1. The lateral incisor length: Lat_Lgth
2. The Buccolingual width at the cementoenamel junction level: BL_C EJ
3. The Mesio-distal width at the cementoenamel junction level: MD_C EJ

The inclusion criteria were⁽¹⁾ at least one maxillary palatally impacted canine;⁽²⁾ CBCT image acquired prior to the start of fixed orthodontic treatment.

Exposure of the impacted canine always followed placement of fixed appliances. Patients were treated with a variety of methodologies and fixed orthodontic appliances, but alignment of the impacted canine was not achieved in all the cases.

Statistical Analysis

Comparative statistics were prepared to characterize the sample. A paired t-test was used to compare differences between palatally displaced canine and control groups. A significance level of 0.005 was used to account for multiple comparisons. Seven independent variables were included in the analysis. Can _ Sag, Can _ Cor, Lat _Sag, Lat _ Cor, Lat _ Length, BL _CEJ, MD _CEJ.

A line graph of angular and linear variables comparing the palatally displaced canine and the control group was plotted.

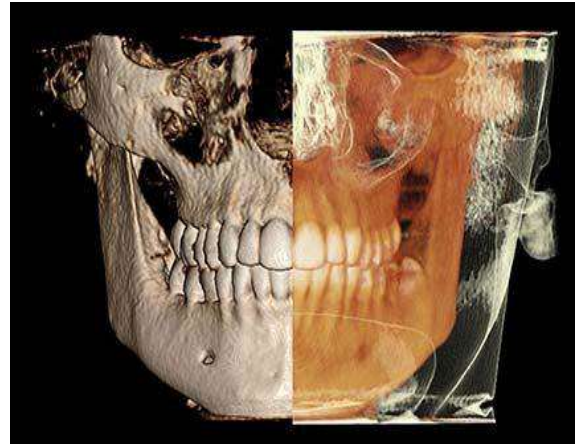


Fig. 3.3: Calculation of linear distances (frontal view)

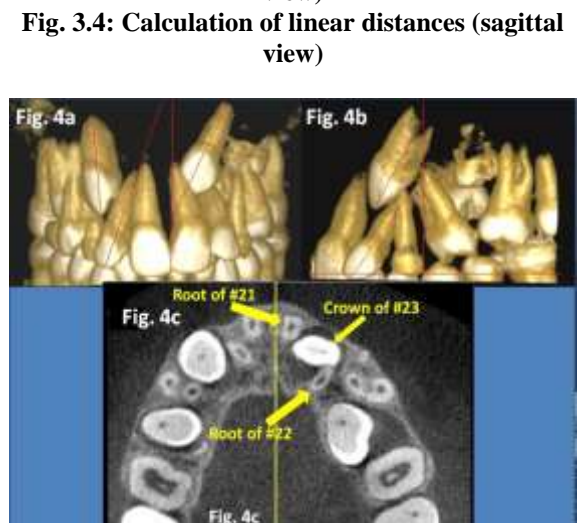
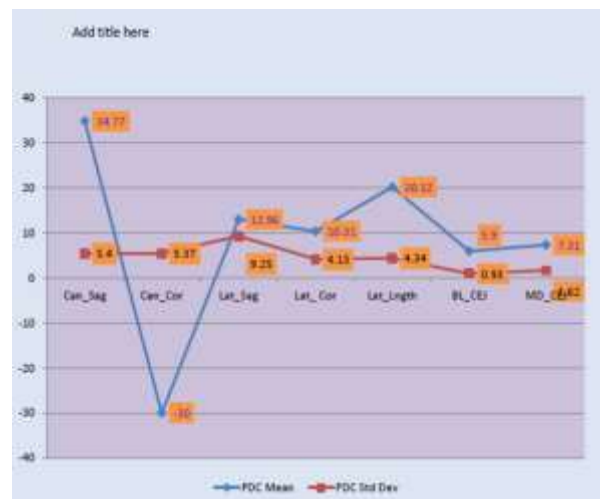

Fig. 3.4: Calculation of linear distances (sagittal view)



Line graph of angular (°) and linear (mm) Variables comparing the palatally displaced canine and the control groups

Paired t-test complete

Variable	PDC Group		Control Group		Mean Difference	Unpaired T- test
	Mean	Std Dev	Mean	Std Dev		
Can_sag	34.77	5.4	23.06	4.20	11.71	<0.0001
Can_Cor	-30	5.37	11.03	5.15	-41.03	<0.0001
Lat_sag	12.96	9.25	29.9	5.09	-16.94	<0.0001
Lat_cor	10.31	4.13	15.76	5.53	-5.45	<0.0001
Lat_lngth	25.96	4.34	23.77	5.83	2.19	0.14
Bl_cej	5.9	0.93	8.09	1.85	-2.19	<0.0001
Md_cej	7.31	1.62	11.96	3.62	-4.65	<0.0001

Results

In this study two groups were studied for linear and angular measurements of impacted maxillary canine and displaced lateral incisors. The measurements were taken for each sample using Dolphin Imaging software. The paired t-test showed significant values for both linear and angular measurements in the two groups. We analyzed 30 palatally displaced canines and 30 control canines in this study. All of the data was normally distributed. The canine variables between the two groups were significantly different ($P < 0.005$).

In this study the maxillary lateral incisors in the palatally displaced canine group tended to be more upright in the sagittal and coronal plane. The sagittal angulation of the canine and the coronal angulation of the canine were highly correlated with each other.

Discussion

The results of this study agree with most of the published literature regarding palatally impacted canine. The objective of this study was to determine the association between palatally displaced unilateral or bilateral canines and morphological features of maxillary lateral incisor on both affected and non-affected side. To achieve this, a paired t-test was performed. The descriptive statistics show that in this sample palatally impacted canines are, on average, displaced in the antero-posterior dimension and transverse dimension.

The most apparent weakness of this study was the CBCT software used in assessing the linear variable for the study. The present investigation tested the assumption that the crown-to-root angulation of lateral incisors adjacent to palatally impacted canines differs compared to lateral incisors adjacent to normally erupted canines.

The results indicated that when a canine is palatally impacted, the long axis of the adjacent maxillary lateral incisor tends to be angulated more mesially by approximately 9.25 degree in the sagittal plane and 4.13 degree palatally in the coronal plane when compared to lateral incisors with normal adjacent canines. This difference was found to be statistically significant. The mean length of the maxillary lateral incisors in the palatally displaced canine group was significantly

shorter than those in the control group by 2.19 mm ($P < 0.001$), and that of the maxillary lateral incisors in the palatally displaced canine group were significantly smaller than those in the control group, especially in buccolingual dimension, by 0.7 mm ($P < 0.001$) on average.

Morphologically abnormal maxillary lateral incisors have been associated with palatally impacted canines by numerous investigators. Some tend to support that an abnormally shaped, peg, or missing lateral incisor will cause the adjacent canine to impact by not guiding it into the correct position in the arch. This study also found that orthodontists tended to be able to “predict” the presence of a palatally impacted canine by observing the adjacent lateral incisor. When the lateral incisor was considered to be “abnormal,” 66.7% of the adjacent canines were palatally impacted. Practitioners should be aware of normal canine development, relevant investigations, and of dental anomalies such as peg-shaped lateral incisors that occur concurrently, so that early recognition and interceptive treatment can be carried out.

The presence of smaller-than-average teeth in the PDC sample supports previous reports that palatal canine impactions develop in patients with dento-alveolar arch-space adequacy. The trend for smaller incisors with PDC is a strong indicator that the entire dentition is smaller in PDC patients.

Anomalies in the anatomic form of the lateral incisor are considered to be a partial expression or a genetic predisposition of its absence, yet canine impaction is less likely to occur with a missing adjacent lateral incisor. This study also indicated that the eruption of canine is strongly influenced by the environmental factors. This association is even more marked in the case of Maxillary canine impaction and first pre-molar.

Two groups of patients were compared in this retrospective study. The control group was formed by consecutive patients referred to the department of orthodontics, V.S. Dental College for ortho treatment. The other group represented selected patients with eruption disturbances and missing maxillary permanent lateral incisor or canine. The study help us conclude that if the eruption path of maxillary permanent canine

is not followed consistently in these patients, the diagnosis of impaction is often determined only at the age when the maxillary permanent canine should erupt into the oral cavity. It was observed that female population is more frequently affected than male population.

Reviewing the literature we found many studies dealing with similar issue. The authors correlated these parameters with greater palatal space availability on the apical level of the incisors and loss of the role of the lateral incisor root as a navigator of the canine crown at its eruption. Thus, it support the guidance theory.

Summary and Conclusion

The present study undertaken to assess the association between impacted maxillary canine and maxillary lateral incisor:

1. The palatally displaced canines both unilateral and bilateral show a significant association with adjacent lateral incisors in maxilla.
2. The mean tooth angulation of the lateral incisors in patients with palatally displaced canines were significantly different compared with those of the control group.
3. It was concluded from this study that the location and orientation of palatally displaced canines were associated with changes in the angulations of the maxillary lateral incisors

Bibliography

1. Brin, Solomon, and Zilberman. Trauma as a possible canine impaction etiologic factor in maxillary. *Am J Orthod* 1993;104.
2. Dewel BF. The upper cuspid: its development and impaction. *Angle Orthod* 1949;19:79-90.
3. Bishara SE. Impacted maxillary canines: a review. *Am J Orthod Dentofacial Orthop.* 1992;101(2):159-171.
4. Moyers, R. E.: Handbook of orthodontics. 1963. Year Book Medical Publishers, Inc.
5. Shafer WG, Hine MK, Levy BM. A textbook of oral pathology. 2nd ed. Philadelphia: WB Saunders, 1963:2-75.
6. McBride, L. J.: Traction-A surgical/orthodontic procedure. *AM. J. ORTHOD.* 73: 287-299, 1979.
7. Harry Jacoby: The etiology of Maxillary canine impaction: a review. *Am J Orthodontics.* 1983, Vol 2.
8. Juanita Coulter, Andrew Richardson. Normal Eruption of the maxillary canine quantified in three dimensions. *European Journal of Orthodontics*, 1997:171-183.
9. Garn SM, Lewis AB, Kerewsky RS. Size interrelationships of the mesial and distal teeth. *J Dent Res.* 1965;44:350-354.
10. Langberg BJ, Peck S. Adequacy of maxillary dental-arch width in patients with palatally displaced canines. *Am J Orthod Dentofacial Orthop.*
11. Adrian Becker, Shaltiel Sharabi, Stella Chaushu. Maxillary tooth size variation in dentition with palatal canine displacement. *European Journal of Orthodontics.* 2002:313-318.
12. Ing Wei Liuk, Richard John Olive, Mark Griffin: Association between palatally displaced canines and maxillary lateral incisors . *Ajo-DO2012.11.025.*
13. Adrian Becker, Shaltiel Sharabi and Stella Chaushu: Maxillary tooth size variation in dentitions with palatal canine displacement. *European Journal* 2002:313-318.
14. Ing Wei Liuk, Richard John Olive, Mark Griffin: Association between palatally displaced canines and maxillary lateral incisors . *Ajo-DO2012.11.025.*
15. Adrian Becker, Shaltiel Sharabi and Stella Chaushu: Maxillary tooth size variation in dentitions with palatal canine displacement. *European Journal* 2002:313-318.
16. Basdra EK, Kiokpasoglou MN, Congenital tooth anomalies and malocclusion: a genetic link. *Eur J Orthod.* 2001;23:145-151.
17. Shafer WG, Hine MK, Levy BM. A textbook of oral pathology.
18. Butler PM. Studies of the mammalian dentition, differentiation of the post-canine dentition. *Proc Zool Soc Lond Ser B.* 1939;109:1-36.
19. Broadbent BH. Ontogenic development of occlusion. *Angle Orthod* 1941;11:223-41.
20. Peck L, Peck S, Attia Y. Maxillary canine-first premolar transposition, associated dental anomaly of genetic basis. *Angle Orthod.* 1993;63:99-109.