

## Management on Acute Symptoms of Myofascial Pain Syndrome by using Michigan Splint: A case report

Chihargo<sup>1,\*</sup>, Ricca Chairunnisa<sup>2</sup>

<sup>1</sup>Resident, Prosthodontics Residency Program, <sup>2</sup>Lecturer, Department of Prosthodontics, Faculty of Dentistry, University of Sumatera Utara, Medan, Indonesia

**\*Corresponding Author:**

Email: chihargo89@gmail.com

### Abstract

**Introduction:** Myofascial pain syndrome (MPS) is part of temporomandibular disorders (TMDs), which involve the masticatory muscles and cervical muscles around neck can also be affected. There are a lot of etiologies of MPS. Therefore, diagnostic procedures are very critical to make a proper treatment in treating TMDs. This paper aims to describe diagnostic and treatment procedures with special attention given to clinical importance of TMDs and the fabrication of Michigan splint.

**Case Report:** A clinical case with a 68-years-old female patient undergo a pain on right cheek area, especially while mouth opening for too long, there will be more pain and stiffness, also ever up to headache. On clinical examinations, there is no clicking, nor crepitus, and no pain on temporomandibular joint. However, there is pain by palpating multiple muscles around face and neck and limited jaw opening.

**Discussion:** Etiology factor of MPS on this patient was extrusion of lower right third molar leads to traumatic occlusion. Patient was treated with analgesics, muscle relaxants, fabrication of Michigan splint also occlusal adjustment. Michigan splint is also known as stabilization splint with cuspid rise and increasing the occlusal vertical dimension by the amount thickness of occlusal part of the splint, which is mostly indicated for patient with TMDs of arthrogenic/myogenic origin and nocturnal bruxism.

**Conclusion:** There are several ways which participate in management of TMDs. The occlusal splint may provide behavioral effects about the position, function and parafunction of the mandible as well as placebo effect.

**Keywords:** Temporomandibular disorder, Myofascial pain syndrome, Michigan splint, Stabilization splint.

### Introduction

Temporomandibular disorders (TMDs) is considered the most common source of orofacial pain of a non-dental origin and constitutes a heterogeneous group of conditions that affect the temporomandibular joint (TMJ) and/or masticatory muscles.<sup>(1)</sup> The American Academy of Orofacial Pain (AAOP) classification divides temporomandibular disorders broadly into muscle-related TMDs (myogenous), and joint-related TMDs (arthrogenous).<sup>(2)</sup> Myofascial Pain Syndrome (MPS) is one of the most common main complaints on the patient, which primarily involves jaw muscles, sometimes cervical muscles are affected as well.<sup>(3)</sup>

MPS is characterized by regional pain originating from hyperirritable spots located within taut bands of skeletal muscle, known as myofascial trigger points (MTrPs).<sup>(4)</sup> Several studies have said that MTrPs may indeed be significantly caused headache, sore around neck or even pelvic pain.<sup>(5)</sup> The precise etiology of MPS is not fully understood.<sup>(3)</sup> However, direct or indirect trauma, spine pathology, exposure to cumulative and repetitive strain, postural dysfunction, and physical deconditioning may contributes it.<sup>(3,4)</sup>

Several treatment methods for TMDs have been used, including occlusal splints, physiotherapy, relaxation therapy, pharmacological interventions as well as educational and behavioural counseling. Conservative treatment also has been used, includes soft diet, physical therapy, occlusal adjustment, analgesia

and medication, such as NSAIDs, painkillers, and tranquilizers.<sup>(1,3)</sup>

Splint therapy has been a preferred modality for the management of TMDs since the 1960s, and many practitioners use splints as a primary care technique for patients with TMDs.<sup>(6)</sup> However, the efficacy remains uncertain and the actual mechanism of action remains debatable. Most occlusal splints are relatively simple to make, i.e. chairside, in the clinic using a vacuum pressure method, or by a dental technician following impressions and a registration of the jaw relationship.<sup>(7)</sup>

There are many types of occlusal splints which are recommended for treatment of TMDs, but there are two types of occlusal splints are most commonly used, such as stabilization splint and reposition splint. Stabilization splint is also called as muscle relaxation splint because it's been used for the purpose of reducing muscle pain.<sup>(8)</sup> Michigan splint (occlusal bite plane stabilization splint) by Ramfjord and Ash is a splint covering all the teeth in the jaw, enabling antagonistic contacts on the flat planes according to occlusal concepts of freedom in centric position.<sup>(9)</sup> The splint should be fabricated by an experienced team consisting of the dentist and the laboratory technician to avoid any discomfort to the patient. TMDs are very often associated with many systemic diseases, such as rheumatoid arthritis, multiple sclerosis, myasthenia gravis, Parkinson's disease, drug-induced parkinsonism, ischemic stroke or inflammatory bowel diseases. Therefore, a thorough patient history

during diagnostic procedure should be collected before the active functional treatment starts.<sup>(10)</sup>

This paper aims to describe diagnostic and treatment procedures with special attention given to clinical importance of TMDs and the fabrication of Michigan splint.

### Case Report

A 68-year old female patient was referred to Prosthodontic's Clinic of Dental Hospital at Faculty of Dentistry, University of Sumatera Utara, with the complaint of pain on the lower right cheek, especially when opening the jaw for too long, there will be more pain and stiffness also ever up to headache. Patient had tried to take some painkillers, but the pain only could be relieved for few hours. Patient had experienced this condition for approximately a month. Patient also had a bad habit such as often chewing on the right side.

Patient was asked some few questions that are based on the Research Diagnostic Criteria for Temporomandibular Disorders (RDC/TMD).<sup>(11)</sup> It was aimed to know the medical history of TMJ in order to help classify the types of TMDs during examinations of muscles around the face and neck, also TMJ.

Extra-oral examination showed symmetrical face shape (Fig. 1). Extra-oral examination on muscles, i.e. masseter muscle, temporal muscle, temporal tendon, sternocleido-mastoid muscle, splenius capitis muscle, and trapezius muscle which are associated with TMDs, are recorded with scores based on the criteria of DC / TMD:<sup>(12)</sup>

0: no pain

1: mild pain

2: moderate pain

3: severe pain



**Fig. 1: Profile of the frontal face shows a symmetrical face**

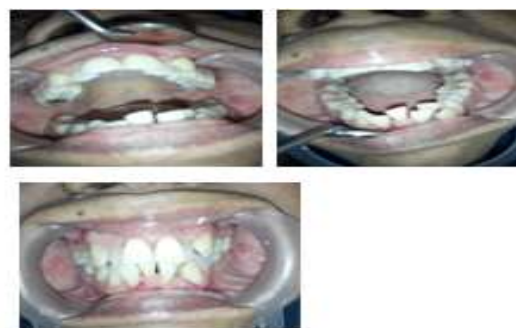Examination of functional manipulation was also conducted, i.e. a maximum mouth opening with and without pain, lateral movements, protrusive movement; midline shifting when maximum mouth opening. Afterwards, examination of TMJ was conducted, such as intra-auricular palpation, extra-auricular palpation;

examination of joint sounds, and as the result are shown in Table 1.

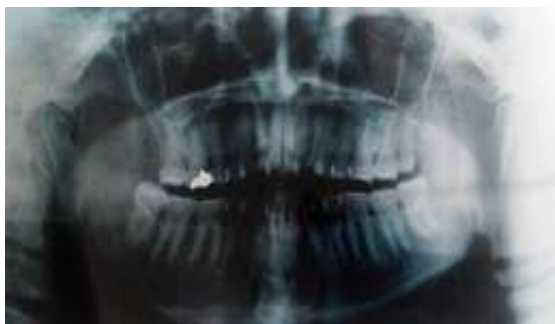**Table 1: Results on examinations of muscles and functional manipulation which are related on TMDs, as well as the examination on TMJ**

Examination	Region	
	Right	Left
Temporal	Ant: 0 Med: 1 Post: 0	Ant: 0 Med: 0 Post: 0
Temporal Tendon	2	0
Masseter	2	0
Posterior Region of Cervical Neck	1	0
Sternocleido-mastoideus	0	0
Splenius Capitis	1	0
Trapezius	0	0
Maximum Mouth Opening without Pain	35 mm	
Maximum Mouth Opening with Pain	43 mm	
Lateral Movements	4 mm	7 mm
Pain on TMJ	-	-
TMJ Sounds	-	-
Headache	-	-
Tinnitus	-	-
Occlusion	Angle Class I (Normal) with extrusion on 48	
Mid-Line Shifting of Mandible while Maximum Mouth Opening	Normal, but there was inconsistent of deviation/deflection while mouth opening and closing.	

On Intra-oral examination and panoramic radiography analysis, patient did not undergo any tooth loss, except there was congenital missing (hypodontia) of 18; extrusion on 48; superficial caries on 17, 37, 38, 48; amalgam filling on 16; and several crowded on anterior teeth; also Angle Class I malocclusion. (Fig.2a, 2b)



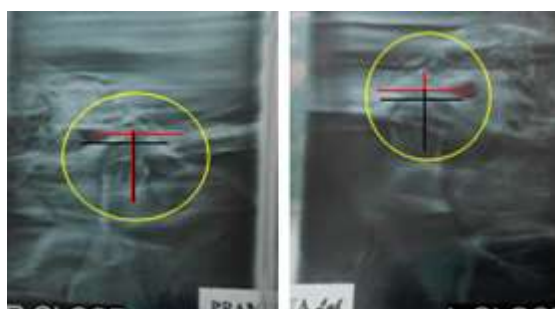**Fig. 2a: Intra-oral condition on maxilla and mandibula**



**Fig. 2b: Panoramic radiograph**

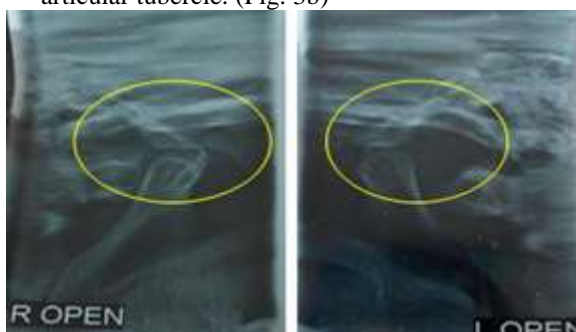
On examination of TMJ radiograph, it can be seen that:

1. While mouth closing, the mandibular condyle positions on the right and left side were in the glenoid fossa with concentric relative position. (Fig. 3a)



**Fig. 3a: TMJ Radiography while mouth closing**

2. While mouth opening, the mandibular condyle positions on the left and right were at the anterior of articular tubercle. (Fig. 3b)



**Fig. 3b: TMJ Radiography while mouth opening**

Anatomic impressions were done by using alginate and casted for 2 times to get a study casts and working casts.

Based on the above examinations results and associated them with RDC / TMD, diagnosis of TMDs was obtained as: Myofascial Pain Syndrome (MPS) with limited mouth opening et causa occlusal factor, i.e. there was extrusion on 48 because of congenital missing (hypodontia) on 18, also patient's bad habit such as often chewing on the right side. It is based on the pain from palpation of facial muscles, especially on the right side of masseter muscle, temporal muscle, temporal tendon,

posterior cervical neck muscle, and splenius capitis. There was no pain on TMJ during palpation, also no joint sounds such as clicking or crepitus while mouth opening and closing. There was inconsistent of deviation / deflection during mouth opening and closing. There was protective co-contraction / muscle splinting due to occlusion changes which was characterized by the extrusion on 48 because of hypodontia on 18. This caused indirect trauma due to cumulative and repetitive exposure of tension exposure. There was limited maximum mouth opening without pain during measurement on incisal range (35 mm), which was below normal ( $N > 40$  mm).

Preliminary treatment which was known as the first phase of treatment was given to the patient, such as:<sup>(12,13)</sup>


1. **Communication:** Explanation to patient about having a reversible TMD that may be associated with bad habits, such as often chewing on right side and the patient is suggested to change this habit, also a tooth extrusion.
2. **Physical therapy:** The treatment was done alone at home by compressing the area of TMJ with a warm towel around 10-15 minutes continuously and at least up to 3 weeks; massage around the facial muscles which was previously applied with cream containing methyl-salicylate; exercise in mouth opening and closing slowly without any deviation / deflection in front of the mirror.
3. **Treatment by medicines:** Patient was given prescription drugs such as analgesics, anti-inflammatory (Non Steroid Anti-Inflammatory Drugs / NSAIDs), and muscle relaxant drugs.

Physical therapy and drug treatment as described above suggested to the patient to be done regularly until the fabrication process of occlusal splints was completed and ready to be fitted on the patient.

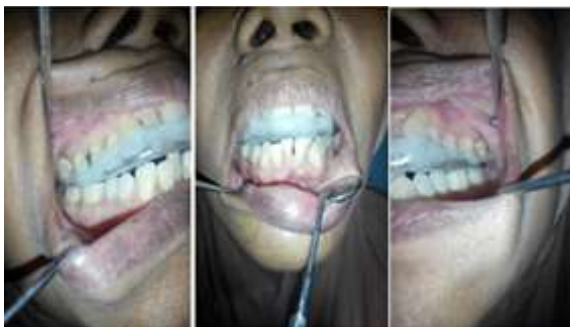Michigan splint (splint stabilization) was chosen for this case, because there was pain on facial muscles so that relaxation process of the facial muscles was necessary; there was no pain on TMJ during examination; and the absence of joint sounds. The procedure of making Michigan splint (splint stabilization) which was also the first phase of treatment, as follows:

1. Taking bite wax registration by increasing the occlusal bite wax according to patient's free way space (2-4 mm), then the patient was instructed to bite in centric relation position
2. Survey on the working casts in order to get the height contour of teeth that will be waxed up also areas that need to be blocking out. (Fig.4a)
3. Mouting the working casts along with bite wax registration into articulator semi-adjustable.
4. Wax up was done on the maxilla until it covered the height contour of teeth according to survey results so it would be more aesthetic and retentive and did not exceed the gingival margin which would cause irritation.

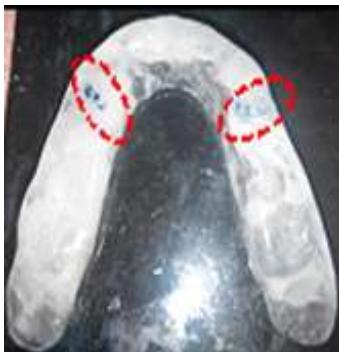5. Processing Michigan splint with heat polymerized translucent acrylic resin.
6. Insertion of splint, by checking : (Fig.4b)
  - a. Adaptation and retention
  - b. Thickness in accordance with the free way space
  - c. Occlusal contacts during centric and eccentric movements with the concept of canine guidance occlusion. (Fig. 4c)



**Fig. 4a: Result of surveying the teeth contour of teeth in purposes for wax up and blocking out areas**



**Fig. 4b: Michigan splint was inserted on patient maxillary**



**Fig. 4c: The concept of canine guidance occlusion was seen on the surface of Michigan occlusal splint**

The patient was instructed to come for the first control (a week after the insertion of Michigan splint), then was examined about complaints during splints wear, such as:

1. Examination on the muscles which previously had complaints (masseter, medial and lateral pterygoid, temporal, temporal tendon, posterior cervical neck, splenius capitis). Results showed that the spasms were reduced but there was still pain.
2. Examination on deviation/ deflection of the mandible while mouth opening and closing were still not consistent.

The patient was re-educated on the importance of physical therapy at home. At the secondary control:

1. Examination on the muscles which previously had complaints showed that the spasms and pain had been more reduced.
2. Examination on deviation/ deflection of the mandible while mouth opening and closing was quite consistent.

The second phase of treatment was done, such as occlusal adjustment on 48 which was extruded, in this case, the patient refused to do an extraction of 48. The next control will be done continuously at least once every two weeks until the complaint is resolved and splint is used for 4-6 months, any time, except while eating.

## Discussion

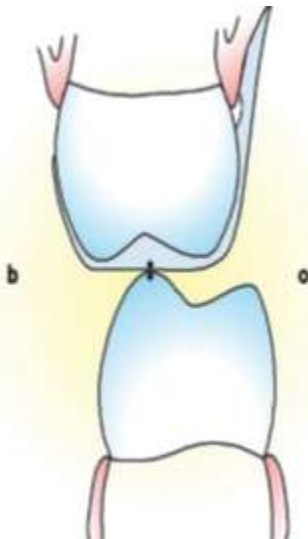
Muscular pain or tenderness in and around the joint area, excessive posturing of the mandible and occlusal disharmonies, using the jaws as a method of releasing emotional tension are some of the supposed causes of MPS. MPS is the most common cause of musculo-skeletal pain in medical practice and should be suspected in all chronic pain patients.<sup>(3)</sup> Hyperactivity of the masseter muscles and constant activity of the anterior temporal muscles even when the mandible is in the resting position is a common characteristic among individuals with sleep bruxism and TMDs. Such individuals exhibit reduced blood flow to the masticatory muscles due to vasoconstriction from muscle hyperactivity, which impedes the transport of nutrients and metabolites and can cause the build-up of by-products, thereby triggering pain.<sup>(1)</sup>

Many therapies can be done to overcome the symptoms of TMDs, which are reversible or irreversible, surgical and non-surgical. Occlusal splint is the treatment of choice, because it is reversible, non-invasive, and less expensive than other treatments.<sup>(8)</sup> Occlusal splint therapy can lead to a reduction in fatigue of the masticatory muscles, as demonstrated in a study by Zhang et al. (cited from Gomes CAFP et al., 2014), who found electromyographic changes in the masticatory muscles following occlusal splint therapy employed for the same period of time as that used in the present study.<sup>(1)</sup> Initial non-specific treatment of TMDs can be realized by a Michigan splint, according to Ramfjord and Ash, which was developed at Michigan University (USA) with the object of treating dysfunction of the TMJ and muscle, and control of bruxism. It

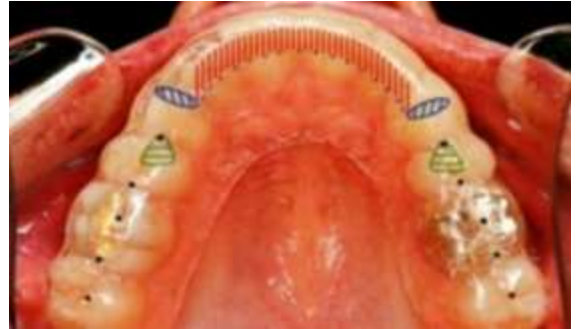consists of a bite splint with flat surfaces on which occlusal stability of the dental arches is ensured.<sup>(14)</sup>

Michigan splint is fabricated with cuspid rise and freedom in centric by a space of 0.5-1.0 mm on the splint plane. Centric relation serves as a therapeutic position which stabilizes the mandible in occlusal relations, wherein the habitual mandibular position is often identical to the centric position in TMJ.<sup>(9)</sup> The flat surfaces of the splint create contact between the dental arches by covering all the teeth, in order to avoid their movement, and growth and movement of the splint from its base. Occlusal contacts are achieved between the working cusps of all the teeth and the flat surfaces of the splint. In this way, free movement in the centric relation is ensured in the retral contact position (RCP).<sup>(14)</sup>(Fig. 5a)

During occlusal movements, the concept of canine guidance (Fig. 5b) is realized by planes of the splint in the canines region, whereas the interference, hyper balance and balance contacts between other teeth and splint plane are avoided. Indications for Michigan splint are as follows: TMDs of arthrogenic and/or myogenic origin, management of nocturnal (sleeping) bruxism and uncontrolled parafunction during the day, maintaining of centric relations as a precondition to extensive prosthodontic restoration in patients with painful and stiff masticatory muscles or limited mandibular movements, and as a means of differential diagnostics of TMDs with respect to other ailments with similar symptoms (orofacial and craniocervical pain, tension headache, secondary tinnitus, etc.)<sup>(9)</sup>



**Fig. 5a: Antagonists are supported by working cusps of the posterior teeth on the flat occlusal plane of the splint (b, buccal; o, oral)<sup>(9)</sup>**



**Fig.5b: Maxillary stabilization splint; the occlusal surface of the splint is made in flat surfaces. Ideally, the posterior occlusal surfaces contact the tip of the functional cusp of the opposing teeth<sup>(8)</sup>**

A recent paper by Goddard et al. (cited from Klasser GD et al., 2009) summarizes these developments in the placebo field and presents implications for the management of TMDs patients. Dao and Lavigne (cited from Klasser GD et al., 2009), in a review paper regarding the use of occlusal splints, commented that despite their lack of true efficacy, splints should be used as a treatment modality for some subgroups of TMDs patients because they are “effective” treatments (that is, they produce positive subjective responses), and they are harmless when properly used. Obviously, this implies that as long as clinicians stay in the domain of conservative and reversible care, there will be a variety of other effective treatments available in addition to occlusal splints that are likely to be helpful in treating their TMDs patients. Combined with cognitive-behavioral education of patients and an awareness of important psychosocial factors (especially in chronic TMDs patients), this approach should lead to “effective” treatment protocols and the avoidance of aggressive ones.<sup>(15)</sup>

## Conclusion

There are several ways which participate in management of TMDs. However, generally in the treatment of TMDs, the principle of non-invasive and reversible treatments are preferred.

The occlusal splint therapy may provide behavioral effects of self-consciousness (cognition) about the position, function and parafunction of the mandible as well as placebo effect.

## Reference

1. Gomes CAFF, Hage YE, Amaral AP, Politti F, Gonzalez DAB. Effects of massage therapy and occlusal splint therapy on electromyographic activity and the intensity of signs and symptoms in individuals with temporomandibular disorder and sleep bruxism: a randomized clinical trial. *Chiropractic Manual Therapies*. 2014. 22:43.
2. Kirov DN, Krastev DS. Efficacy of stabilization splint in management of myogenous temporomandibular disorders. *Int J Sci Res*. 2014;3(10):950-3.

3. Agrawal B, Somkuwar K. Treatment of myofascial pain dysfunction syndrome in an edentulous patient: A case report. *Ppl J Sci Res.* 2011;4(1):43-6.
4. Desai MJ, Saini V, Saini S. Myofascial pain syndrome: A treatment review. *Pain Ther.* 2013;2:21–36.
5. Simons DG, Dommerholt J. Myofascial pain syndromes-trigger points. *Journal of Musculoskeletal Pain.* 2004;12(2):45-58.
6. Nagata K, Maruyama H, Mizuhashi R, Morita S, Hori S, Yokoe T, Sugawara Y. Efficacy of stabilisation splint therapy combined with nonsplint multimodal therapy for treating RDC/TMD axis I patients: a randomised controlled trial. *J Oral Rehabilitation.* 2015;42:890–9.
7. Jokstad A, Mo A, Krogstad BS. Clinical comparison between two different splint designs for temporomandibular disorder therapy. *Acta Odontologica Scandinavica.* 2005;63:1–9.
8. Chairunnisa R, Kurnikasari E. Review of occlusal splints for the treatment of temporomandibular joint disorders. *Dentofasial J Ked Gigi.* 2013;12(1):38-43.
9. Badel T, Kocijan SS, Lajnert V, Dulčić N, Zadavec D. Michigan splint and treatment of temporomandibular joint. *Medicina Fluminensis.* 2013;49(2):112-20
10. Drobek W, Paradowska A, Kawala B. Use of lower Michigan splint: Case Report. *Dent. Med. Probl.* 2010;47(2):251–6.
11. Schiffman EL, Ohrbach R, Truelove EL et al. Diagnostic Criteria for Temporomandibular Disorders (DC/TMD) for clinical and research applications: Recommendations of the international RDC/TMD consortium network and orofacial pain special interest group. *J Oral Facial Pain Headache.* 2014;28(1):6–27.
12. Okeson JP. Management of temporomandibular disorders and occlusion. 6<sup>th</sup> Edition. Philadelphia: Mosby Elsevier. 2008:164-404.
13. Wright EF. Manual of temporo-mandibula disorders. 2<sup>nd</sup> Edition. Singapore: Wiley-Blackwell. 2010:37-257.
14. Badel T, Pandurić J, Kraljević S, Dulčić N. Initial treatment of prosthetic patients with a Michigan splint. *Acta Stomatol Croat.* 2003;37(2):207-10.
15. Klasser GD, Greene CS. Oral appliances in the management of temporomandibular disorders. *Oral Surg Oral Med Oral Pathol Oral Radiol Endod.* 2009;107(2):212-23.