

## Surgical retrieval of a separated instrument from the peri apical region aided by packing the defect by platelet rich fibrin: A case report

Jayakanth K<sup>1,\*</sup>, V. M. Mohammed Sagir<sup>2</sup>, Biju P Babu<sup>3</sup>, Kennet J Chirayath<sup>4</sup>, Sowmya Balakrishnan<sup>5</sup>

<sup>1,5</sup>Assistant Professor, <sup>2</sup>Professor and HOD, <sup>3,4</sup>Professor, <sup>1-4</sup>Dept. of Conservative Dentistry & Endodontics, <sup>5</sup>Dept. of Prosthodontics, Royal Dental College, Chalissery, Kerala, India

**\*Corresponding Author: Jayakanth K**

Email: jkroyalendo@gmail.com

### Abstract

Separated instrument is an unexpected procedural mishap often encountered in day today clinical practice. A separated instrument beyond the periapical region mandates the retrieval by surgical means. This article is a case report describing the surgical retrieval of a separated instrument from the periapical region which was aided by the application of Mineral trioxide aggregate for the endodontic management and application of Platelet Rich Fibrin (PRF) for promoting the regeneration potential of the periapical rarefaction.

**Keywords:** Platelet Rich Fibrin, Mineral trioxide aggregate (MTA), Regeneration, Growth factors, Separated instrument.

### Introduction

Healing of periapical lesions has been a major concern for clinicians dealing with endodontic surgery cases.<sup>1</sup> Many of the cases reported to endodontic clinics often requires a surgical management of an associated periapical defect.<sup>10</sup> The main goal of a periapical surgery procedure is the complete elimination of the ongoing periapical pathology and also the healing of the periapical lesion and the regeneration of the periapical bone at the periapical surgery site.<sup>2</sup> The present case report describes the surgical retrieval of a fractured endodontic instrument followed by the application of Mineral Tri-oxide aggregate for the endodontic management followed by the application of platelet rich fibrin for the regeneration and repair of periapical defect.

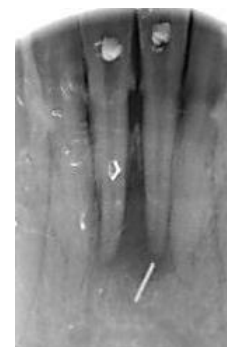
### Platelet Rich Fibrin (PRF)

PRF is a second generation platelet concentrate which is developed as a modification to overcome the shortcomings of its predecessor Platelet Rich Plasma (PRP).<sup>4,6</sup> It was introduced by Choukroun et al in France and it could eliminate the risks of using a bovine thrombin which included life threatening coagulopathies and it is more safe as the preparation of PRF does not include any chemicals or anti-coagulants.<sup>3,4</sup> PRF is a massive collection of platelets entangled in fibrin mesh which are separated from the patient's own blood. Studies have shown that PRF attracts growth factors like Transforming Growth Factor-beta (TGF-beta), Platelet Derived Growth Factor (PDGF) and other cytokines to the area of its application. This in turn enhances cell migration and angiogenesis there by promoting healing and tissue regeneration.<sup>5,7</sup>

### Case Report

42 years old female patient reported to the department of conservative dentistry & endodontics of our institution with a chief complaint of pain and swelling in relation to the mandibular central incisors region. On further case history taking, patient provided the history of an attempted root canal treatment on teeth no. 31 and 41, from a private dental

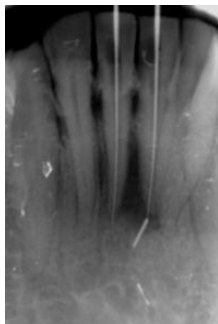
clinic 3 months ago. Further radiographic investigations carried out revealed a linear radio-opacity extending from the periapical region of tooth no. 31 which was assumed to be a separated endodontic instrument. (Fig. 1)



**Fig. 1: Pre operative radiograph**

The pre-operative RVG also revealed a radio-lucent area in between the root apices of 31 and 41 measuring around 8 mm in diameter. A final diagnosis of a failed root canal treatment with separated instrument at the periapical region of 31 was made. The treatment modalities were explained to the patient and consent for treatment was obtained.

**Procedure:** Local anesthesia with 2% lignocaine and 1:80000 adrenaline was administered. Access to the canals was re-opened in 31 and 41 and working lengths were determined with the help of 15 size k-file (Mani, Japan) by radiographic method. From the working length radiograph, it was made sure that the location of separated instrument was beyond the root apex of tooth no.31 and the surgical opening of the area is the only choice for retrieving the object. (Fig. 2)



**Fig. 2: Working length radiograph**

Thorough debriding of the root canal space was carried out in 31 and 41, cleaning and shaping of the canals were done with rotary endodontic system (NSK, Japan) and the canals were enlarged sequentially from S1 to F2 size with protaper universal files (Dentsply, Maillefer, Switzerland). During the procedure, standard irrigation protocol has been followed with alternate irrigation of 3% sodium hypochlorite (Vishal, India), 0.9% normal saline and 17% EDTA (Endo-prep RC, India), and 2% chlorhexidine gluconate (Asep-RC, India). Calcium hydroxide intra canal medicament was placed in the canals of 31 and 41 and access cavity was sealed with zinc-oxide eugenol temporary cement (cavit).

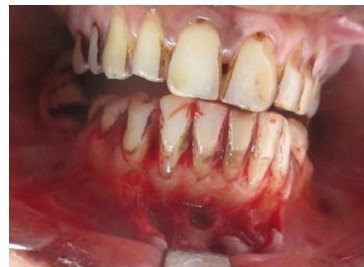**Pre-Operative Preparations:** The procedures for peri-apical surgery and the risk factors and the treatment outcome were explained to the patient. The appointment was scheduled after a week and the hemogram was obtained before the surgery and all the values were found to be within the normal limits. Complete oral prophylaxis was done by scaling procedure and subsequent use of mouth rinse with 0.2% chlorhexidine gluconate for one week.

One hour prior to the surgical procedure intra oral antisepsis was made sure with 0.2% chlorhexidine gluconate rinse and extra oral antisepsis with povidone iodine solution.

Access to the canals were re-opened and cleaning and shaping is again carried out till F2 size of protaper universal file and the above said irrigants to remove the intracanal medicament.

### Surgical Access

After administering local anesthesia, a full thickness rectangular muco-periosteal flap was reflected in the buccal aspect of 31 and 41, this was achieved by giving intra crevicular incisions extending from the distal aspect of 33 to the distal aspect of 43 and two vertical releasing incisions given at 33 and 43. Flap was retracted and after achieving proper hemostasis and irrigating the peri-apical area with copious amount of normal saline the separated instrument was visible at the peri-apical region of 31. The instrument was retrieved by a mosquito forceps. RVG was taken to confirm no fragments of separated instrument was remaining in the area. (Fig. 3), (Fig. 4).



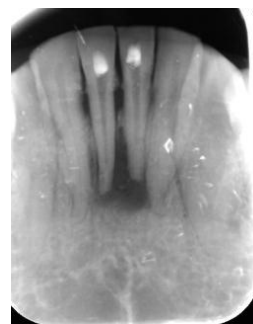**Fig. 3: Separated instrument exposed**



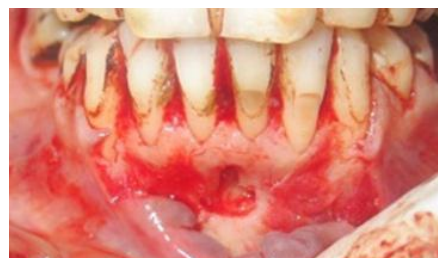**Fig 4: Instrument retrieved**

An osseous defect was visualised associated with the periapical region of 31. Complete curettage of the periapical area was done with a molt curette. The apical 3 mm of the root of 31 associated with the osseous defect was resected perpendicular to the plane of the root.

At the time of evaluating the working length RVG, the root canals of 31 and 41 were found to be having open apices and this was confirmed during the root canal instrumentation procedure. So after drying the root canals of 31 and 41 with paper points, white MTA (Proroot) was packed in the apical 6 mm area of 31 and 41 to ensure the complete sealing of an open apex. The access cavity was sealed with a temporary cement. (Fig. 5), (Fig. 6).



**Fig 5: MTA packed at apical 6mm and apicectomy done**



**Fig. 6: Bone defect after curettage**

### PRF Preparation

PRF was prepared as per the protocol described by Freymiller and Aghalo. 10 ml of intravenous blood was drawn in to a sterile tube by venipuncturing the patient's antecubital vein. No anticoagulant was added to the blood the blood sample was immediately centrifuged at 3000 rpm for 10 minutes. Following the procedure, the blood settled in to 3 layer-

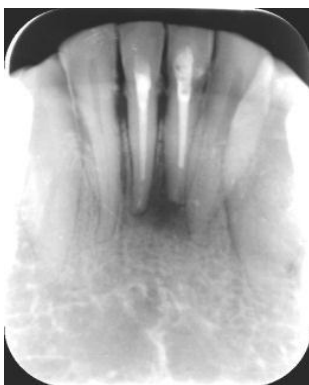1. Upper straw coloured acellular plasma,
2. Middle fraction containing the fibrin clot and
3. Red coloured lower fraction containing RBC

The upper layer is removed and middle fraction of PRF was collected. The PRF is the platelets trapped in high concentration in fibrin meshes.

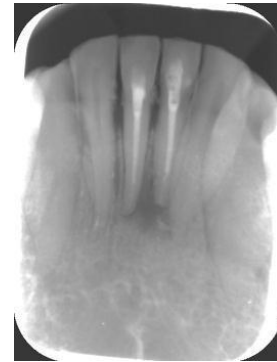

**Fig. 7: PRF prepared to match the size of the defect**

The prepared PRF was carefully cut to roughly match the size of the osseous defect and was carefully placed in the defect with a tissue forceps. The flap is carefully placed back in to position without disturbing the PRF in position. (Fig 7). Sutures were placed. One week later sutures were removed and access in to the canals reopened and the remaining portion of the root canals were obturated using AH plus sealer and the corresponding sizes of gutta-percha cones. One month and 3 months review of the patient and radiographic evaluation of the periapical area was done. The teeth were asymptomatic and the radiographs revealed the appearance of a healing lesion with sufficient amount of bone regeneration at the periapical osseous defect area. (Fig. 8). (Fig. 9)



**Fig. 8: One month follow up**



**Fig. 9: Three months follow up**

3 months later post endodontic restorations were given on 31 & 41

### Discussion

Large periapical lesions often present challenges to the choice of peripical surgery.<sup>8-10</sup> And the patients compromised medical status can complicate it further more. Platelet rich fibrin has been proved to be a boon in promoting the healing procedure. PRF has few additional advantages.

1. It's most cost effective and readily available
2. No immunologic or tissue rejection reactions involved
3. Do not require any biochemical handling of blood
4. Helps in hemostasis
5. It promotes better cell migration and proliferation process

Due to these reasons, whenever periapical surgery of large lesions is contemplated, PRF can be taken as an aid for achieving faster tissue regeneration and healing process, because it provides a benefit of local application of growth factors and host modulating agents, thereby maximizing the natural healing process of the body.

### References

1. F. H. Barbakow, P. E. Cleaton-Jones, and D. Friedman, "Endodontic treatment of teeth with periapical radiolucent reas in a general dental practice," *Oral Surg, Oral Med Oral Pathol.* 1981;51(5):552-559.
2. J. D. Bashutski and H. L. Wang, "Periodontal and endodontic regeneration," *J Endod.* 2009;35(3):321-328.
3. B. Goyal, S. Tewari, J. Duhan, and P. K. Sehgal, "Comparative evaluation of platelet-rich plasma and guided tissue regeneration membrane in the healing of apicomarginal defects: a clinical study," *J Endod.* 2011;37(6):773-780.
4. D. M. Dohan, J. Choukroun, A. Diss. "Platelet-rich fibrin (PRF): a second-generation platelet concentrate. Part I: technological concepts and evolution," *Oral Surg, Oral Med, Oral Pathol. Oral Radiology and Endodontol.* 2006;101(3):E37-E44.
5. Jayalakshmi KB, Agarwal S, Singh MP, Vishwanath BT, Krishna A, Agrawal R. Platelet-rich fibrin with beta-tricalcium phosphate-a novel approach for bone augmentation in chronic periapical lesion: a case- report. *Case Rep Dent.* 2012;2012:902858.

6. L. He, Y. Lin, X. Hu, Y. Zhang, and H. Wu, "A comparative study of platelet-rich fibrin (PRF) and platelet-rich plasma (PRP) on the effect of proliferation and differentiation of rat osteoblasts in vitro," *Oral Surg, Oral Med, Oral Pathol, Oral Radiol Endodontol.* 2009;108(5):707–713.
7. Naik B, Karunakar P, Jayadev M, Marshal VR. Role of platelet rich fibrin in wound healing: a critical review. *J Conserv Dent.* 2013;16:284-293.
8. U. Sjögren, B. Hägglund, G. Sundqvist, and K. Wing, "Factors affecting the long-term results of endodontic treatment," *J Endod.* 1990;16(10):498–504.
9. V. S. Pinto, M. L. Zuolo, J. T. Mellonig, "Guided bone regeneration in the treatment of a large periapical lesion: a case report," *Pract Periodontics Aesthet Dent.* 1995;7(2):76–82.
10. Spili P, Parashos P, Messer HH. The impact of instrument fracture on outcome of endodontic treatment. *J Endod.* 2005;31(12):845-850.

**How to cite this article:** Jayakanth K, Sagir V. M. M, Babu B. P, Chirayath K. J, Balakrishnan S. Surgical retrieval of a separated instrument from the peri apical region aided by packing the defect by platelet rich fibrin- A case report. *Int J Oral Health Dent.* 2018;4(4):249-252.