

Spontaneous intraorbital arteriovenous fistula with thrombosed varix: A rare case report

Sucheta Parija^{1,*}, Indranil Saha²

¹Associate Professor, Dept. of Ophthalmology, AIIMS, Bhubaneswar, ²Fellowship Training in Vitreoretinal Services, Dr. Shroff Eye Hospital, New Delhi

***Corresponding Author:**

Email: suchetaparija@yahoo.com

Abstract

Arteriovenous shunts in the orbit are rare acquired vascular malformations and cause of proptosis. Literature search reported only 6 spontaneous and 4 traumatic cases of intraorbital AVF. We report the clinical and radiological findings of a patient with isolated, spontaneous AVF of orbit with a thrombosed varix which is rare and its management dilemma. A 55 year old female presented with progressive axial proptosis, chemosis and loss of vision in the right eye. There was no preceding history of trauma or any systemic illness. Imaging of the brain and orbit was suggestive of an intraorbital arteriovenous fistula which had perhaps evolved spontaneously into a thrombosed varix of the right superior ophthalmic vein due to pooling of blood which explained the mass effect features. The thrombosed SOV was excised by frontal craniotomy, following which the symptoms subsided with partial restoration of vision.

Keywords: CT angiography, Orbital AVF, Proptosis, Thrombosed varix.

Introduction

An arteriovenous fistula (AVF) is a rare acquired vascular abnormality defined as a direct connection between an artery and a vein without an intermediate capillary network or nidus.^(1,2) The regional blood flow through the fistula exposes the veins to increased intraluminal pressure and varix formation. The caliber of the artery involved will dictate the type of lesion, as well as the signs and subsequent treatment. De Keizer⁽²⁾ classified different types of carotid-cavernous (CCF) and orbital AVFs. An isolated orbital AVF without dural or cavernous communication is rather rare.^(3,4) AVFs restricted to the orbit only are low-flow fistulas but induce the same ocular features as do dural and direct CCF.⁽³⁾ Usually an intraorbital AVF is acquired following trauma or tumor and it's very rare to have an AVF spontaneously.^(5,6) We report here the clinical and radiological features of a case of spontaneous intra-orbital arteriovenous fistula with thrombosed varicose superior ophthalmic vein (SOV) which was treated by direct excision.

Case Report

A 55 year old female, was referred with complaints of pain, progressive proptosis and gross diminution of vision in the right eye since 15 days (Fig. 1). She was apparently well 6 month back when she noticed intermittent self resolving episodes of protrusion of the right eye, with diminished vision, along with intermittent episodes of severe headache and vomiting. She had no history of trauma, hypertension or family history of vascular disorders. Visual acuity in the right eye was 6/60 and 6/9 in the left eye. Ocular motility of the right eye was limited in all fields of gaze. On palpation the eye was extremely tender, non-

compressible, pulsatile but no bruit was auscultated. Slit lamp examination of right eye showed dilatation of conjunctival vessels, severe chemosis, axial proptosis and posterior subcapsular cataract. Pupils of both eye was normally reacting to light. Hertel Exophthalmometry showed a 25mm proptosis in right eye and 16mm left eye. Fundus examination of both right and left eye was normal. Intraocular pressure was 24 mm Hg RE and 12 mm Hg in LE. Neurological examination revealed no deficits.

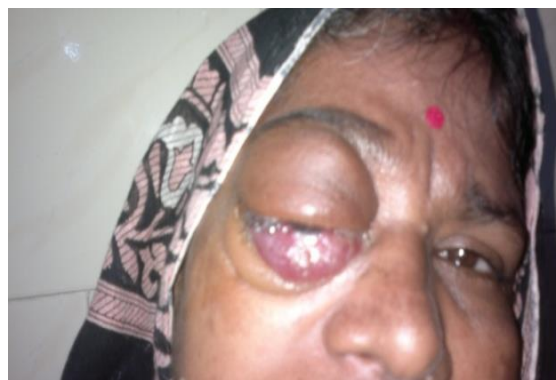

Fig. 1: Progressive axial proptosis with conjunctival chemosis of right eye

Computed tomography (CT) of brain and orbit (Fig. 2) demonstrated a nonenhancing, serpiginous, soft tissue mass within the right retrobulbar space with associated hyperostosis of superior wall of the orbit & right squamous temporal bone.

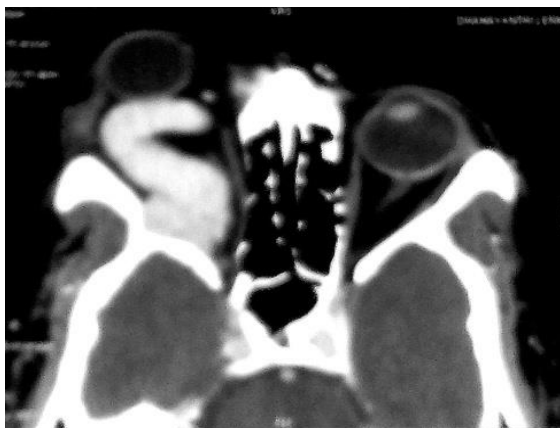


Fig. 2: Axial CT Scan features suggestive of arteriovenous fistula involving the right orbit with thrombosis of the superior ophthalmic vein causing orbital proptosis and osseous changes in the right sphenoid bone

CT angiography (Fig. 3) with 3 D reconstruction CT (Fig. 4) revealed an intraconal, serpiginous vascular lesion of size (4-6mm) filled with non enhancing thrombus which was possibly arising from right internal carotid artery (ICA) and ending at the level of the SOV. The SOV drained anteriorly into the several small tributaries with slow outflow. These findings were consistent with the diagnosis of thrombosed varicose SOV with intraorbital AVF which was confirmed by high frequency (5-7.5 MHz) B scan ultrasound with doppler.

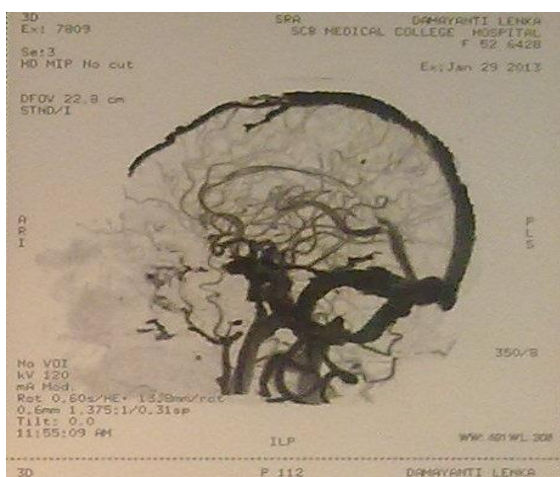


Fig. 3: CT Angiography sagittal view showing absence of flow within the right superior ophthalmic vein and drainage into the deep venous system, suggestive of thrombosis of right superior ophthalmic vein

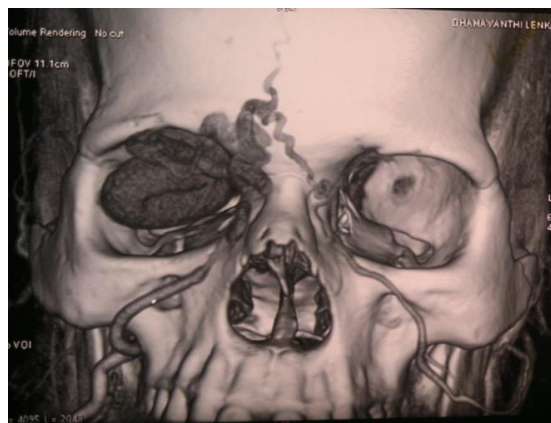
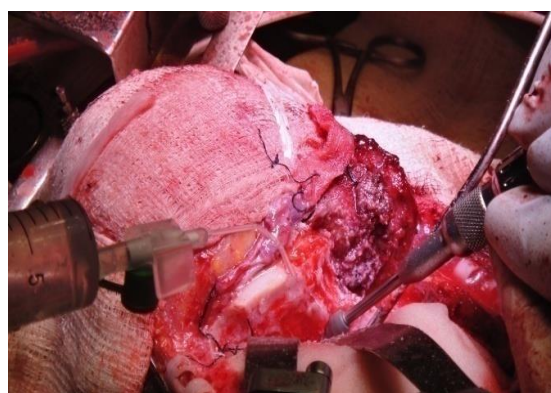
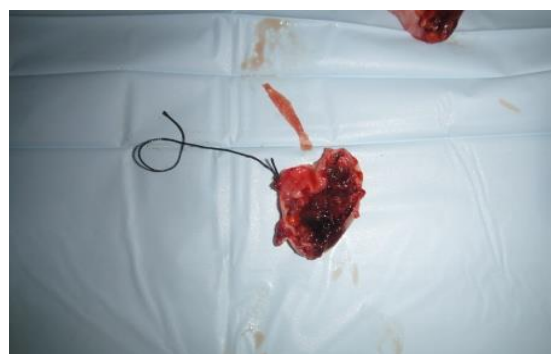


Fig. 4: 3D - CT reconstruction of face showing enhancing vascular structure (in arterial phase) of size 4-6mm, is noted in a serpiginous pattern possibly arising from right internal carotid artery. The arterial structure is seen to end at the level of the superior ophthalmic vein which is dilated and grossly tortuous of 2cm size

To combat the symptomatic lesion, an open surgical excision was planned by the neurosurgery team. Through fronto-orbital approach, the thickened thrombosed SOV was resected completely after ligation of the proximal feeding artery (Fig. 5).



A



B

Fig. 5a & b: Intraoperative pictures showing the thrombosed superior ophthalmic vein which was excised

Proptosis and ocular motility improved immediately after surgery (Fig. 6). After one month she underwent small incision cataract surgery and visual acuity is 6/18 in the right eye. She is stable with no recurrence after 6 months follow up.

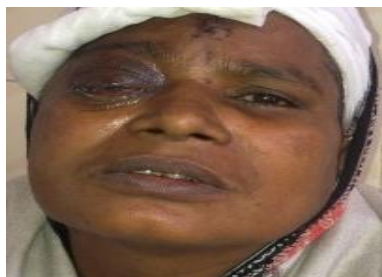

Fig. 6: Two weeks post- surgery shows reduction of proptosis and chemosis

Discussion

AVFs in the orbit are quite rare, and are part of facial arteriovenous malformations (AVMs)⁽⁴⁾ or occur after an ethmoidal fracture. Cases of spontaneous AVF without any prior history of trauma are rarely encountered⁽⁶⁾ and may arise due to a congenital ophthalmic artery aneurysm rupturing into a vein, or from progressive vessel erosion in hypertension, atherosclerosis, vascular or connective tissue disease with features of mass effect. Ohtsuka K et al.⁽⁴⁾ (1999) and Hamada J et al.⁽⁷⁾ (2006) reported cases of spontaneous AVFs without any history of trauma, similar in our case.

Orbital AVFs have hemodynamic characteristics comparable to that of orbital AVM or CCF.⁽³⁾ Increased venous pressure in the orbit and signs of orbital congestion, such as proptosis, conjunctival and retinal vessels dilatation, ocular hypertension, and dilation of the superior ophthalmic vein, can be found in all three conditions,^(1,2,4,5) as was also seen in our patient. When orbital AVF produces varix, engorgement may occur through a valsalva maneuver or similar action (e.g., bending, coughing, and straining)^(8,9) resulting in intermittent periorbital pain, proptosis, thrombosis, and hemorrhage.⁽⁹⁾ The degree of shunt, flow rate and the adequacy of external drainage of the SOV are all related to the frequency of the orbital symptoms. Even very slow flow shunts can result in severe proptosis and chemosis because of poor external drainage as seen in our case.

In an angiogram, AVFs are characterized by a single arteriovenous connection in the vascular mass. The shunt between the artery and the vein is identified by abrupt changes in the vessel caliber and/or the course of the feeding pedicle.^(7,8,9) In our patient, CT angiography revealed no evidence of a nidus; instead, a fistulus communication was found to exist between a minute artery from ICA and SOV. The role of catheter angiography is essential in evaluation and management of intraorbital AVF. Financial constraint and to

unavailability in our center, neither this nor direct carotid stick angiography could be done.

Treatment of intraorbital AVFs remains controversial and usually managed by conservative approach. Symptomatic AVF in association with thrombosed varices are only amenable to surgical excision under direct vision.⁽¹⁰⁾ Since the orbital AVF was associated with hard thrombosed SOV varix in our case, simple ligation of the feeding artery might not have been sufficient to decompress the lesion. In view of our patient's progressive symptoms, the SOV was exposed and excised surgically followed by ligation of the feeding arteries. The treatment for the AVF was effective enough to alleviate the symptoms.

Our report, suggests that orbital AVFs can occur spontaneously, with no history of trauma. A complete analysis of the hemodynamics by means of selective cerebral angiography is needed for differential diagnosis and effective management.

Reference

1. Yazici B, Yazici Z, Erdogan C, et al. Intraorbital arteriovenous fistula secondary to penetrating injury. *Ophthal Plast Reconstr Surg* 2007;23:275–278.
2. De Keizer R. Carotid-cavernous and orbital arteriovenous fistula: ocular features, diagnostic and hemodynamic considerations in relation to visual impairment and morbidity. *Orbit* 2003;22:121–142.
3. Frankefort N, Salu P, Van Tussenbroek F. Orbital arteriovenous fistula with symptoms contralateral to the arterial supply: a case report. *Bull. Soc. belge Ophtalmol* 2005;296, 63-67.
4. Ohtsuka K, Hashimoto M. Clinical Findings in a Patient with Spontaneous Arteriovenous Fistulas of the Orbit. *Am J Ophthalmol* 1999;127:736–737.
5. Naqvi J, Laitt R, et al. A Case of a Spontaneous Intraorbital Arteriovenous Fistula: Clinico-Radiological Findings and Treatment by Transvenous Embolisation via the Superior Ophthalmic Vein. *Orbit*, 2013;32(2):124–126
6. Lin CJ, Blanc R, Clarencon F, et al. Transvenous embolisation of an intraorbital arteriovenous fistula using onyx. *J Clin Neurosci* 2010;17:783–785.
7. Hamada J, Morioka M et al. Spontaneous arteriovenous fistula of the orbit: case report. *Surgical Neurology* 65 (2006) 55–57.
8. Bullock JD, Goldberg SH, Connelly PJ. Orbital varix thrombosis. *Ophthalmology*. 1990;97:251–6.
9. Shields JA, Dolinskas C, Ausburger JJ, Shah HG, Shapiro ML. Demonstration of orbital varix with computed tomography and Valsalva manoeuvre. *Am J Ophthalmol*. 1984;97:108–10.
10. Arat YO, Mawad ME, Boniuk M. Orbital venous malformations: Current multidisciplinary treatment approach. *Arch Ophthalmol*. 2004;122:1151–8.