

Intra lesional injection of triamcinolone acetonide- An aesthetic method of treating chalazion

K. Kavita¹, Mohammed Ather^{2,*}, Samra Wahaaj Fatima³

¹Assistant Professor, ²Professor, ³Junior Resident, Dept. of Ophthalmology, Sarojini Devi Eye Hospital Regional Institute of Ophthalmology, Telangana, India

***Corresponding Author:**

Email: ather11258@gmail.com

Abstract

Aim: To study the efficacy of intra lesional injection of triamcinolone acetonide in treating chalazion.

Materials and Method: This is a prospective interventional study conducted on 100 cases of chalazion at the department of Oculoplasty and orbital disease of Sarojini Devi eye hospital, during July 2013 to June 2015. 100 cases of chalazion who came to the out patient department of Sarojini Devi Eye Hospital were included in the study. Recurrent cases, cases of acute hordeolum internum, Lid malignancies, and children were excluded from the study.

Informed consent was obtained from cases selected. They were investigated for Routine surgical profile and size of chalazion measured in millimetres by a transparent ruler. Then Injection of 0.1 ml of triamcinolone was given intra lesionally into the chalazion in minor operation theatre taking all Aseptic Precautions. Cases were followed post operatively after 1st week and fourth week for reduction in size of chalazion.

Result: Out of 100 cases 80 had complete resolution, 11 had reduction in size and 9 didn't respond to treatment.

Conclusion: Intra lesional injection of triamcinolone is Aesthetic method of treating chalazion.

Keywords: Chalazion, Intra lesional injection, Triamcinolone acetonide.

Introduction

Chalazion (Meibomian cyst, Tarsal cyst or conjunctival granuloma) is a chronic non infective granulomatous inflammatory lesion caused by retained secretion leaking from the meibomian glands into adjacent stroma.¹

Chalazion is a most common lid swelling affecting either upper lid or lower lid. It is found in population of lower socioeconomic class and in population living in urban areas.² It presents as a painless nodule in 20 to 50 years old. Males are more commonly affected. Predominance could be related to more outdoor activities of males.³ Upper lid is involved more commonly than the lower lid because the upper lid contains more meibomian glands than lower lid.⁴

Morbidity associated with chalazion includes - continued inflammation which can lead to rupture of the lesion through the tarsal conjunctiva leading to granuloma formation. Progression of chalazion can lead to disfigurement of the lid. Decreased vision is because of large centrally located chalazion pressing on the cornea, causing mechanically with the rule astigmatism and acquired hyperopia.⁵

Conventional treatment of chalazion is Incision and Curettage causing stress to patient which will be followed by lid swelling because of inflammatory edema.

Materials and Methods

This is a Prospective interventional study conducted at the department of Oculoplasty and Orbital disease of Sarojini Devi Eye Hospital/ Regional institute of Ophthalmology. The study was conducted

between July 2013-June 2015. 100 cases of chalazion were included in the study. Of 100 cases selected 61 were males and 39 were females. The cases of recurrent chalazion, Lid infections, Lid malignancies and those who were having systemic disorders like diabetes and hypertension were excluded. The children below 15 years were also excluded from study. Informed consent was obtained from all patients selected for the study regarding usage of drug and also use of their photographs without revealing their identity for scientific publications. Size of chalazion was measured using a transparent ruler and documented. Routine investigations like surgical profile (RBS, CT, BT, HIV antigen, HBSAg,) were done in all patients. The patient were taken to Minor operation theatre. Eye to be treated was cleaned by povidone Iodine swab and patient was draped by sterile drape. Topical anaesthetic agent proparacaine eye drops were instilled to anaesthetise the conjunctiva. Chalazion clamp applied to the lid and 0.1 ml of injection triamcinolone acetonide 40mg/ml is loaded in Tuberculin syringe was injected intra lesionally using 26 gauge needle. Chalazion clamp removed and light pressure applied over the lesion to stop bleeding. Pad and bandage applied to the eye. Patient prescribed topical antibiotic drop like ciprofloxacin 4 times daily and asked to report after one day. On post injection visit patients were examined on slit lamp for any corneal epithelial defects by staining with 2% Fluorescein sodium strip. Then patient was followed up after a week and after 4 weeks. During these visits size of chalazion was rechecked and compared with pre-treatment status in addition to slit lamp examination. All patient got their IOP recorded

during post treatment visits. All patients were photographed during post treatment visit for reduction in size and resolution of chalazion.

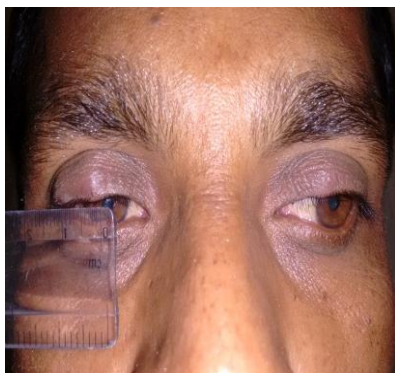

Fig. 1: Before Injection

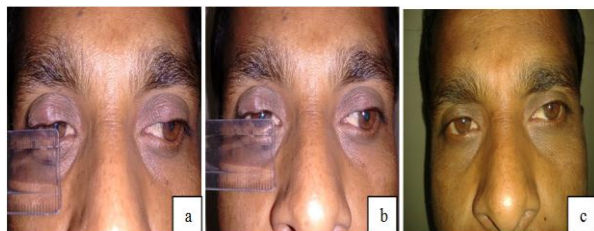

Fig. 2, a: After 1 day, (2, b: After 1 week, (2, c: After 4 weeks

Results

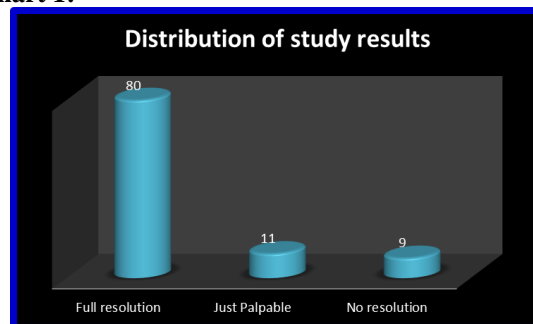
100 patients having chalazion of either upper lid or lower lid were included. 61 were males and 39 females. Age group varied from 20-50 years of age.

Table 1: Distribution of age group in the study population

Age group	No. of patients	Percentage
20-30 years	62	62%
31-40 years	33	33%
41-50 years	5	5%

After fulfilling the study criteria 40mg/ml of 0.1 ml of injection triamcinolone (ie 4mg of triamcinolone) was given intra-lesionally on the conjunctival side and followed up on day one and after first and fourth week. No major and minor side effects of injection triamcinolone like raised IOP or corneal erosion were noted. No second injection was planned in our study. 80 patients have shown full resolution of the lesion at the end of 4 weeks, only after one injection. 11 patients had reduction in size of chalazion and lesion became invisible but felt on palpation. 9 patients did not respond to one injection of triamcinolone.

Chart 1:



Discussion

Standard treatment for chalazion is Surgical, ie Incision and curettage of lesion under local anaesthesia.⁶ Intra lesional injection of triamcinolone acetonide has been tried successfully all over the world.⁷

Pavic-Astalos J et al⁸ had treated 37 cases of primary and recurrent chalazia with intra lesional injection of triamcinolone and 24 control were given Injection of NaCl. Group I had shown resolution in 35 cases.

GJ Ben Simon et al⁹ had studied 155 primary and recurrent cases of chalazia by intra lesional injection of triamcinolone. 93 patients (60%) resolved in one injection. 31 patients (20%) received second injection and got resolution. 31 patients didn't responded to injection were treated by Incision and curettage. A. Panda et al¹⁰ & AA Kothari¹¹ also reported same results with intra lesional triamcinolone.

Md. Akhtaruzzama et al¹² compared efficacy of intra lesional triamcinolone with surgical I&C. Group I consist of 54 patients who received intra lesional injection of triamcinolone had 88% success rate. Group II of 42 patients who received I & C had success of 92%. The difference is statistically insignificant.

In present study 100 cases were given one injection of intra lesional triamcinolone. 80 patients had shown complete resolution after 4 weeks. 11 patients had shown partial resolution to the extent that chalazion was not visible but felt on palpation. 9 patients didn't responded to intralesional injection of triamcinolone were surgically treated by Incision and curettage.

Conclusion

Intra lesional injection of triamcinolone is equally effective in treating chlazion as surgical incision and curettage. It is more aesthetic method of dealing with chalazion. The intra lesional injection of triamcinolone is more useful in cases of multiple chalazia involving both lids and both eyes. This method is also effective and safe for treating chalzion near medial canthus and chalazion close to canaliculi. Surgical treatment of such chalazion can lead to canalicular damage.

Financial Interest: Nil

References

1. M.Yanoff & J Duker, Ophthalmology, 4th edition, Elsevier Saunder page1304.
2. A K Khorana 6th edition, Jaypee Publishers page 368.
3. Wolff's Anatomy, 8th edition page 30.
4. Nemet AY et al, associated morbidity of chalazia, Cornea 2011, Dec(12):1376-81.
5. L C Dutta, Modern Ophthalmology, 3rd edition, Jaypee Publishers pages 612-613.
6. Jack J Kanski, Clinical Ophthalmology, 7th edition, Elsevier page 4.
7. Pavic-Astalos J et al, Intralesional injection of Triamcinolone acetonide for Chalazion, Acta clinical Croatia, 2010 March, 49(1) pg 43-48.
8. G J Ben Simon et al, Intra lesional triamcinolone acetonide for primary and recurrent Chalazion: Is it really effective, Ophthalmology, 2005 May 112(5), Pg: 913-917.
9. Anita Panda et al, Intra lesional Corticosteroid therapy for Chalazion, IJO,1987,35(4)Pg:183-185.
10. A A Kothari et al, Intra lesional Kenacort in Chalazion, Current Indian Eye research,2016: 3(1):Pg 26-28.
11. Mohammed Akhtar uz zama et al, Efficacy of Intralesional Injection of Triamcinolone in the management of Chalazion, RCMC journal, 2011 July, Vol1(11) Pg 1-6.