

A prospective analysis of the causes and characteristics of uveitis patients in a private practice set up in an urban south Indian population

Vijayan. S¹, Manoj Vasudevan^{2,*}

¹Senior Resident, ²Director and Consultant Eye Surgeon, Dept. of Ophthalmology, ¹Government Sivagangai Medical College, Tamil Nadu, ²Janu's Eye Clinic, Chennai, Tamil Nadu, India

***Corresponding Author:**

Email: manojvasudevanms@gmail.com

Abstract

The pattern of uveitis is influenced by a number of geographic, demographic and racial factors. Collaborative studies between different regions would be of help in establishing etiology and pattern of uveitis. A few studies on the pattern of uveitis from southern¹⁻³ central and northern⁴ India have been reported in literature. In this paper we have highlighted the causes and characteristic pattern of uveitis seen over a period of 8 years in urban south Indian population of different age groups and gender seen at a private practice set up and also emphasize the difficulties faced by the treating physician to diagnose, treat and follow up these individuals.

Keywords: Uveitis, Granulomatous, Non-granulomatous, Traumatic, Infective, Anterior, Intermediate, Posterior, Pan-uveitis.

Introduction

Uveitis is intra ocular inflammatory disease of the eye with several etiological and pathological causes. These also vary in different population based on ecological, socio-economic and racial variations of the population studied. There is also influence from the epidemiological and geographical distribution of specific uveitic entities. The etiology varies between age and gender as well. "Uvea" means bunch of grapes which refers to inflammation in general. The inflammation is defined as acute if they are present for less than three weeks or chronic if present for more than three weeks and recurrent when two or more similar episodes occur with a disease free period. Anterior uveitis is defined as inflammation of iris (iritis) or iris with pars plicata of ciliary body (iridocyclitis). Intermediate uveitis is defined as inflammation of the pars plana region of the ciliary body. Posterior uveitis is defined as inflammation of the choroid and the vitreous. Pan uveitis is defined as, when all the three structures comprising the iris, ciliary body and the choroid of the eye are involved simultaneously. Granulomatous uveitis is defined as when the uveitis presents with large mutton fat like keratic precipitates and iris nodules. A diagnosis of Fuchs heterochromic iridocyclitis (FHIC) is made based on following clinical features:

1. Small to medium-sized keratic precipitates involving the whole endothelial surface.
2. A chronic inflammation in anterior chamber, usually $\leq 2+$ according to SUN criteria¹.
3. Diffuse iris stromal atrophy with or without heterochromia.
4. Lack of posterior synechiae unless there was a history of ocular surgery.
5. Absence of snow banks or choroidal/retinal infiltrates despite the presence of vitreous cells.

Materials and Methods

All patients with a diagnosis of uveitis seen at our clinic between August 2008 and July 2016 were included in the study and analyzed prospectively. Our material mostly included outpatient uveitis cases. A standard clinical proforma for uveitis with the patient profile and clinical findings including the uveitis characteristics, specific ocular cause and systemic association if any identified clinically or suspected from history or already patient is on treatment for that disease after a confirmatory diagnosis by laboratory investigations were documented for analysis. Patients were classified according to current International Uveitis Study Group (IUSG) classification based on the localization of intraocular inflammation.² Ocular findings were analyzed in each patient by external examination using a diffuse torch light, slit-lamp biomicroscopy, aplanation tonometry if necessary and indirect ophthalmoscopy (IDO) with scleral depression in full dilatation. Fundus examination was done with IDO using 20-diopter (D) lens and slit-lamp using 90-D lenses. Ancillary tests included B scan ultrasound, fundus fluorescein angiography in selected cases and tailor made laboratory investigations in each patient based on the clinical findings and a probable clinical differential diagnosis. Routine investigations were done for all patients except for those with traumatic uveitis which included radiography of chest, complete blood count, erythrocyte sedimentation rate (ESR), mantoux test, VDRL, and peripheral smear. Specific investigations were done based on the clinical picture of the condition which included radiography of the lumbo sacral region with the sacro-iliac joints, Magnetic resonance imaging of the lumbo-sacral region with sacro-iliac joints, High resolution computed tomography (HRCT) of the chest, serology for HIV, antibody titres of IgG and IgM antibodies for toxoplasmosis, herpes simplex and zoster, toxocariasis,

cytomegalovirus, syphilis, Anti Nuclear Antibody (ANA), Rheumatoid Antibody Factor (RA) factor, Perinuclear Anti Neutrophilic Cytoplasmic Antibodies (P-ANCA), Cytoplasmic Anti Neutrophilic Cytoplasmic Antibodies (C-ANCA), Anti Double stranded DNA antibodies (dsDNA) for various auto immune disorders associated uveitis, serum angiotensin converting enzyme (ACE), and serum calcium. Consultation was done with the concerned medical specialist whenever needed and referred accordingly. The final etiological diagnosis was made based on clinical features, laboratory investigations and systemic evaluation. Patients who needed long term immunosuppression therapy, Pan uveitis, uveitis with associated syndromes like Behcet, Collagen vascular diseases, Vogt-Koyanagi-Harada syndrome (VKH), uveitis with posterior segment involvement requiring intra vitreal therapy or vitrectomy, those requiring intraocular fluids such as aqueous or vitreous for a polymerase chain reaction (PCR) to be run for identification of the etiological cause of uveitis were referred to tertiary care eye hospitals and closely followed up.

Anterior Uveitis

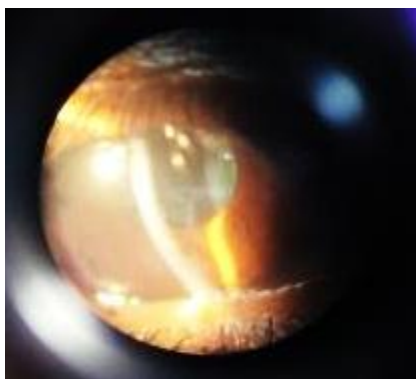


Fig. 1 A: Non granulomatous anterior uveitis- Keratic precipitates on the corneal endothelium

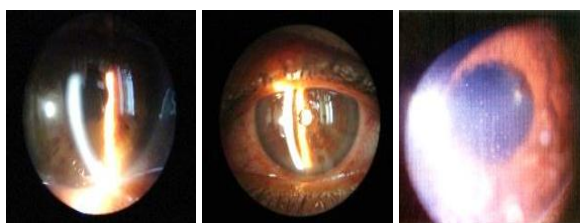

Fig. 1 B: Granulomatous anterior uveitis- Keratic precipitates at angle, Koeppe's and Busacca's nodules on the iris

Sequelae of Chronic Anterior Uveitis

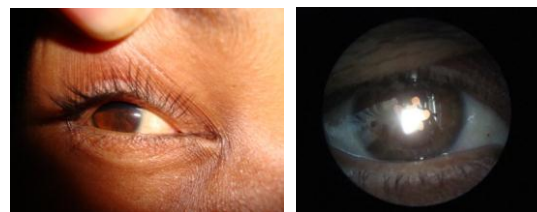


Fig. 2A: Seclisio pupillae, Fig. 2B: Festooned pupil

Posterior Uveitis

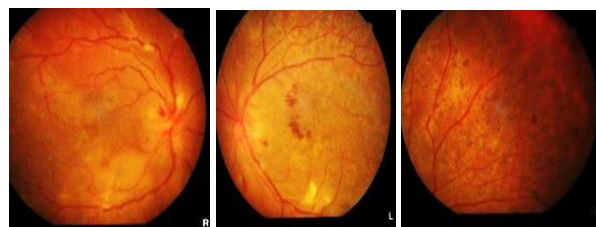


Fig. 3: Choroiditis with vasculitis

Results and Discussion

Higher incidence is seen in males (63.33%) as compared to females (36.67%). This is similar to various studies from India²⁻⁵ and abroad.⁶⁻⁸ The patients were predominantly seen in the 20-40 years age group in this study. A higher incidence of anterior uveitis (87.4%) was striking in our study as compared to Henderly et al⁶ (27.8 %) and Biswas et al² (39.28%). Majority of the anterior uveitis were either due to trauma (43.3%) or idiopathic (33%) in this study. Non-granulomatous uveitis was seen in 91.9% and formed the most common characteristic pattern of the uveitis in the study. Non infectious uveitis was more common when compared to infectious uveitis. The most commonly seen specific entity for uveitis was Tuberculosis and herpes zoster around 4 % among the infectious uveitis. Acute uveitis was seen in 60 %, chronic uveitis in 23% and recurrent uveitis in 17 %. A similar study to identify the pattern and causes in chronic uveitis was done by Weiner et al.⁹ Right eye was involved in 48 %, left eye in 39% and both eyes involvement in 13 %. A confirmatory laboratory diagnosis could be achieved only in 70% of the patients who were tested for various etiologies while the remaining 30 % no specific laboratory investigation could pin point a confirmed diagnosis for the uveitis. Most common form of anterior uveitis was due to trauma (50%), intermediate uveitis was idiopathic (86 %), posterior uveitis was due to tuberculosis (40%) and toxoplasmosis (40%) and for pan uveitis was VKH syndrome (18%). Out of the 270 patients 17 patients were diagnosed with Fuchs Heterochromic Iridocyclitis (FHIC) purely based only on the clinical features and no laboratory investigations available for the confirmation of the same. 77% of patients were treated

with topical steroids of which nearly 99 % were having anterior uveitis. 5 % of patients needed topical and systemic steroids, 2 % needed periocular injection of steroids of which 87 % had intermediate uveitis and 17 % had pan uveitis. 2 % needed a combination of topical, systemic and periocular steroid injections of which 60 % had pan uveitis and 40 % had intermediate uveitis. 14% needed some specific treatment apart from the requirement of steroids like anti- tubercular treatment (ATT), Anti toxoplasmic treatment, and anti virals. Patients requiring immunosuppressants were referred to tertiary eye care centers and were followed up as and when required. All patients were put on steroid treatment in some form with cycloplegic eye drops namely homatropine 2% or atropine 1% during the acute phases. In a study done by Rathinam et al¹⁰ it was found that uveitis accounted for 0.8% of the out-patient visits. The uveitis was idiopathic in 44.6% and the most commonly identified entities in the cohort were leptospiral uveitis (9.7%), tuberculous uveitis (5.6%), herpetic uveitis (4.9%). The most common uveitis seen in children below 16 years was parasitic anterior uveitis and in adults more than 60 years was herpetic anterior uveitis¹⁰. As in other tropical countries, there was a higher incidence of infectious uveitis seen in this population.¹⁰

The causes of uveitis vary between regions and are very complex and incompletely understood. They include a lot of host and environmental factors.^{11,12} Among the environmental factors, the most important appears to be the regional distribution of various pathogens¹¹⁻¹⁶ including new and emerging agents.

The challenges these patients posed to us were in making a confirmatory diagnosis with investigations supporting the clinical picture or a differential diagnosis which most often came negative. So the patients were treated based on a clinical diagnosis and the response to treatment was considered to be a confirmatory evidence for a particular disease even though the lab reports were negative. On some occasions the patients were unable to afford for the expensive investigations or even if they were done it was inconclusive and needed further tests which was very difficult to explain and convince the patient. The patients sometimes lost to follow up and ended stopping the treatment, later on coming back with multiple recurrences and complications. Some of the patients and their relatives were asking about complete cure of the condition and were really mentally depressed due to the illness with frequent recurrences affecting their social and family life.

Table 1: Demographic characteristics

| Characteristics | Location | | | | Total |
|-----------------------------|----------------------------|-----------------------------|---------------------------|---------------------|--------------|
| | Anterior (n=236: 87.4%) | Intermediate (n=7: 2.6%) | Posterior (n=10: 3.7%) | Pan (n=17: 6.3%) | |
| Age at presentation (years) | | | | | |
| Range | 6-83 | 23-38 | 15-75 | 23-86 | 6-86 |
| Mean±SD | 37.1±15.9 | 31.7±5.8 | 34.1±20.7 | 55.2±18.5 | 38.0±16.7 |
| Median | 33.5 | 35.0 | 28.5 | 59.0 | 34.0 |
| Age group | | | | | |
| <20 | 29 (93.5%) | - | 2 (6.5%) | - | 31 (100.0%) |
| 20 – 40 | 117 (86.0%) | 7 (5.1%) | 6 (4.4%) | 6 (4.4%) | 136 (100.0%) |
| 41 – 60 | 70 (94.6%) | - | - | 4 (5.4%) | 74 (100.0%) |
| >60 | 20 (69.0%) | - | 2 (6.9%) | 7 (24.1%) | 29 (100.0%) |
| Gender (%) | | | | | |
| Male | 148 (86.5%) | 4 (2.3%) | 7 (4.1%) | 12 (7.0%) | 171 (100.0%) |
| Female | 88 (88.9%) | 3 (3.0%) | 3 (3.0%) | 5 (5.1%) | 99 (100.0%) |

Table 2: Clinical characteristics

| Characteristics | Location | | | | Total |
|-----------------|----------------------------|-----------------------------|---------------------------|---------------------|------------|
| | Anterior (n=236; 87.4%) | Intermediate (n=7; 2.6%) | Posterior (n=10; 3.7%) | Pan (n=17; 6.3%) | |
| Chronicity | | | | | |
| Acute | 159 (67.4) | - | 1 (10.0) | - | 160 (59.3) |
| Chronic | 55 (23.3) | 2 (28.6) | - | 7(41.2) | 64 (23.7) |
| Recurrent | 22 (9.3) | 5 (71.4) | 9 (90.0) | 10 (58.8) | 46 (17.0) |
| Laterality | | | | | |
| Right Eye | 116 (49.2) | 3 (42.9) | 3 (30.0) | 8 (47.1) | 130 (48.1) |
| Left Eye | 96 (40.7) | - | 5 (50.0) | 4 (23.5) | 105 (38.9) |

| | | | | | |
|-----------------------------|------------|-----------|----------|------------|------------|
| Both | 24 (10.2) | 4 (57.1) | 2 (20.0) | 5 (29.4) | 35 (13.0) |
| Pattern | | | | | |
| Non-Granulomatous | 224 (94.9) | 6 (85.7) | 7 (70.0) | 11 (64.7) | 248 (91.9) |
| Granulomatous | 12 (5.1) | 1 (14.3) | 3 (30.0) | 6 (35.3) | 22 (8.1) |
| Etiological Classification | | | | | |
| Idiopathic | 81 (34.3) | 6 (85.7) | 1 (10.0) | 1 (5.9) | 89 (33.0) |
| Identified syndrome/disease | | | | | |
| Infectious | 24 (10.2) | 1 (14.3) | 9 (90.0) | 16 (94.1) | 50 (18.5) |
| Noninfectious | 212 (89.8) | 6 (85.7) | 1 (10.0) | 1 (5.9) | 220 (81.5) |
| Investigations done | | | | | |
| Yes | 59 (25.0) | 7 (100.0) | 8 (80.0) | 17 (100.0) | 91 (33.7) |
| No | 177 (75.0) | - | 2 (20.0) | - | 179 (66.3) |
| Lab diagnosis arrived | | | | | |
| Yes | 161 (68.2) | 1 (14.3) | 9 (90.0) | 16 (94.1) | 187 (69.3) |
| No | 75 (31.8) | 6 (85.7) | 1 (10.0) | 1 (5.9) | 83 (30.7) |
| Treatment Given | | | | | |
| Topical Steroids | 207 (87.7) | - | 1 (10.0) | - | 208 (77.0) |
| Topical+Systemic steroids | 13 (5.5) | - | - | - | 13 (4.8) |
| Periocular injections | - | 5 (71.4) | - | 1 (5.9) | 6 (2.2) |
| Combination therapy | - | 2 (28.6) | - | 3 (17.6) | 5 (1.9) |
| Specific treatment | 16 (6.8) | - | 9 (23.7) | 13 (76.5) | 38 (14.1) |

Table 3: Etiological classification by age group distribution

| Diagnosis | <20 | % | 20-40 | % | 41-60 | % | >60 | % | Total | % | Mean age | p-value* |
|-----------------|-----|------|-------|------|-------|------|-----|------|-------|------|----------|----------|
| Idiopathic | 6 | 19.4 | 45 | 33.1 | 28 | 37.8 | 10 | 34.5 | 89 | 33.0 | 39.8 | 0.376 |
| Trauma | 23 | 74.2 | 60 | 44.1 | 27 | 36.5 | 7 | 24.1 | 117 | 43.3 | 33.4 | 0.011 |
| TB | 1 | 3.2 | 7 | 5.1 | 2 | 2.7 | 1 | 3.4 | 11 | 4.1 | 35.6 | 0.639 |
| HZO | - | - | 5 | 3.7 | 5 | 6.8 | 2 | 6.9 | 12 | 4.4 | 44.6 | 0.181 |
| FHIC | - | - | 11 | 8.1 | 6 | 8.1 | - | - | 17 | 6.3 | 38.9 | 0.825 |
| Toxoplasmosis | - | - | 3 | 2.2 | - | - | 1 | 3.4 | 4 | 1.5 | 38.0 | 1.000 |
| VKH | - | - | 3 | 2.2 | - | - | - | - | 3 | 1.1 | 31.3 | 0.488 |
| HIV | - | - | 1 | 0.7 | - | - | - | - | 1 | 0.4 | 33.0 | - |
| Hansens Disease | - | - | 1 | 0.7 | 2 | 2.7 | - | - | 3 | 1.1 | 41.0 | 0.756 |
| Toxocariasis | 1 | 3.2 | - | - | - | - | - | - | 1 | 0.4 | 18.0 | - |
| Others | - | - | - | - | 4 | 5.4 | 8 | 27.6 | 12 | 4.4 | 66.8 | <0.001 |
| Total | 31 | 100 | 136 | 100 | 74 | 100 | 29 | 100 | 270 | 100 | 38.0 | |

*Mean age in years of individual diagnosis – compared with overall mean age, 38.0 years

Table 4: Causes of anterior uveitis

| Causes | No. (%) of Patients | <20 | 20 – 40 | 41 – 60 | >60 | Mean Age | p-value* |
|------------|---------------------|-------------|------------|-------------|------------|-----------|----------|
| | | 236 (87.4%) | 29 (12.3%) | 117 (49.6%) | 70 (29.7%) | 20 (8.5%) | |
| Idiopathic | 81 (34.3) | 6 (20.7) | 38 (32.5) | 28 (40.0) | 9 (45.0) | 40.0 | 0.343 |
| Trauma | 117 (49.6) | 23 (79.3) | 60 (51.3) | 27 (38.6) | 7 (35.0) | 33.4 | 0.011 |
| TB | 4 (1.7) | - | 2 (1.7) | 1 (1.4) | 1 (5.0) | 42.5 | 0.593 |
| HZO | 12 (5.1) | - | 5 (4.2) | 5 (7.1) | 2 (10.0) | 44.6 | 0.181 |

| | | | | | | | |
|-----------------|----------|---|----------|---------|---------|------|-------|
| FHIC | 17 (7.2) | - | 11 (9.4) | 6 (8.6) | - | 38.9 | 0.825 |
| Hansens Disease | 3 (1.3) | - | 1 (0.9) | 2 (2.9) | - | 41.0 | 0.756 |
| Others | 2 (0.8) | - | - | 1 (1.4) | 1 (5.0) | 60.0 | 0.064 |

*Mean age in years of individual diagnosis – compared with overall mean age, 38.0 years

Table 5: Causes of intermediate uveitis

| Causes | No. (%) of Patients | 20 – 40 | Mean | p-value* |
|------------|---------------------|------------|------|----------|
| | | | Age | |
| | 7 (2.6%) | 7 (100.0%) | | |
| Idiopathic | 6 (85.7) | 6 (85.7) | 32.0 | 0.381 |
| TB | 1 (14.3) | 1 (14.3) | 30.0 | - |

*Mean age in years of individual diagnosis – compared with overall mean age, 38.0 years

Table 6: Causes of posterior uveitis

| Causes | No. (%) of Patients | <20 | 20 – 40 | >60 | Mean | p-value* |
|---------------|---------------------|-----------|-----------|-----------|------|----------|
| | | | | | Age | |
| | 10 (3.7%) | 2 (20.0%) | 6 (60.0%) | 2 (20.0%) | | |
| Idiopathic | 1 (10.0) | - | - | 1 (50.0) | 75.0 | - |
| TB | 4 (40.0) | 1 (50.0) | 3 (50.0) | - | 24.0 | 0.095 |
| Toxoplasmosis | 4 (40.0) | - | 3 (50.0) | 1 (50.0) | 38.0 | 1.000 |
| Toxocariasis | 1 (10.0) | 1 (50.0) | - | - | - | - |

*Mean age in years of individual diagnosis – compared with overall mean age, 38.0 years

Table 7: Causes of pan uveitis

| Causes | No. (%) of Patients | 20 – 40 | 41 – 60 | >60 | Mean | p-value* |
|------------|---------------------|-----------|-----------|-----------|------|----------|
| | | | | | Age | |
| | 17 (6.3%) | 6 (35.3%) | 4 (23.5%) | 7 (41.2%) | | |
| Idiopathic | 1 (5.9) | 1 (16.7) | - | - | 34.0 | - |
| TB | 2 (11.8) | 1 (16.7) | 1 (25.0) | - | 48.0 | 0.399 |
| VKH | 3 (17.6) | 3 (50.0) | - | - | 31.3 | 0.488 |
| HIV | 1 (5.9) | 1 (16.7) | - | - | 33.0 | - |
| Others | 10 (58.8) | - | 3 (75.0) | 7 (100.0) | 68.2 | <0.001 |

*Mean age in years of individual diagnosis – compared with overall mean age, 38.0 years

Conclusion

In this study the most common type of uveitis was anterior uveitis and males were affected more than females. Most common age group was between 20-40 years. Non granulomatous uveitis was more common compared to granulomatous uveitis. Non infectious uveitis was more common when compared to infectious uveitis. The most commonly seen specific infectious uveitis was tuberculous uveitis and herpetic uveitis. The diagnosis of uveitis is pretty simple but finding out the cause of the underlying condition many a times is difficult and even when a specific entity is clearly seen clinically, does not provide a significant positive laboratory confirmation and this not only frustrates the patient but also the treating physician. Changing patterns in uveitis should always be borne in mind by the treating physician at different periods of time in the same regions based on new emerging pathogens and other environmental factors. Introduction of new uveitis entities, changes in the incidence of already known disease and increased availability of diagnostic testing have all altered the epidemiology of uveitis in

recent years. Knowledge of regional patterns of disease is essential¹⁷ while handling patients with uveitis.

References

- Jabs DA, Nussenblatt RB, Rosenbaum JT. Standardization of Uveitis Nomenclature (SUN) Working Group. Standardization of uveitis nomenclature for reporting clinical data. Results of the First International Workshop. Am J Ophthalmol. 2005 Sep;140(3):509-16.
- Biswas J, Narain S, Das D, Ganesh SK. Pattern of uveitis in a referral uveitis clinic in India. Int Ophthalmol. 1996-1997;20:223-8.
- Dandona L, Dandona R, John RK, McCarty CA, Rao GN. Population based assessment of uveitis in an urban population in southern India. Br J Ophthalmol. 2000;84:706-9.
- Rathinam SR, Namperumalsamy P. Global variation and pattern changes in epidemiology of uveitis. Indian J Ophthalmol. 2007;55:173-83.
- Singh R, Gupta V, Gupta A. Pattern of uveitis in a referral eye clinic in North India. Indian J Ophthalmol. 2004;52:121-5.
- Henderly DE, Genstler AJ, Smith RE, Rao NA. Changing patterns of uveitis. Am J Ophthalmol. 1987;103:131-6.

7. Smith RE, Nozik RA. Uveitis: A clinical approach to diagnosis and management. 2nd ed. Baltimore: Williams and Wilkins; 1989.
8. Perkins ES, Folk J. Uveitis in London and Iowa. *Ophthalmologica*. 1984;189:36-40.
9. Weiner A, Ben Ezra D. Clinical patterns and associated conditions in chronic uveitis. *Am J Ophthalmol*. 1991;112:151-8.
10. Rathinam SR, Namperumalsamy P. Global variation and pattern changes in epidemiology of uveitis. *Indian J Ophthalmol*. 2007 May-Jun;55(3):173-83.
11. Glasner PD, Silveira C, Kruszon-Moran D, Martins MC, Burnier Júnior M, Silveira S, Camargo ME, Nussenblatt RB, Kaslow RA, Belfort Júnior R. An unusually high prevalence of ocular toxoplasmosis in southern Brazil. *Am J Ophthalmol*. 1992 Aug 15;114(2):136-44.
12. Rathinam SR, Cunningham ET Jr. Infectious causes of uveitis in the developing world. *Int. Ophthalmol Clin* 2000; 40(2):137-52.
13. Rathinam SR, Rathnam S, Selvaraj S, Dean D, Nozik RA, Namperumalsamy P. Uveitis associated with an epidemic outbreak of leptospirosis. *Am J Ophthalmol*. 1997 Jul;124(1):71-9.
14. Rathinam SR. Ocular leptospirosis. *Curr Opin Ophthalmol*. 2002 Dec;13(6):381-6.
15. Rathinam SR, Usha KR, Rao NA. Presumed trematode-induced granulomatous anterior uveitis: a newly recognized cause of intraocular inflammation in children from south India. *Am J Ophthalmol*. 2002 Jun;133(6):773-9.
16. Rathinam SR, Namperumalsamy P. Leptospirosis. *Ocul Immunol Inflamm*. 1999 Jun;7(2):109-18.
17. Tsirouki T, Dastiridou A, Symeonidis C, Tounakaki O, Brazitikou I, Kalogeropoulos C, Androudi S. A Focus on the Epidemiology of Uveitis. *Ocul Immunol Inflamm*. 2018;26(1):2-16.