

## Outcomes of lumbar canal stenosis treated with posterior decompression and spinal instrumentation

Vikramjit Singh<sup>1</sup>, Anirudh Bansal<sup>2</sup>, Arvind Kumar<sup>3,\*</sup>, Sudhir Rawat<sup>4</sup>, Bhagirat Singh Kela<sup>5</sup>

<sup>1,2,3</sup>rd Year Resident, <sup>3</sup>Associate Professor, <sup>4</sup>Assistant Professor, <sup>5</sup>2nd Resident, Dept. of Orthopaedics, SBKSMIRC & Dhiraj Hospital, Vadodara, Gujarat, India

**\*Corresponding Author: Arvind Kumar**

Email: drakumar76@gmail.com

### Abstract

**Introduction:** Lumbar spinal stenosis is a frequent indication for spinal surgery. The clinical symptoms may not be accurately reflected on radiological studies. Treatment is aimed at not only obtaining immediate pain relief but also in preventing its long-term disabling sequelae. The walking ability needs to be correlated with functional outcome measures in assessing patients with symptomatic lumbar canal stenosis (LCS).

**Aims and Objectives:** To study and evaluate the outcome of surgery for degenerative LCS on a clinical, radiological, and functional basis, and to establish an association between various factors that may be influencing the development of LCS.

**Materials and Methods:** A prospective study of 24 patients was carried out at the Department of Orthopaedics, Dhiraj General Hospital, Piparia, Vadodara, in whom the LCS was confirmed and measured on magnetic resonance imaging images by thecal sac cross-sectional area (CSA). The functional assessment pre-operative and post-operatively was calculated according to the Japanese Orthopaedic association score.

**Results:** Overall, 83.33% patients (n=20) in our study showed improvement in all variables of the JOA scoring system postoperatively. 66.66% patients (n=16) showed excellent outcome, 25% (n=6) showed good outcome, and 8.33% (n=2) showed fair outcome. No patient had poor outcome. After surgery 95.83% patients (n=23) had normal gait with walking distance more than 500 m and no claudication symptoms.

**Conclusions:** Operative treatment in patients of degenerative lumbar canal stenosis with decompression and spinal instrumentation yields excellent results as observed on the basis of JOA scoring system.

**Keywords:** Spine, Stenosis, Decompression, Disc, Claudication.

### Introduction

Spinal stenosis presents with symptoms of back, buttock or leg pain having characteristic provocative and palliative features.<sup>1</sup> Spinal canal stenosis is described as narrowing of spinal canal by a combination of bone and soft tissues leading to mechanical compression of nerve roots. Pseudo-claudication or neurogenic claudication is found to be the classical symptom of stenosis in spinal canal.<sup>2-7</sup>

Lumbar canal stenosis was first described by Sachs and Frankel in 1900. However its first clinical description is attributed to Henk Verbiest – a Dutch neurosurgeon (1954). Since then surgeons are searching for accurate method of definite diagnosis and operative treatment for spinal canal stenosis (SCS). Arnoldi et al. (1976) proposed the major classification which remains more useful.<sup>8</sup>

Congenital, developmental, acquired, degenerative, iatrogenic, post traumatic and metabolic are the basic classification types for spinal canal stenosis. Acquired senile degenerative stenosis is the most common and observed type which is further classified into central, peripheral and degenerative spondylolisthesis types.

Aging causes spinal canal degeneration which is the major manifestation of SCS. It becomes symptomatic in the fifth and sixth decades of life. Manifestation of symptoms in lumbar stenosis occur in 2 types.

1. Central canal narrowing causing Neurogenic Claudication (unilateral/bilateral)
2. Radiculopathy due to narrowing of the vertebral foramen.

Patient can present with one or both symptoms. Neurogenic claudication also known as pseudo claudication is a definitive characteristic of spinal canal stenosis.

Neurogenic claudication is characterized with leg pain, parasthesia and weakness in accordance with walking or standing which affects the standing time and walking distance i.e the overall mobility of the patient. Pain, which can be unilateral radicular pain or having diffuse nondermatomal symptoms originating in the back and buttocks and radiating into variable distance into the legs is the predominant and characteristic feature of spinal canal stenosis. Sitting or bending forwards relieve symptoms in Lumbar canal stenosis which differentiates it from vascular claudication.

Degenerative conditions involving the spine are the gradual loss of normal spine structure and function over time that is commonly caused by aging, but may also be the result of tumors, infections or arthritis. This process can alter the pressure on the nerve root and spinal cord. Thus causing degenerative spinal canal stenosis. Acquired lumbar canal stenosis most often occurs from age-associated degenerative or arthritic changes that affect the complex that includes the lumbar vertebrae, facet joints, and adjoining intervertebral disk. The earliest changes occur in the disks, with desiccation and flattening that can lead to disk bulging and collapse.

History and physical findings alone can determine lumbar canal stenosis in many cases, non-contrast stress

MRI now provides a confirmation in many cases, and now routine myelography is no longer necessary. The anatomic presence of spinal stenosis is confirmed radiologically with X-ray or MRI. The correlation of clinical symptoms with radiographic imaging is necessary to make the clinical diagnosis of lumbar spinal stenosis.

Conservative measures do not improve Severe Lumbar canal stenosis. Deficit in neurology is the absolute indication for surgery. For patients who are persistently symptomatic despite adequate conservative care, surgery can offer a highly rewarding and effective for improvement in quality of life.

The surgical procedure which is done most commonly for the adult lumbar spine is mostly for Lumbar canal stenosis.<sup>9</sup> The main of surgical intervention is to relieve the pressure on neural tissues and nerve root canals while passing through the neural canal.<sup>10</sup>

Various surgical techniques for operative treatment for lumbar canal stenosis have been developed and explained in literature since then with varied results. These includes hemilaminectomy, standard laminectomy, wide laminectomy, laminotomy, split spinous process laminectomy, spinous process osteotomy & laminectomy and their numerous modification.

Decompressive laminectomy is a widely used operative treatment for Lumbar canal stenosis.<sup>11</sup> A single level facet-sparing laminectomy is the commonly used surgical decompression procedure. Although after the impinged nerves are decompressed and neurological symptoms, like sciatica, claudication, motor, sensory and reflex activities, improve following surgery,<sup>12</sup> the anatomical destruction of this technique affects spinal biomechanics. Lumbar segment instability is a significant post operative complication clinically.<sup>13,14</sup> Some surgeon prefer long segment fusions to reduce post operative instability, however, such surgeries leads to loss of motion of lumbar spine and predispose to adjacent level degeneration and further canal stenosis.<sup>15-18</sup> Adequate spinal decompression while maintaining the spinal stability is mainstay in the treatment of spinal stenosis.<sup>19</sup>

Decompressive total laminectomy with or without spinal instrumentation and fusion is said to be the gold standard surgical procedure for the treatment of lumbar canal stenosis. Verbiest was of the opinion that spread of the articular process on the spinal cord is the prime cause for stenosis leading to symptoms. Hence, laminectomy as a procedure alone may not sufficient without removal of the medial part of the articular facets.<sup>20</sup> Hemilaminectomy, laminoplasty and interlaminar fenestration have been suggested and considered as alternative procedures in order to maintain the stability of the spinal column.

The present study highlights the results of surgical management of secondary degenerative lumbar canal stenosis with decompression and spinal instrumentation in the form of pedicular screws and rods and analyzes the effect on various outcome variables using the Japanese Orthopaedic Association score.

## Materials and Methods

This was a prospective study involving 24 patients diagnosed with degenerative LCS at Dhiraj General Hospital who underwent posterior decompression and spinal instrumentation using transpedicular systems. Study comprised of patients having degenerative lumbar canal stenosis in a single or multiple levels. The diagnosis of LCS was based on the clinical symptoms, neurological examinations and imaging studies like plain radiography and MRI. All 24 patients presented with typical symptoms of LCS, like neurogenic intermittent claudication and leg pain with/without numbness. The exclusion criteria were prior lumbar spine surgery due to other cause of Lumbar canal stenosis like traumatic, metabolic, congenital, tumors and infection, and also patients who were medically unfit for surgery due to other comorbidities.

Cross section area of lumbar spinal canal by MRI was evaluated in all patients presenting with symptoms of LCS with neurological claudication.

Based on the canal cross sectional area

1. 180 + 50 mm<sup>2</sup> - normal range,
2. 100-70 mm<sup>2</sup> - moderate stenosis,
3. <70 mm<sup>2</sup> - severe stenosis.

Based on clinical and radiological evidence of disc prolapse and dissection, decision for discectomy as and when required was taken. Central canal diameter on MRI if found to be 10mm or less were planned for surgery after due consideration and trial of conservative treatment. Flexion and extension lateral radiographs were taken to evaluate the Spinal instability as per Posner's criteria. In all cases of surgical intervention, Laminectomy with decompression and instrumentation for stabilization of the spine was done. When a soft bulging disc was found intraoperatively, Discectomy was done. According to this protocol which was formulated, laminectomy with instrumental stabilization was done in all 24. Cases undergoing surgery, Laminectomy and discectomy with instrumented stabilization was done in 15 cases. The follow up period was in the range of 10–19 months (average: 13 months) in the present study. 15 patients had a follow up period for more than a year. JOA evaluation system was used to assess Pre and post-operative low back pain and other symptoms.

The JOA score was evaluated through subjective symptoms of individual patients clinical signs, and restriction of activities of daily living.

## Observations and Results

The mean age in the present study was 48.2 years (range 35-68 years). 15 males and 9 females were included in our study. All patients in our study had continuous. Symptoms for more than 3 months. All the variables of JOA scoring system was assessed in all patients before and after the surgical intervention [Table 1]. Continuous severe low backache was present in .58.33% (14) of patients, 33.33% (8) had occasional severe low backache and 8.33% (2) presented with occasional mild low backache when evaluated preoperatively. After the surgery on Six months

follow up, complete relief of back pain was observed in 83.33% (20) patients and 16.66% (4) had occasional mild low back pain. None of the patients had severe or continuous symptoms after surgical intervention.

Pre operatively 83.33% (20) patients had presented with severe leg pain with respect to posture but post-operatively 95.83% patients (23) had no leg pain. 95.83% patients (23) had normal gait with walking distance of more than 500 m without neurological claudication in comparison to claudication pain with walking for a distance <300 m before surgery.

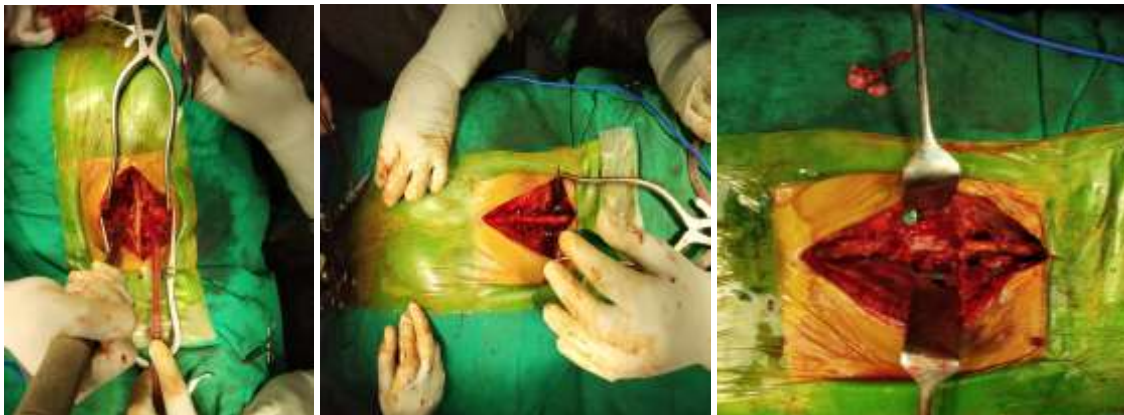
The most common level involved in stenosis was L4-L5 (66.66%) patients (16) and secondly L5-S1 (33.33%) patients, (8). 33.33% patients (8) showed stenosis of more than a single level. SLRT (straight leg. raising test) was abnormal in .91.66% (22) patients. Severely affected positive SLRT (below 30°) was seen in 29.16% patients (7) and SLRT between 30°-70° was seen in 62.5% (15) patients. But postoperatively 91.66% (22) patients had SLRT >80°.

Decreased sensations were seen in L4, L5, S1 dermatomes in 5, 6 and 3 patients respectively. More than one dermatome was involved in 4 patients. Overall, sensory disturbance were seen in 14 patients (58.33%)

preoperatively. We observed a complete recovery in all of these patients in respect to sensory function. Motor function were affected in 11 patients (45.83%) during evaluation before surgery, but postoperatively only 1 patient (4.16%) showed motor function deficit.

Overall, in respect to all variables of JOA scoring system 83.33% patients (20) showed improvement postoperatively. At 6 months follow up, we observed excellent results in 41.66% patients (10) and 50%. (12) showed good outcome. At the final follow up, 66.66% patients (16) showed excellent, 25% (6) showed good, and 8.33% (2) showed fair outcomes. Poor outcome was not observed in any of the patient. Patients outcome improved with time after the surgery and. Remained static thereafter till the last follow up. Statistically significant improvement were seen in all other variables except lifting heavy weights and running.

Among all 2 patients had dural tears during intra-operative period as a complication which were repaired and hence, spontaneous uneventful recovery was observed without any consequence. 1 patient developed post operative infection which was treated in the form of debridement and sensitive antibiotics. The patient made an uneventful recovery following it.



Intra-Operative

<b>CLINICAL HISTORY:</b>	Lower back pain with tingling.
<b>SPECIMEN:</b>	Laminectomy specimen comprising of soft tissue with bone chunks.
<b>GROSS EXAMINATION:</b>	Received multiple soft tissue bits aggregating 2.5 x 1 x 0.5 cm.
<b>MICROSCOPY:</b>	6584/18: The sections studied shows normal disc material. Mild inflammatory infiltrates are seen.
<b>IMPRESSION:</b>	<b>NORMAL INTERVERTEBRAL DISC</b>

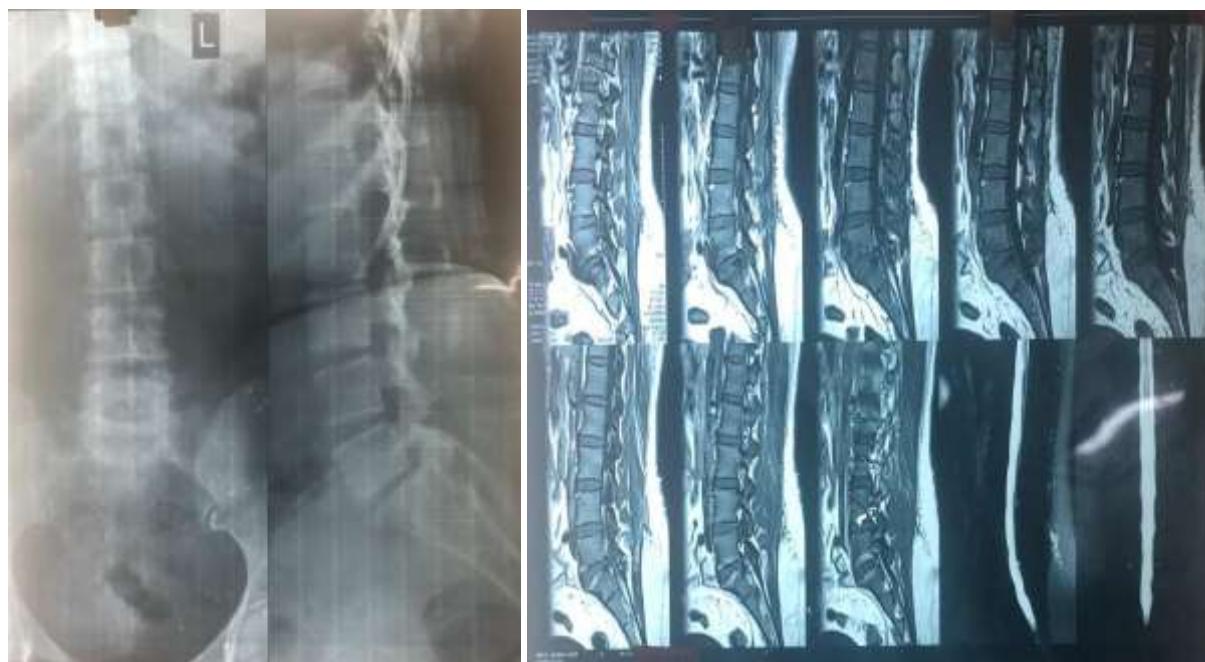Biopsy report

## JOA score

Variables of JOA score	Pre operative assessment		Assessment at final follow up	
	Number	%	Number	%
Low Back Pain				
1. None(3)	0	0	20	83.33%
2. Occasional, Mild (1)	2	8.33%	4	16.66%
3. Frequent, Mild or Occasional severe(1)	8	33.33%	0	
4. Frequent, severe (0)	14	58.33%	0	
Leg Pain				
1. None (3)	0	0	23	95.83%
2. Occasional mild leg pain or numbness (2)	0	0	1	4.16%
3. Frequent mild or occasional severe leg pain or numbness (1)	4	16.66%	0	0
4. Frequent, severe leg pain or numbness (0)	20	83.33%	0	0
Gait				
1. Normal (3)	0	0	23	95.83%
2. Able to walk >500m with leg pain or numbness (2)	0	0	1	4.16%
3. Able to walk 100-500m (1)	19	79.16%	0	0
4. Unable to walk >100m (0)	5	20.83%	0	0
Straight leg raising				
1. Normal (2)	2	8.33%	22	91.66%
2. 30-70 (1)	15	62.5%	2	8.33%
3. <30 (0)	7	29.16%	0	0
Sensory deficit				
1. Normal (2)	10	41.66%	24	100%
2. Slight disturbance (1)	14	58.33%	0	0
3. Severe disturbance(0)	0	0	0	0
Motor deficit				
1. Normal (2)	13	54.16%	23	95.83%
2. Motor power > grade 3 (1)	11	45.83%	1	4.16%
3. Motor power < grade 3 (0)	0	0	0	0
Turnover while lying				
1. Easy (2)	4	16.66%	22	91.66%
2. Difficult (1)	20	83.33%	2	8.33%
3. Impossible (0)	0	0	0	0
Standing up				
1. Easy (2)	9	37.5%	24	100%
2. Difficult (1)	15	62.5%	0	0
3. Impossible (0)	0	0	0	0
Washing face				
1. Easy (2)	18	75%	22	91.66%
2. Difficult (1)	6	25%	2	8.33%
3. Impossible (0)	0	0	0	0
Leaning forward				
1. Easy (2)	2	8.33%	19	79.16%
2. Difficult (1)	14	58.33%	5	20.83%
3. Impossible (0)	8	33.33%	0	0
Siting about 1 hour				
1. Easy (2)	0		18	75%
2. Difficult (1)	11	45.83%	6	25%
3. Impossible (0)	13	54.16%	0	0
Lifting heavy weight				

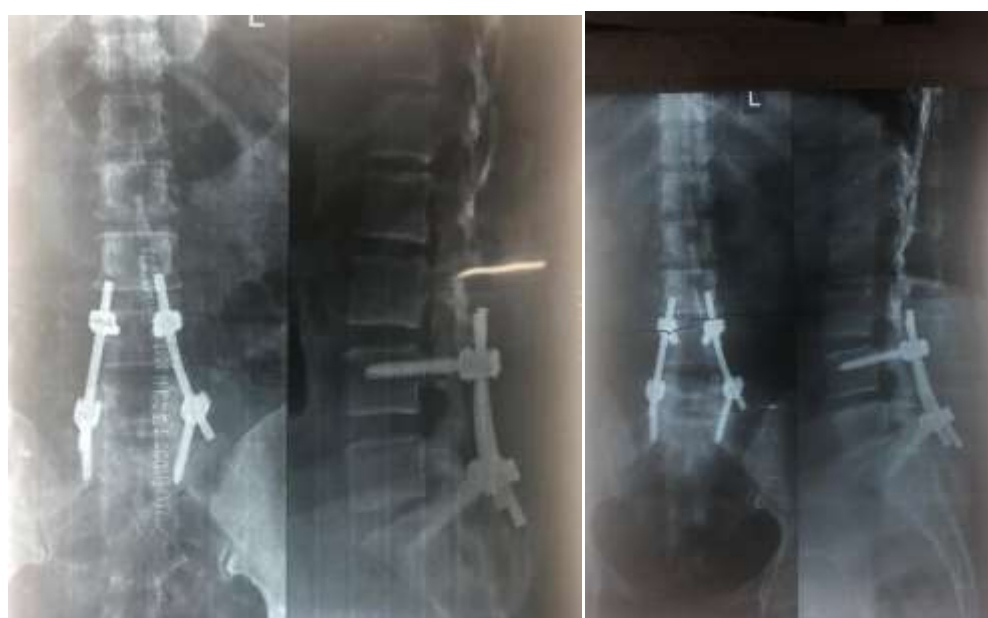1. Easy (2)	0		7	29.16%
2. Difficulty (1)	7	29.16%	13	54.16%
3. Impossible (0)	17	70.83%	4	16.66%
<b>Running</b>				
1. Easy (2)	0		6	25%
2. Difficulty (1)	5	20.83%	14	58.33%
3. Impossible (0)	19	79.16%	4	16.66%

**Case No. 1: 44 Year old female with chronic leg pain and neurogenic claudication**



**Pre-Operative X –Ray**

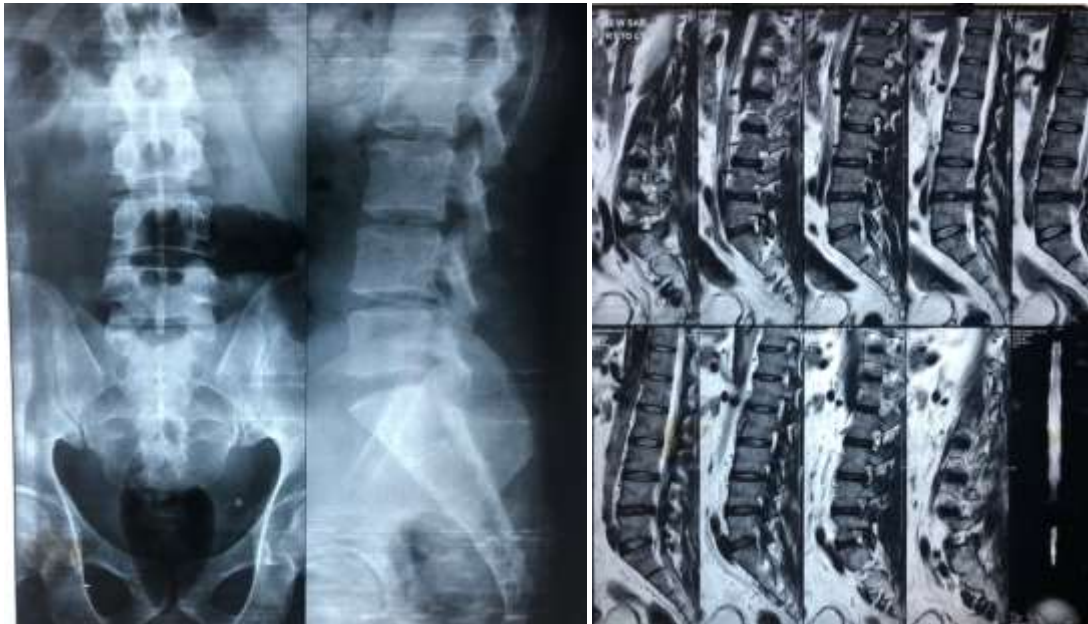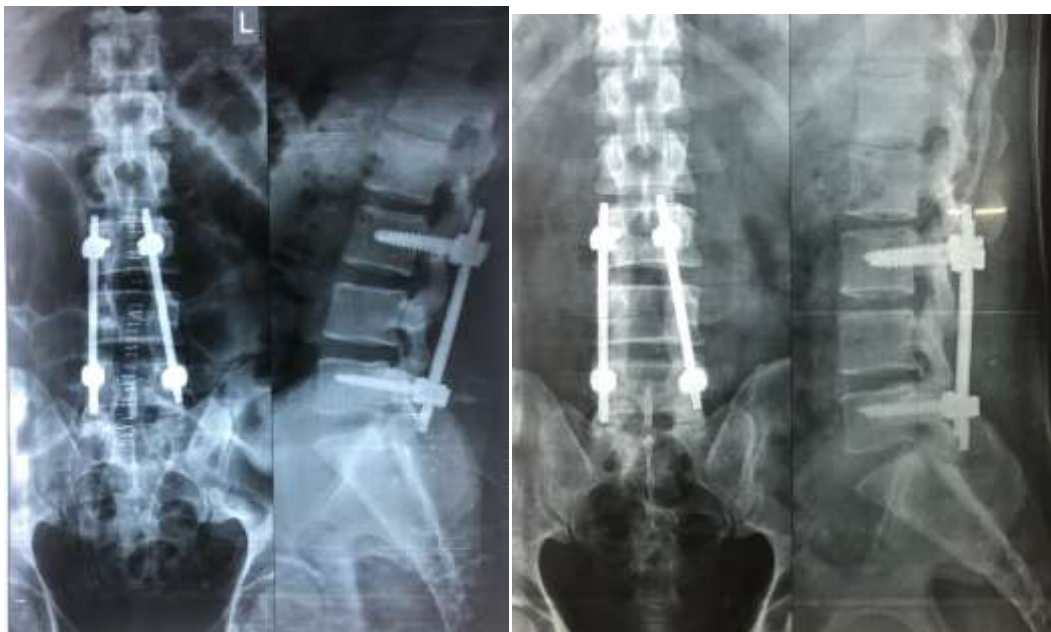**Pre-Operative MRI**



**Immediate post operative X-ray**

**Final follow up**



**Case No. 2: 51 Years old male with chronic low back and leg pain with claudication****Pre-operative X-ray****Pre-Operative MRI****Post-operative X-ray****Final follow up****Discussion**

In our present study 66.66% patients showed excellent and 25% showed good outcome at the final follow up, while Ganz et al. (1990) demonstrated almost similar result as the present study showing 86% good outcome in their series of 33 patients operated with decompressive surgery.<sup>21</sup>

In our study, finally, 83.33% patients had no back pain and occasional mild pain seen in 16.66%, 95.83% had no leg pain at all, 95.83% had normal gait, 91.66% had normal SLRT, and 100% had sensory improvement. (i.e. patients who presented with sensory disturbance). Herron et al.

(1991) observed similar findings in their study with improvement of leg pain in 82% and overall improvement in back pain of 71%.<sup>22</sup>

Weinstein et al. (2010) in their prospective study of 654 patients observed that patients with significant spinal canal stenosis treated surgically compared with those treated conservatively had substantially greater findings in pain and function through 4 years. All patients in the said study were surgical candidates with a history of at least 3 months of neurological claudication or radicular leg pain and spinal stenosis without spondylolisthesis. The patients were treated

by either standard decompressive laminectomy (414 patients) or usual conservative management (240 patients).<sup>23</sup>

Decompressive laminectomy was also significantly supplemented with pedicle screw fixation and/or discectomy as and when needed (cases with a soft bulging disc). Only two patients had fair outcome. The failure of surgery to completely alleviate pain in these two patients may be due to widespread degeneration. Outcomes were also considered to be affected due to some variables of scoring system like running and heavy weight lifting in which female patients and patients over 50 years scored less despite being free of pain due to the difficulty in performing the said activities.

Getty (1980) in his study of 31 patients (age range 18 to 75 years) who were managed surgically for lumbar spinal stenosis between 1968 and 1978 and followed for an average period of 42 months found that in 28 (90%) patients, progressive continuous degenerative changes in the lumbar spine was the main causative factor; with the other 3 having idiopathic developmental lumbar spinal stenosis. In his study of 17 (55%) patients, the result was found to be good, with a total of 26 (84%) patients satisfied with the final outcome. This is in comparison to our study in which 93.75% patients (30) were satisfied with their final outcome. Good results of surgery for lumbar spinal stenosis in series of Getty were observed by rapid relief of claudication symptoms in the lower limbs. The most important reason for failure to relieve symptoms in his series was considered to be inadequate surgical decompression.<sup>24</sup>

Postacchini et al. (1992) observed bony regrowth in 88% of 40 patients in his study who had laminectomy or laminotomy for spinal canal stenosis at an average of 8.6 years of followup. Bone regrowth was observed in all patients with associated spondylolisthesis. We did not observe any case of bone regrowth in our series. A major reason could be that the period of follow up in our study was significantly lower as compared to the above mentioned series.<sup>25</sup>

Also, we did a wide laminectomy with medial facetectomy in all of our patients in comparison to narrow laminotomy in some cases of Postacchini et al. Postacchini (1999) proclaimed that 70–80% of patients of lumbar canal stenosis had favourable result from surgery, but the clinical symptoms tended to deteriorate in the long term.<sup>25</sup> In our study, the outcomes gradually improved postoperatively till 1 year but thereafter neither showed any improvement or deterioration till last follow up.

When we assess our complications we found that there were 3 cases (12.5%) cases with surgical complications. It was equivalent to the study of Hermansen et al (11%). Out of those 3 cases, 2 (8.33%) had dural ruptures. Weiner et al. Reported 4 (8%) cases who had dural rupture. Hermansen et al<sup>26</sup> had 1 (<1%) case of dural rupture. We had 1 (4%) case of infection where had Hermansen et al had 1 (<1%) case of infection.

With the result of the present study we are of the opinion that surgical treatment in patients of degenerative lumbar canal stenosis yields excellent long term functional results as observed on the basis of JOA scoring system with

a strict inclusion criteria that patients are properly selected and adequate decompressive surgery is performed with simultaneously addressing the associated instability or spondylolisthesis. In the present study all activities of daily living which were assessed using JOA score showed significant improvement except for running and heavy weight lifting. No patient in the present study got recurrence of symptoms of nerve compression and claudication.

## Conclusion

Lumbar spinal stenosis is a narrowing of the spinal canal leading to compression of nervous and vascular structures. The surgical treatment is to relieve this compression by performing a decompressive procedure. To achieve this goal of decompression at the disc level where the narrowing primarily takes place, most parts of the ligamentum flava and the lamina (whole or parts of it) are removed. The consequences of bone and ligament removal must be considered when performing decompression for spinal stenosis. This was a prospective study of effect of decompressive laminectomy with pedicle screw instrumentation in 24 patients with lumbar canal stenosis.

“Narrowing of osteo ligamentous vertebral canal and the intervertebral foramina causing compression of the thecal sac and the caudal nerve roots, at a single vertebral level, narrowing may affect the whole canal or part of it.”<sup>27</sup> is the definition given by Postacchini for lumbar canal stenosis.

Stenosis due to degenerative changes seen anatomically is hypertrophy of articular processes, ligamentum flavum thickening, associated with posterior osteophytosis of the vertebral body.<sup>1</sup> Hypertrophy of superior articular process contributes to the deformation of central portion of the canal and narrows intervertebral portion of the nerve root canal, and also hypertrophy of the inferior articular process can lead to narrowing of the spinal canal.<sup>1</sup>

Shortening of ligamentum flavum usually occurs in the vertical and transverse planes and they get thickened. The cause of shortening is due to loss of disc height and hypertrophy of the articular process.<sup>28</sup>

The aim in surgery for LCS is to decompress the neural structure like nerve root in their extra thecal course, without compromising vertebral stability.<sup>28</sup> Utmost importance is to be given to preserve the stability of spine. Because the relief of symptoms in the leg may not satisfy the patient if the back pain persists or if becomes worse.<sup>29</sup>

Lumbar stenosis in the elderly is mainly due to a combination of facet hypertrophy and soft tissue buckling. Hence it is logical to limit the resection to only the obstructing structure, thus limiting damage and instability.

Technique of decompression in lumbar canal stenosis treated with laminectomy, pedicle screw fixation with discectomy when required gives long term satisfactory results and is generally considered to be the best and safest method of treatment. The authors are of the opinion of using this technique to provide relief to patients suffering from chronic low back pain with neurogenic claudication.

**Conflict of Interest:** None.

## References

1. Chapman MW. Spinal stenosis. In: *Chapman's Orthopaedic Surgery*, Vol-4 3rd edition. Lippincott Williams & Wilkins: 2001, 3817-3843.
2. Arbit E, Pannullo S. Lumbar stenosis: A clinical review. *Clin Orthop Relat Res* 2001;384:137-143.
3. Herkowitz H. Degenerative lumbar spondylolisthesis. *Spine (Phila Pa 1976)* 1995;20:1084-1090.
4. Bridwell KH. Lumbar spinal stenosis. Diagnosis, management, and treatment. *Clin Geriatr Med* 1994;10:677-701.
5. Garfin SR, Herkowitz HN, Mirkovic S. Spinal stenosis. AAOS Instructional Course Lectures 2000;49:361-374.
6. Hall S, Bartleson J, Onofrio B, Baker H Jr, Okazaki H, O Duffy D. Lumbar spinal stenosis -clinical features, diagnostic procedures, and result of surgical treatment in 68 patients. *Ann Intern Med* 1985;103:271-275.
7. Spivak J. Degenerative spinal stenosis. *J Bone Joint Surg* 1998;80:1053-1066.
8. Arnoldi CC, Brodsky AE, Cauchoix J, Crock HV, Dommissie GF, Edgar MA et al. Definition and classification of lumbar spinal stenosis and nerve root entrapment syndromes. *Clin Orthop* 1976;115:4-5.
9. Ciol MA, Deyo RA, Howell E, Kreif S. An assessment of surgery for spinal stenosis: time trends, geographic variations, complications, and reoperations. *J Am Geriatr Soc* 1996;44:285-290.
10. Grabian S. Current concept review, the treatment of spinal stenosis. *J Bone Joint Surg (Am)* 1980;62:308-313.
11. Arnoldi CC, Brodsky AE, Cauchoix L, Crock HV, Dommissie GF, Edgar MA, et al. Lumbar spinal stenosis and nerve root entrapment syndrome: Definition and classification. *Clin Orthop Relat Res* 1976;115:4-5.
12. Weinstein J.N, Tosteson T.D, Lurie J.D, Tosteson A, Blood E, Herkowitz H, et al. Surgical versus nonoperative treatment for lumbar spinal stenosis four-year result of the Spine Patient Outcomes Research Trial. *Spine (Phila Pa 1976)* 2007;35:1329-1338.
13. Leone A, Guglielmi, G, Cassar- Pullicino, V.N. Bonomo L. Lumbar intervertebral instability: a review. *Radiol* 2007;245:62-77.
14. Verbiest H. Results of surgical treatment of idiopathic developmental stenosis of the lumbar vertebral canal; A review of twenty-seven years experience. *J Bone joint Surg Br* 1977;59:181-188.
15. Lee CK. Lumbar spine instability (olisthesis) after extensive posterior spinal decompression. *Spine (Phila Pa 1976)*. 1983;8:429-423.
16. Frymoyer JW, Henley EN Jr, Howe J, Kuhlmann D, Matteri RE. A comparison of radiographic findings in fusion and nonfusion patient ten or more years following lumbar disc surgery. *Spine (Phila Pa 1976)*1979;4:435-40.
17. Lehmann TR, Spratt KF, Tozzi JE, Weintein JN, Reinartz SJ, el-Khoury GY, et al. Long-term follow-up of lower lumbar fusion patients. *Spine (Phila Pa 1976)*.1987;12:97-104
18. Lee CK. Accelerated degeneration of the segment adjacent to lumbar fusion. *Spine (Phila Pa 1976)*.1988;13:375-7
19. Arnoldi CC, Brodsky AE, Cauchoix J, Crock HV, Dommissie GF, Edgar MA, et al. Lumbar spinal stenosis and nerve root entrapment syndromes: Definition and classification. *Clin Orthop Relat Res* 1976;115:4-5.
20. Verbiest H. A redicular syndrome from developmental narrowing of its lumbar vertebral canal. *J Bone Joint Surg (Br)*.1954;36:230-234.
21. Ganz JC. Lumbar spinal stenosis: Postoperative results in terms of preoperative posture-related pain. *J Neurosurg* 1990;72:71-74.
22. Herron LD, Mangelsdorf C. Lumbar spinal stenosis: Results of surgical treatment. *J Spinal Disord* 1991;4:26-33.
23. Weinstein JN, Tosteson TD, Lurie JD, Tosteson A, Blood E, Herkowitz H, et al. Surgical versus nonoperative treatment for lumbar spinal stenosis four-year results of the spine patient outcomes research trial. *Spine (Phila Pa 1976)* 2010;35:1329-38.
24. Getty CJ. Lumbar spinal stenosis: The clinical spectrum and the results of operation. *J Bone Joint Surg Br* 1980;62:481-485.
25. Postacchini F, Cinotti G. Bone regrowth after surgical decompression for lumbar spinal stenosis. *J Bone Joint Surg* 1992;74B:862-869.
26. Hermansen E, Moen G, Fenstad AM, Birketvedt R, Indrekvam K. Spinous process osteotomy to facilitate the access to the spinal canal when decompressing the spinal canal in patients with lumbar spinal stenosis. *Asian Spine J* 2014;8(2):138-44. doi: 10.4184/asj.2014.8.2.138. Epub 2014 Apr 8.
27. Postacchini F. Management of lumbar canal stenosis: *J Bone Joint Surg (Br)*1996;78:154-164.
28. Postacchini F, Cinoit G, Perugia D, Gumina S. The Surgical treatmentof central lumbar stenosis. *J Bone Joint Surg (Br)* 1993;75:386.
29. Patond KR, Kakodia SC. Interlaminar decompression in lumbar canal stenosis. *Neurol India* 1999;47:286-289.

**How to cite this article:** Singh V, Bansal A, Kumar A, Rawat S, Kela BS. Outcomes of lumbar canal stenosis treated with posterior decompression and spinal instrumentation. *Indian J Orthop Surg* 2019;5(1):21-28.