

## A comparative study between cemented hemiarthroplasty and proximal femoral nail in proximal femur fractures in elderly patients

Madhuchandra P<sup>1</sup>, Sunil Santhosh G<sup>2,\*</sup>, Raju K.P<sup>3</sup>, Pawankumar KM<sup>4</sup>, Nandeesh S<sup>5</sup>

<sup>1,4</sup>Associate Professor, <sup>2,5</sup>Assistant Professor, <sup>3</sup>Professor, Dept. of Orthopaedics, BGS Global Institute of Medical Sciences, Bangalore, Karnataka, India

**\*Corresponding Author: Sunil Santhosh G**

Email: sunilsanthosh4@gmail.com

### Abstract

**Introduction:** Incidence of fractures around the hip is increasing worldwide owing to increased life span of the people and secondary to osteoporotic fragile bones. Stable intertrochanteric fractures can be easily treated by internal fixation methods. Unstable comminuted and osteoporotic intertrochanteric fractures are very difficult to treat. They can be treated by internal fixation with proximal femoral nail. But chances of implant failure and non union are high with highly osteoporotic and comminuted fractures. In such cases primary hemiarthroplasty is a useful alternative option. We have compared the outcomes of unstable intertrochanteric fractures treated with hemiarthroplasty and proximal femoral nail.

**Materials and Methods:** Our study was conducted in BGS Global Institute of Medical Sciences, Bangalore from January 2014 to December 2016 on patients who had sustained intertrochanteric fractures. It was a prospective study done for a period of two years. Patients with intertrochanteric fractures who had come to our hospital were included in our study. Patients aged more than 60 years with closed intertrochanteric fractures were included in the study. Patients were divided as group I- operated with hemiarthroplasty and group II- operated with proximal femoral nail. Functional outcome of both groups was assessed using Harris Hip scale and various parameters were compared.

**Results:** Majority of the patients were in the age group 70-79 years, 16 being females and 14 males. Commonest mode of injury was trivial fall (83.33%). Average duration of hospital stay for hemi-arthroplasty patients was 14.33 days and for PFN patients was 11.86 days. 15 patients had associated conditions like diabetes or hypertension. Average intra-operative blood loss was 516.66 ml for hemi-arthroplasty and 187.33 ml for PFN. Average operating time for hemi-arthroplasty was 80 minutes whereas for PFN was 83.33 minutes. Mean harris hip score at the end of one year for hemi-arthroplasty was 76.46 and for PFN was 77.8.

**Conclusion:** The outcomes of both the modalities are almost equal. PFN has an advantage of shorter operative time, less blood loss, lower hospital stay with no difference in functional outcome or general complications as compared to hemiarthroplasty. Major advantage of PFN is patients treated with PFN can squat and sit cross legged after fracture union. Hemiarthroplasty does provide a stable, pain-free, and mobile joint with a very low complication rate as seen in our study; however a larger prospective randomized study with longer follow up comparing the use of PFN against primary hemi-arthroplasty for proximal femur fractures needs to be done.

**Keywords:** Intertrochanteric fractures, Hemiarthroplasty, Proximal femoral nail.

### Introduction

Fractures of neck of femur and intertrochanteric fractures are very commonly seen in the geriatric age group. There is a rise in the incidence of these fractures due to increase in the life span of the people and osteoporosis. There is expected to be doubling in the incidence of these fractures in the years coming ahead. As per the literature age is an important risk factor,<sup>1</sup> due to which the incidence of these fractures is high. However, there is increase of these fractures in younger individuals also due to increased incidence of road traffic accidents. Fractures around the hip are more common among females,<sup>2</sup> this could be due to post-menopausal osteoporosis. Hip fractures should be fixed early and patient should be mobilized early in order to avoid the complications such as bed sores, pulmonary complications.

Management of these fractures is very difficult because of the osteoporotic nature of the bone. Incidences of implant failure and fracture related complications are very high in proximal femoral fractures. Different fixation methods have been described in the literature for the management of these proximal femoral fractures. Commonly used fixation methods for these fractures are hemiarthroplasty-cemented

or uncemented,<sup>3</sup> internal fixation with Dynamic Hip Screw, Proximal Femoral Nail,<sup>4-6</sup> AO screws. Results of these surgeries have variable success and failure rates. Of these surgeries, most commonly performed surgeries are proximal femoral nail, Dynamic Hip Screw and hemiarthroplasty. Among internal fixation devices Dynamic Hip Screw usage has been restricted to only stable fractures because of higher failure rates among unstable fractures. Proximal femoral nail is the implant of choice in unstable fractures. However owing to the osteoporotic nature of the bone, incidences of failures are seen in patients fixed with proximal femoral nail.<sup>7,8</sup> Hence primary hemireplacement is an alternative solution to these fractures. When cemented hemiarthroplasty is done, it will give more stable fixation and early mobilization can be done. In our study, we have compared the outcomes of cemented hemiarthroplasty and proximal femoral nail in proximal femur fractures in elderly patients.

### Materials and Methods

Our study was conducted in BGS Global Institute of Medical Sciences, Bangalore from January 2014 to December 2016 on patients who had sustained intertrochanteric fractures. It was a prospective study done

for a period of two years. Patients with intertrochanteric fractures who had come to our hospital were included in our study. Patients aged more than 60 years with closed intertrochanteric fractures were included in the study. Compound fractures and patients younger than 60 years were excluded from the study. A total of 30 patients were selected for the study in a randomized manner. Patients were assessed for any other associated comorbidities such as diabetes, hypertension and ischemic heart disease. Patients were screened radiologically to know the fracture geometry and pre operative planning. Patients were divided into two groups. Cemented hemiarthroplasty was performed in patients belonging to group I patients. In group II patients, proximal femoral nailing was done.

### Operative Procedure

#### Group I: (Hemiarthroplasty group)

We placed the patient in the true lateral position (Fig. 1) and we used Moore's posterior approach for the surgery, because it will not affect the hip abductor mechanism. We made a 10-cm to 15-cm curved incision centered on the posterior aspect of the greater trochanter. We retracted the fibers of the split gluteus maximus and the deep fascia of the thigh. We detached the short external rotators close to their femoral insertion. Capsule was incised and head extraction done. Head size was measured and femoral canal preparation done. Cemented hemiarthroplasty was done using bipolar prosthesis (Fig. 2). Wound was closed over a suction drain.

#### Group II: (Proximal Femoral nail group)

Patient tied to fracture table in supine position and fracture reduced under c arm guidance (Fig. 3&4). After preparation and draping, a 5cm incision made extending proximally from the tip of greater trochanter (Fig. 5), gluteal muscles split in its line. Entry point made using bone awl and guide wire inserted and nail inserted over guide wire. Proximal and distal locking done. Wound was closed in layers.

Intravenous antibiotics were given for 48 hours in both the groups. Static quadriceps exercises were started on the same day. Patients were mobilized from the next day with full weight bearing with walker support and knee range of movements were started. All patients were followed up regularly at 12<sup>th</sup> post operative day, then six weeks and twelve weeks and then at six months and one year respectively. Radiological evaluation was done at each follow up and assessed for fracture union, alignments and implant failures. Functional outcome was assessed using Harris Hip scoring system. Both the groups were compared for various intra operative and post operative parameters.

Sample T test was performed to compare the two groups for various parameters.

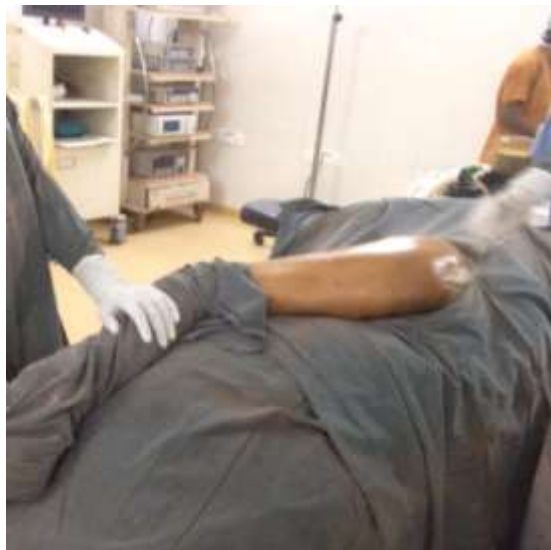


Fig. 1: Patient positioning for hemiarthroplasty

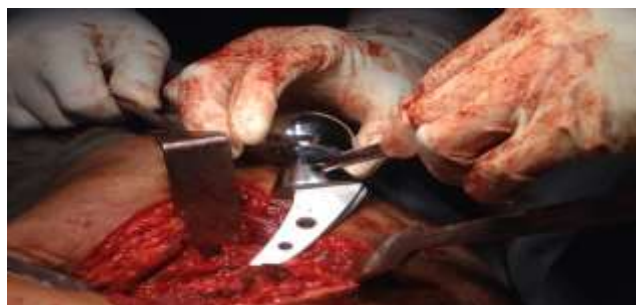
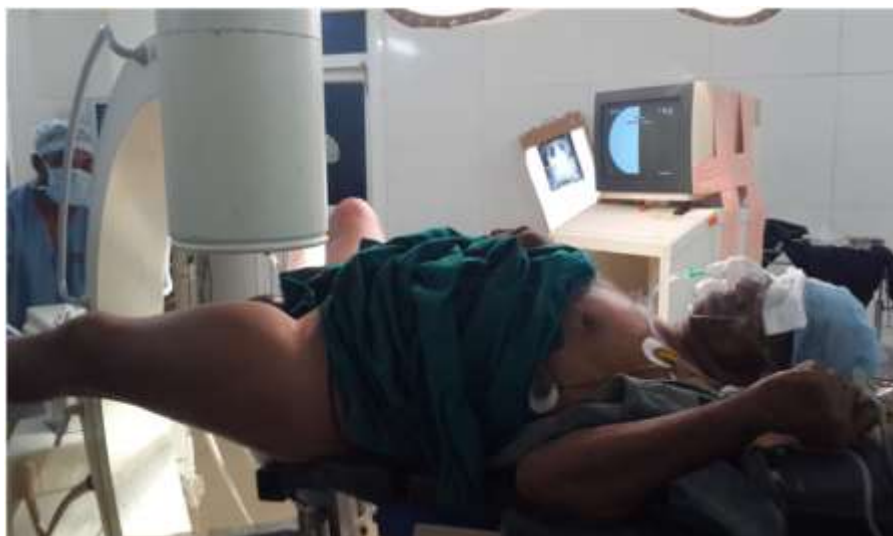
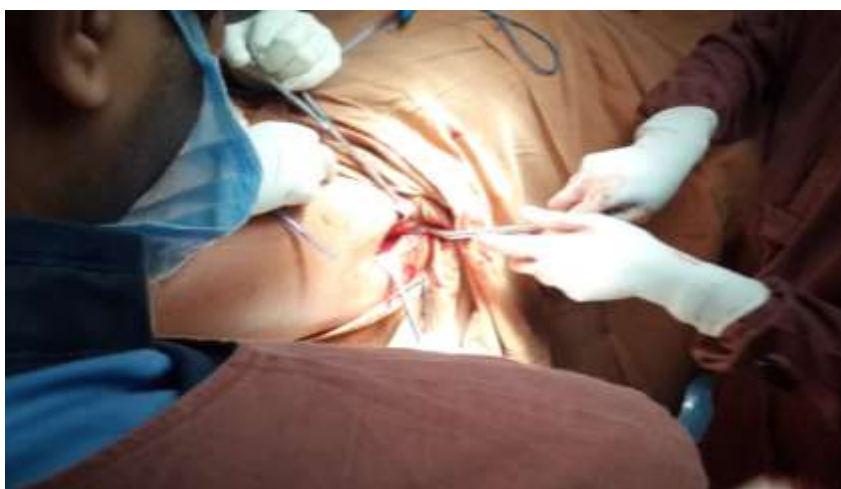Fig. 2: Prosthetic positioning



Fig. 3: PFN instrumentation set



**Fig. 4: Patient positioning for PFN**



**Fig. 5: Showing incision and entry point making**

### Results and Analysis

Our study consisted of 30 patients of pertrochanteric fractures treated surgically either by proximal femoral nail and bipolar hemiarthroplasty. Following observations were made in our study. Age of all the patients in this study fell above 65 years. 18 patients (60%) were in the age group between 70 and 79 years and 7 patients (23.33%) were in the age group 60 to 69 years. There were 5 patients (16.6%) in the age group of 80 and more years (Table 1). In our study, out of the 30 patients there 16 were females accounting to 53.33% and 14 male patients making up the remaining 46.66%. There were 8 females (53.33%) and 7 males (46.66%) in hemiarthroplasty as well as PFN groups.

The average duration of hospital stay for group I (hemiarthroplasty group) was 14.33 days with a range of 25 to 7 days. Except for one patient with contralateral distal radius fracture, all were ambulatory with the help of a cane at the time of discharge. The average duration of hospital stay for group II (PFN group) was 11.86 days with a range of 21 to 8 days. The duration of hospital stay is less in our series as the patients were mobilized early (Fig. 6)

25 out of the 30 fractures (83.33%) occurred due to fall. The fall was mostly low energy trauma (fall <1 m or fall from standing height). The rest of the 5 fractures in our study occurred due to road traffic accidents (16.66%). Left side involvement was more commonly seen than the right side in this study group. Left side was involved in seventeen patients making up for 56.66% of the fractures and the right was involved in thirteen patients accounting for 43.33% of the fractures. None of the patients had bilateral fractures (Fig. 7).

In our study, there were no patients with Singh's grade I osteoporosis, 12 patients (40%) with Singh's grade II osteoporosis, 9 of whom were treated with hemiarthroplasty and 3 with PFN. 15 patients (50%) had grade III osteoporosis, out of which 6 were treated with hemiarthroplasty and 9 were treated by PFN. 3 patients had grade IV osteoporosis, all of whom were treated with PFN. None of the patients had grade V or VI osteoporosis (Table 2).

15 patients (50%) out of 30 had associated conditions like diabetes mellitus, hypertension, COPD etc. at the time of admission in our hospital. 2 patients had a distal end of

radius fracture at the time of fall. One female patient sustained a fracture of both bones of the forearm of the same side due to a road traffic accident.

There was a significant difference between the amount of blood loss between hemiarthroplasty and PFN, PFN being a less invasive and shorter procedure. The average amount of blood lost in hemiarthroplasty cases was 516.66 ml, ranging from 400 ml to 650 ml. The average amount of blood lost in PFN cases was 187.33 ml, ranging from 130 ml to 250 ml (Table 3). The average duration of surgery, which is time from skin incision to skin closure, was 80 minutes for hemiarthroplasty (group 1), ranging from 70 to 100 minutes. The average duration of surgery for PFN (group 2) was 73.33 minutes, ranging from 60 to 90 minutes. Functional results of the surgeries were graded on the basis of Harris hip scale. It is a 100 point scale with 44 points for pain, 47 for function, 5 for range of motion and 4 for absence of deformity. The results were assessed at 1,3,6 months and 1 year (Fig. 8). After a follow up of one year, in our hemiarthroplasty group (group 1), 2 patients had poor result, 9 patients had fair result, 4 had good (Fig. 9) and no patient had an excellent result. In our PFN group (group 2), 2 patients had poor result, 9 patients had fair result, 3 patients had good results and 1 patient had excellent result (Fig. 10a to 10d).

Overall, we had 4 patients (13.33%), with poor result, 18 patients (60%) with fair result, 7 patients (23.33%) with good result and 1 patient (3.33%) with excellent result in our study group of 30 cases (Table 4).

Out of the 30 patients operated, 2 patients (one from each group) got infected. The infection was superficial and was well controlled by oral antibiotics. Over all 5 patients had insignificant limb length discrepancy (less than 2 cm). 3 patients in hemiarthroplasty group and 2 patients in PFN group had limb length discrepancy. In one patient from PFN group (group 2), the hip pin backed out after four months of surgery, which had to be removed.

Two sample t-test was used to compare the outcomes in the two groups. As the table shows, there was no significant association between the age, duration of hospital stay and Harris hip score with the modality of treatment. On the other hand, there was a significant difference in the intraoperative blood loss between hemiarthroplasty and PFN (P value < 0.001) (Table 5).

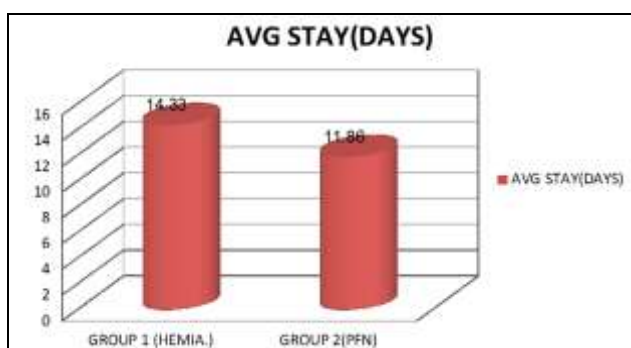


Fig. 6: Duration of hospital stay of patients in both the groups

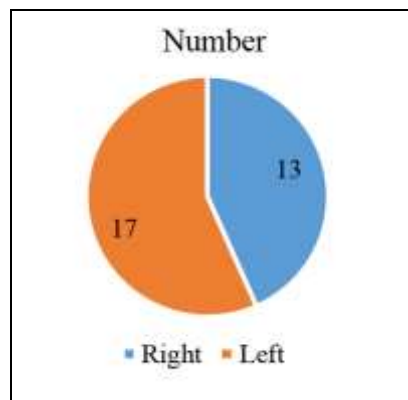


Fig. 7: Injury laterality

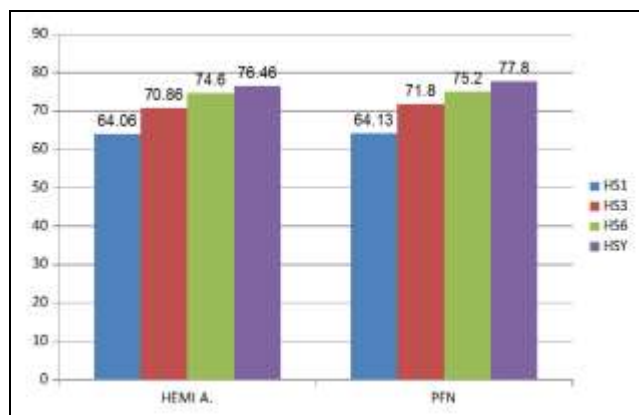


Fig. 8: Functional Results comparison of both the groups

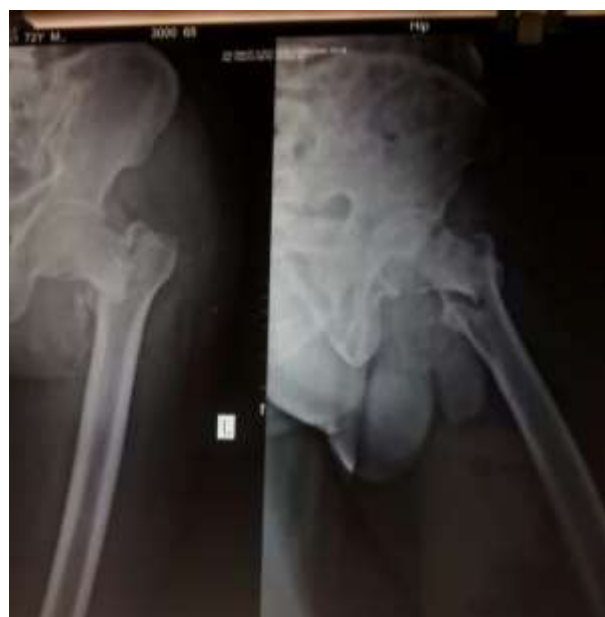

Fig. 9a: Pre operative X-ray

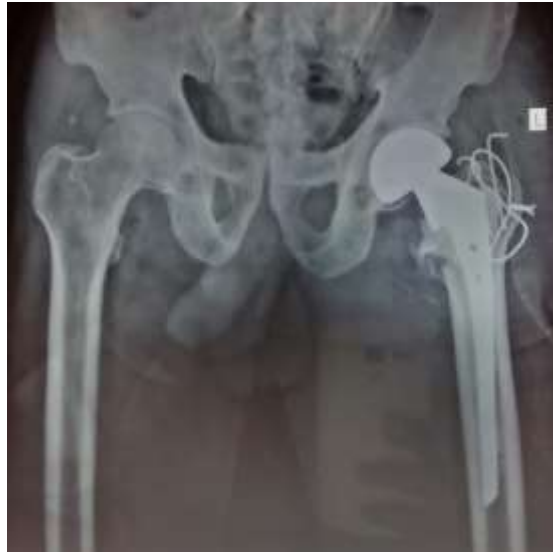

Fig. 9b: Post operative X-ray with cemented hemiarthroplasty

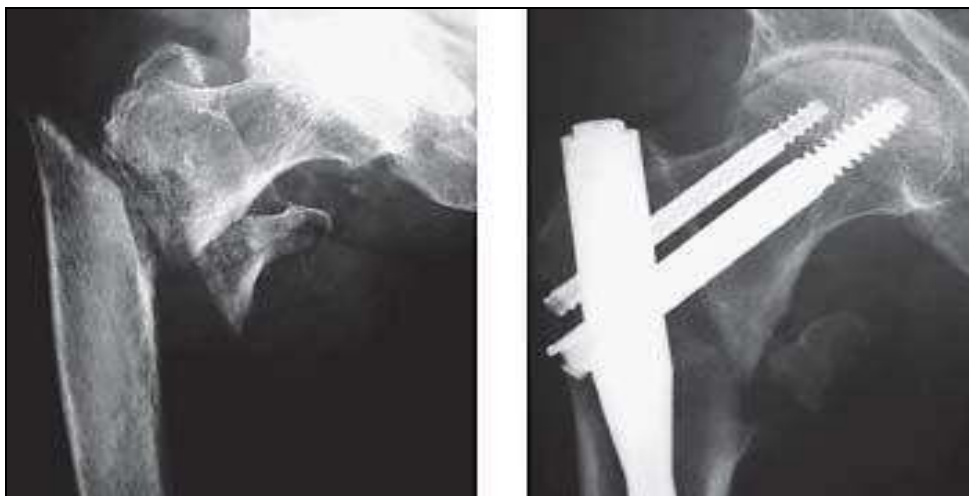


Fig. 10 a: Showing preoperative and immediate post operative X-ray with PFN

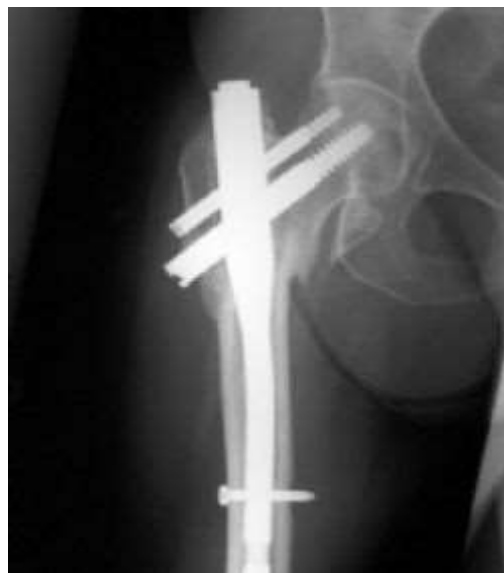

Fig. 10b: Showing union at the end of six months

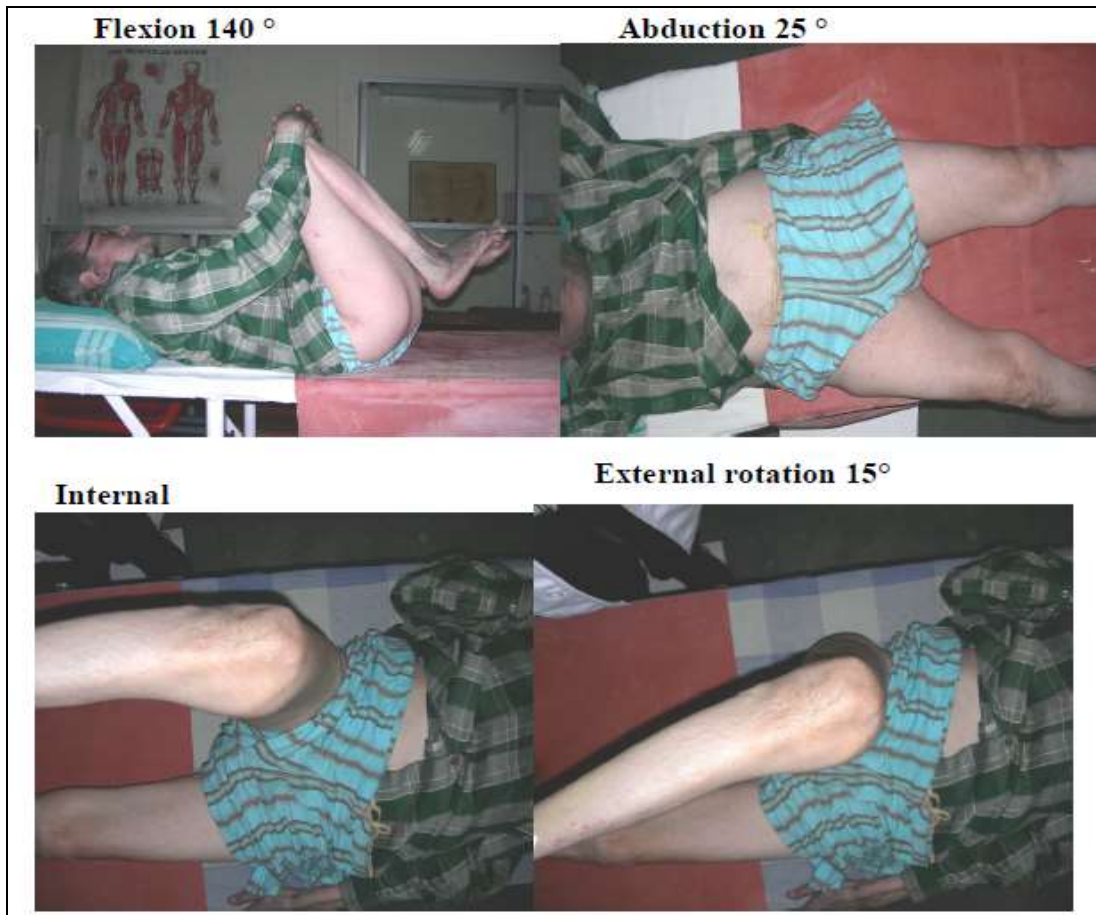


Fig 10c: Showing range of movements after PFN

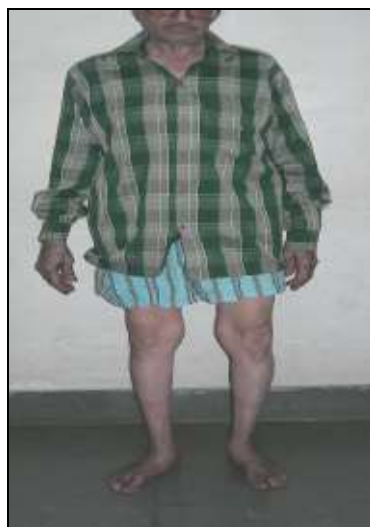

Fig. 10d: Full weight bearing after PFN

Table 1: Age wise distribution

Age (years)	Total	Group 1 (HEMI- Arthroplasty)	Group 2 (PFN)
60-69	7	2	5
70-79	18	9	9
80 & Above	5	4	1

**Table 2: Singh's index in different cases belonging to both groups**

Singh's index	Group 1 (HEMI A.)	Group 2(PFN)	Total
I	Nil	Nil	Nil
II	9	3	12
III	6	9	15
IV	Nil	3	3
V	Nil	Nil	Nil
VI	Nil	Nil	Nil

**Table 3: Comparison of blood loss in hemiarthroplasty and PFN groups**

Blood Loss	Average in Millilitres (ml)
Group 1 (HEMI A.)	516.66
Group 2 (PFN)	187.33

**Table 4: Comparison of functional outcome in both groups**

Outcome (HSY)	Poor	Fair	Good	Excellent
HEMI A.	2	9	4	0
PFN	2	9	3	1

**Table 5: Comparison of various parameters in both the groups**

S. No.	Outcome	HEMI-Arthroplasty Group (N = 15)	PFN Group (N = 15)	P Value (2 Sample T-Test)	Inference
		Mean (S.D.)	Mean (S.D.)		
1	Age (Yrs.)	75(5.33)	71.33(3.92)	T = 2.34, P = 0.27	Not Significant
2	Blood Loss (ml)	516.66(66.61)	187.33(37.31)	T = 16.71, P < 0.001	Highly Significant
3	Stay in Hospital (days)	14.33(4.09)	11.86(3.06)	T = 1.87, P = 0.07	Not Significant
4	Harris Hip Score (1yr)	76.46(7.77)	77.8(6.80)	T = 0.5, P = 0.61	Not Significant

## Discussion

Surgical fixation of unstable intertrochanteric fractures remains a controversial issue. Although many internal fixations have come in the recent years, no particular implant has been accepted universally for fracture fixations. Most common disadvantage with internal fixation is high number of implant failures and screw cut outs. So primary hemiarthroplasty for such fractures gives an additional treatment option. However it has got its own disadvantages such as dislocation and intra operative complications.

Geiger et al<sup>9</sup> compared the outcome of primary hemireplacement, internal fixation with proximal femoral nail and Dynamic hip screw for intertrochanteric fractures found less mortality rate and blood loss with proximal femoral nail. However higher rates of non union and implant failures were seen.

Primary hemireplacement in general is not done for fresh intertrochanteric fractures. However when there is comminution and four part fractures, chances of implant failures and screw cutout are high. In such cases primary hemireplacement is a better alternative. It also overcomes disadvantages of non union and implant failures.<sup>10-12</sup>

In our series, patients with Singh index<sup>13</sup> >III and with traction x-ray showing satisfactory alignment in acceptable position were treated with PFN, where as patients with Singh index <III & with traction x-ray showing loss of

integrity of postero-medial cortex and inadequate alignment were treated with cemented bipolar hemiarthroplasty.

In our study, we had three patients in group 1 and two patients in group 2 with limb length discrepancy which was less than 1.5 cms, which was compensated by shoe raise. In our study, we have done patient each in both the groups with superficial infection which subsided with iv antibiotics.

We compared our results with other established studies for trochanteric fractures treated with hemiarthroplasty or PFN. Most of our patients were of elderly age group. The mean age of patients undergoing hemiarthroplasty was 75 years, as compared to 82 years in Haentjens.<sup>14</sup> The mean age for PFN group was 71.33 years, as compared to 72 years in Tyllianakis et al.<sup>15</sup>

The mean blood loss in our hemiarthroplasty group was 516.66 ml. The mean blood loss in Haentjens group was 680 ml. The mean blood loss in our PFN group was 187.33ml as compared to 320 ml in a study by Pajarinen et al.<sup>16</sup> and 0.5 to 1.8 units (175ml to 630 ml) in Tyllianakis et al.<sup>15</sup>

The duration of surgery was 80 min for hemiarthroplasty group in our study. In Haentjens<sup>14</sup> study, the duration of surgery was 82 plus/minus 4 min. The mean operating time for our PFN group was 73.33 min as compared to 68 min in Tyllianakis et al.

Out of 30 patients in our study, we had 4 poor results, 18 fair, 7 good and 1 excellent result overall. Further, in our

hemiarthroplasty group, we had 9 fair (60%), 4 good (13.33%) and 2 poor (13.33%) as compared to 75-84% as excellent, very good or good and 17-25% as fair poor or bad as compared to Haentjens.

Hemiarthroplasty patients were allowed full weight bearing significantly earlier than the internal fixation patients. Broos et al.<sup>17</sup> concluded that the operative time, blood loss, and mortality rates were comparable between the two groups, with a slightly higher percentage (73% versus 63%) of those receiving a prosthesis considered to be pain free. The functional outcome was comparable between both groups. Stappaerts et al.<sup>18</sup> found no difference between two groups except a higher transfusion need in the replacement group. In our series the average blood loss in hemiarthroplasty group was 516.66 ml with 2 patients requiring postoperative blood transfusion and there was no incidence of dislocation.

Conflicting reports about postoperative mortality in cases with primary hemiarthroplasty are cited in the literature. Kesmezacare et al.<sup>19</sup> reported postoperative mortality in 34.2% after a mean of 13 months and in 48.8% after a mean of 6 months in patients treated with internal fixation and endoprosthesis, respectively. Other studies have shown no differences in postoperative mortality in two groups. In present series, no patient died in a follow up of one year.

Hardy et al.<sup>20</sup> reported early weight bearing without excessive collapse in cases with comminuted intertrochanteric fractures fixed with intramedullary nailing. However, there is only one study by Kim et al.<sup>21</sup> which compares the calcar replacement prosthesis with intramedullary nailing in a prospective study involving two groups of 29 patients. They could not find any significant difference concerning the functional outcomes, but the cut-out rate of the hip screw was 7% in their patients. The Cochrane database analysis of relevant studies concluded that there is insufficient evidence to prove that primary arthroplasty has any advantage over internal fixation. However, they also mentioned that there were only two randomized trials studied and both had methodological limitations, including an inadequate assessment of the longer term outcome.

## Conclusion

Unstable intertrochanteric fractures pose a great challenge to surgeons because of the complexity of the fracture geometry and osteoporotic nature of the bone. Pre-operative planning is very important in successful management of these fractures. Patients with good bone stock and satisfactory alignment in acceptable position can be treated with PFN. Patients with poor bone stock and traction X-ray showing loss of integrity of postero-medial cortex and inadequate alignment should be treated with cemented bipolar hemi-arthroplasty.

The outcomes of both the modalities are almost equal. PFN has an advantage of shorter operative time, less blood loss, lower hospital stay with no difference in functional outcome or general complications as compared to

hemiarthroplasty. Major advantage of PFN is patients treated with PFN can squat and sit cross legged after fracture union. Hemiarthroplasty does provide a stable, pain-free, and mobile joint with a very low complication rate as seen in our study; however a larger prospective randomized study with longer follow up comparing the use of PFN against primary hemiarthroplasty for proximal femur fractures needs to be done.

**Conflicts of Interest:** None.

**Source of Funding:** None.

## References

- Melton JL, Ilstrup DM, Riggs BL, Beckenbaugh RD. Fifty year trend in hip fracture incidence. *Clin Orthop* 1982;167:131.
- Melton JL. Hip fractures: A worldwide problem today and tomorrow. *Bone* 1993;14S1-S8.
- Rahul M, Salunkhe, Shrirang Limaye, Samar K Biswas, Rahul P Mehta. Cemented hemiarthroplasty in proximal femoral fractures with severe osteoporosis- a case series. *Med J Dr. D.Y. Patil Univ* 2012;5(1):36-42.
- Sudan M, Sadowski C. Peritrochanteric fractures. Is there an advantage of intramedullary nail? *J Orthop Trauma* 2002;16:386-393.
- Christian Boldin, Franz J Seibert, Florian Fankhauser. The proximal femoral nail (PFN)—a minimal invasive treatment of unstable proximal femoral fractures. *Acta Orthop Scand* 2003;74(1):53–58.
- Daniel F.A. Menezes, Axel Gamulin. Is the Proximal femoral nail a suitable implant of all the trochanteric fractures? *CORR* 2005;439:221-227.
- Woo-kie Min, Shin – Yoon. Proximal femoral nail for the treatment of Reverse obliquity intertrochanteric fractures compared with Gamma nail. *J Trauma* 2007;73:1054–1060.
- MSG Ballal, N Emms, G Thomas. Proximal femoral nail failures in extra capsular fractures of the hip. *J Orthop Surg* 2008;16(2):146-149.
- Geiger F, Zimmermann-Stenzel M, Heisel C, et al. Trochanteric fractures in the elderly: the influence of primary hip arthroplasty on 1-year mortality. *Arch Orthop Trauma Surg* 2007;127(10):959-966.
- Kim S-YK, Yong-Goo H. Cementless calcar-replacement hemiarthroplasty compared with intramedullary fixation of unstable intertrochanteric fractures. A prospective, randomized study. *J Bone Joint Surg Am* 2005;87(10):2186-2192.
- Rosenfeld RT, Schwartz DR, ALAH. Prosthetic replacement in trochanteric fractures for the treatment of femur. *J Bone Joint Surg Am* 1973;55:420.
- Haentjens P, Casteleyn PP, Opdeecam P. Primary bipolar arthroplasty or total hip replacement for the treatment unstable intertrochanteric and subtrochanteric fractures in elderly patients. *Acta Orthop Belg* 1994;60:124-128.
- Singh M. Changes in the trabecular pattern of upper end of the femur as an index of osteoporosis. *JBJS* 1970;52A:457-467.
- Haentjens P, Casteleyn PP, Opdeecam P. Primary bipolar arthroplasty or total hip replacement for the treatment unstable intertrochanteric and subtrochanteric fractures in elderly patients. *Acta Orthop Belg* 1994;60:124-128.
- Tyllianakis M, Panagopoulos A, Papadopoulos A, Papisimos S, Mousafiris K. Treatment of extracapsular hip fractures with the proximal femoral nail (PFN): Long term results in 45 patients. *Acta Orthop Belg* 2004;70:444-454.



16. Pajarinen J, Lindhal J, Michelssn O, Savolainen V, Hirvensalo E. Pertrochantric fractures treated with a dynamic hip screw or a proximal femoral nail: a randomized study comparing post operative rehabilitation.
17. Broos PL, Rommens PM, Deleyn PR, Geens VR, Stappaerts KH. Pertrochanteric fractures in the elderly: Are there indications for primary prosthetic replacement? *J Orthop Trauma* 1991;5:446–451.
18. Stappaerts KH, Deldycke J, Broos PL, Staes FF, Rommens PM, Claes P. Treatment of unstable peritrochanteric fractures in elderly patients with a compression hip screw or with the Vandeputte (VDP) endoprosthesis: A prospective randomized study. *J Orthop Trauma* 1995;9:292–297.
19. Kesmezacar H, Ogut T, Bilgili MG, Gokay S, Tenekecioglu Y. Treatment of intertrochanteric femur fractures in elderly patients: internal fixation or hemiarthroplasty. *Acta Orthop Traumatol Turc* 2005;39:287–294.
20. Hardy DC, Descamps PY, Krallis P, Fabeck L, Smets P, Bertens CL, et al. Use of an intramedullary hip-screw compared with a compression hip-screw with a plate for intertrochanteric femoral fractures: A prospective, randomized study of one hundred patients. *J Bone Joint Surg Am* 1998;80:618–630.
21. Kim SY, Kim YG, Hwang JK. Cementless calcar-replacement hemiarthroplasty compared with intramedullary fixation of unstable intertrochanteric fractures: A prospective, randomized study. *J Bone Joint Surg Am* 2005;87:2186–2192.

**How to cite this article:** Madhuchandra P, Santhosh SG, Raju K.P, Pawankumar KM, Nandeesh S. A comparative study between cemented hemiarthroplasty and proximal femoral nail in proximal femur fractures in elderly patients. *Indian J Orthop Surg* 2019;5(1):57-65.