

Implant supported prosthesis with guided bone regeneration & laser assisted perioplastic surgery: a case report

Shivam Yadav^{1,*}, Krishna Kumar Gupta², Chetan Chandra³, Shubham Kumar⁴, Akanksha Mishra⁵

¹Lecturer, ³Reader, ^{4,5}PG Student, Sardar Patel Post Graduate Institute of Dental & Medical Sciences, Lucknow, ²Professor & Head, Dept. of Periodontology, Vyas Dental College & Hospital, Jodhpur

***Corresponding Author:**

Email: shivam0710@gmail.com

Abstract

The Guided Bone Regeneration (GBR) treatment concept aims for regeneration of osseous defects predictably via the application of occlusive membranes, which mechanically exclude non-osteogenic cell populations from the surrounding soft tissues, thereby allowing osteogenic cell populations originating from the parent bone to inhabit the osseous wound. The development of techniques for guided bone regeneration (GBR) has led to the possibility of placing implants in the areas where earlier it was not possible due to deficient bone. Further, in the recent years LASERs have also emerged as a powerful and efficient treatment tool for carrying out perioplastic and soft tissue corrections surgeries. The present case report describes a case where implant supported prosthesis was delivered in the minimal available bone and further esthetic enhancement was done by correcting the abnormal frenal attachment by doing LASER assisted perioplastic surgery.

Key Words: Guided bone regeneration, Barrier membrane, Alloplastic bone Graft Perioplastic Surgery, LASER.

Introduction

The development of techniques for guided bone regeneration (GBR) has influenced the possibility of installing implants for fixed prosthesis in the cases where it was not possible due to deficient bone. In periodontally compromised patients severely resorbed alveolar processes are often found after tooth loss, hampering the placement of implants for restorations. When horizontal alveolar bony defects are present, bone regeneration prior to implant placement or during the surgical phase of implant instalment should be considered.^(1,2)

Implants can be placed into deficient alveolar ridges, leading to bone defects around the implants. These bone defects have been classified as dehiscence, infrabony and fenestration defects. In conjunction with the placement of the implant, GBR procedures have been applied and have resulted in successful coverage of the previously exposed implant surfaces with bone. Such regeneration of bone in conjunction with the placement of dental implants has become an accepted and successful clinical procedure.

There have been several published case reports where implant placement was made possible in relatively deficient bone with the aid of successful bone augmentation by GBR. This case report describes a case where implant supported prosthesis was delivered in the minimal available bone and further esthetic enhancement was done by LASER assisted perioplastic surgery.

Case report

A 36 year old male patient reported to out patient clinics Department of Periodontology and Implantology Sardar Patel Post Graduate Institute of Dental and

Medical Sciences Lucknow with a complaint of missing tooth in upper front region since two years and desired for replacement of the same. Extraoral examination did not reveal any abnormalities and there were no palpable regional lymph node. A comprehensive intraoral examination was performed to assess his overall oral health which revealed a neglected mouth with poor oral hygiene as reflected by heavy stains, plaque and calculus accumulation. Further 11 of the patient was missing, with an anterior open bite and papillary frenal attachment. Except for plaque and calculus associated chronic gingivitis, patient had no overt periodontal disease, teeth mobility or loss of attachment in general (Fig. 1). On taking detailed dental history we came to know that 11 of the patient was extracted by some regional dentist two years back due to the reason of endodontic treatment failure in the tooth. Medical history was non contributory.

Diagnostic casts of the patient were prepared for analysis and diagnosis of the case. Further for the purpose of precise diagnosis patient was also advised for Dentscan imaging (Fig. 2 & 3).

After critically evaluating the diagnostic casts and images of dentascan patient was offered with Implant supported prosthesis for the purpose of rehabilitation to which he agreed readily.

The bucco-lingual width available was 3.8mm and the length available was 13mm, the type of bone estimated was D2. Hence keeping the dimensions in view the Implant selected for the purpose of rehab was ADIN TOURAEG OS of size 11.5 x 3.5 mm.

The constrains in the path of delivering successful Implant supported prosthesis were the coronally resorbed buccal cortical plate firstly which could have caused problem at the time of Implant placement (Fig.

4) and secondarily the papillary frenal attachment which could have hindered in the creation of esthetic soft tissue profile after prosthetic completion of prosthetic phase. Hence for the purpose of rehabilitation a treatment plan was developed calling for a GBR procedure and simultaneous placement of a dental implant. The patient provided informed consent for the same.

The patient was carefully treated periodontally before surgery to avoid reservoirs of periodontopathogens. After achieving adequate local anaesthesia full thickness mucoperiosteal flap was raised following a remote incision from the implant site and crevicular incision with respect to the adjacent tooth (Fig. 5). The resorbed portion of bone was identified and the defect on the buccal cortical plate was located. The osteotomy procedure was carried out very carefully without further damaging the buccal cortical plate (Fig. 6). Osteotomy was completed and implant was placed without further damaging the residual bone. At this stage after placement of implant the bone on the buccal side was so thin that the threads of Implant were partially visible. Therefore, if guided bone regeneration procedure would not have been carried out the implant site would have developed dehiscence after a span of time. For the purpose of GBR the recipient cortical plate was perforated with a round bur to induce bleeding in the area. Alloplastic Hydroxylapatite bone was placed over the area and was covered using resorbable collagen membrane and the site was sutured without tension using 3'0 silk suture (Fig. 7, 8 & 9).

The sutures were removed after ten days and the implant site was left undisturbed for six months to achieve maximum bone fill and osseointegration. IOPA radiographs were taken every month to estimate the progress of osseointegration and bone fill. After six months the site was analyzed again for formation of new bone using a bone gauge and the buccolingual width estimated was 5 mm that was 3.8mm at the time of implant placement which denotes 1.2 mm of new bone formation.

The site was reopened and healing abutment was placed (Fig. 10) and after two weeks crown was delivered to the patient. But still the papilla lost in the region of lost tooth was not recreated completely because of the abnormal pull resulting from the papillary frenal attachment (Fig. 11 & 12). For the purpose of correcting the abnormal frenal pull LASER assisted frenectomy was planned. Topical anaesthesia was sprayed on the site and the frenectomy procedure was performed with a diode LASER at 3 watt power and wavelength of 810 nm on continuous mode (Fig. 13 & 14).

The wound healed uneventfully and the abnormal frenal pull was relieved and gingival frenal margin was established. The patient was recalled after two months and the postoperative results were analyzed. The

missing tooth of the patient was replaced, the frenal margin was corrected and the lost inter dental papilla was recreated (Fig. 15). The patient was also advised to undergo correction of the anterior open bite which was not accepted by him due to time constraints. The patient was fully satisfied by the treatment outcome.

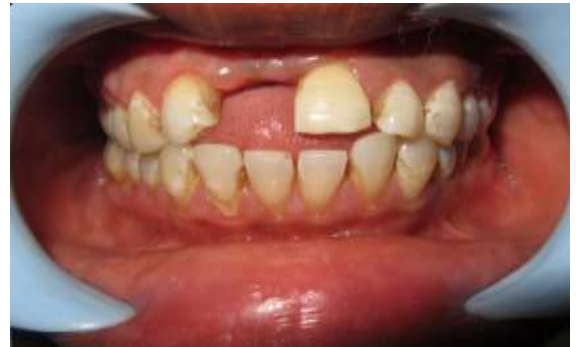

Fig. 1: Pre-operative

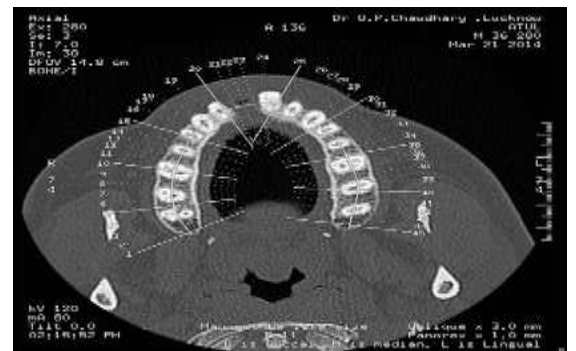

Fig. 2: Dentascan

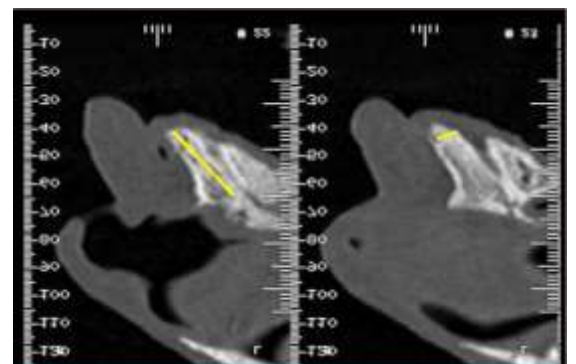


Fig. 3

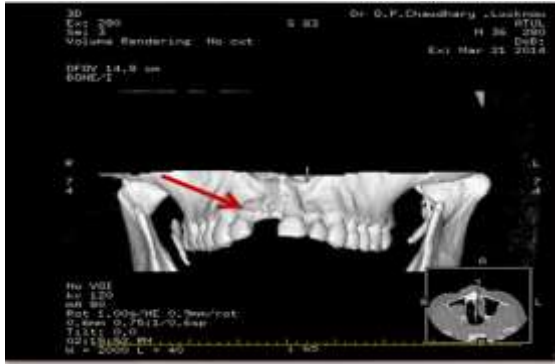

Fig. 4: 3D reconstructed image of defect




Fig. 8: Collagen membrane

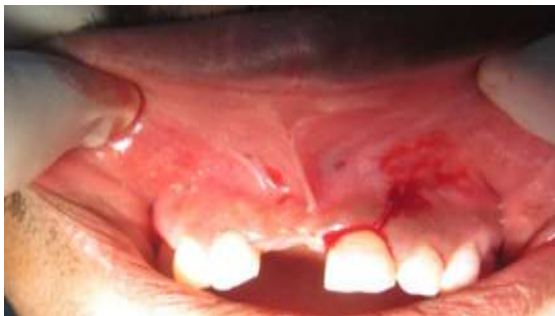

Fig. 5: Incision

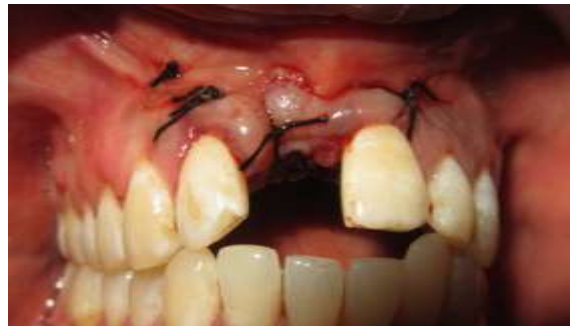

Fig. 9: Sutures placed

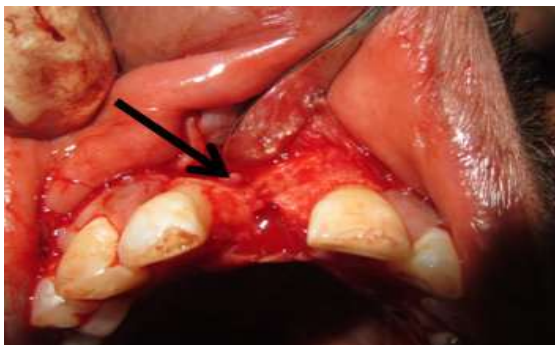


Fig. 6: Flap reflected, Defect located & careful osteotomy done

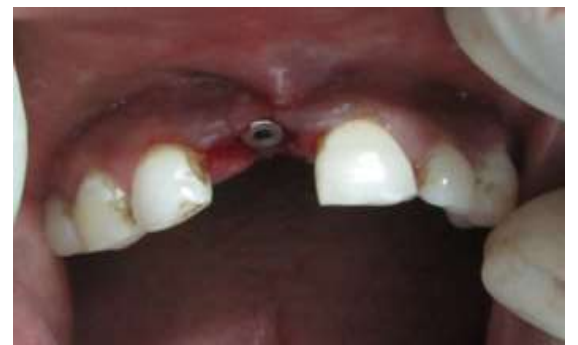

Fig. 10: Gingival former placed

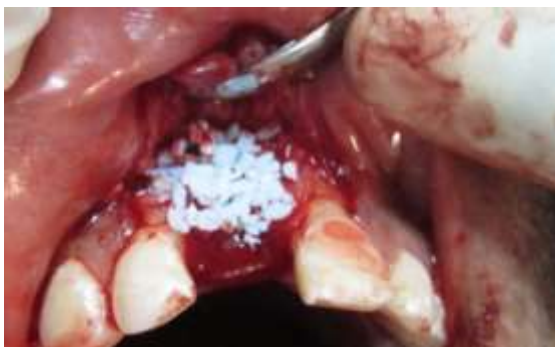

Fig. 7: Bone Graft Placed

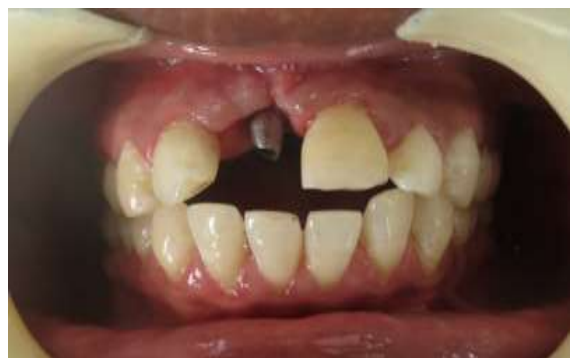

Fig. 11: Abutment placed

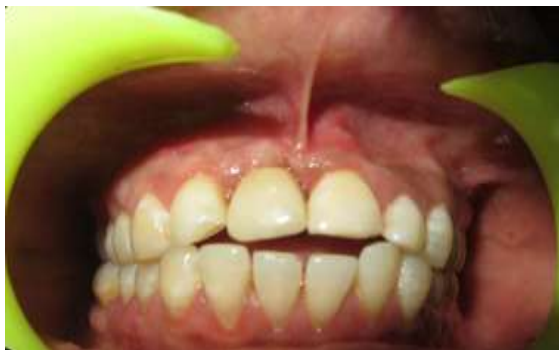

Fig. 12: Prosthesis delivered but still abnormal frenal pull present

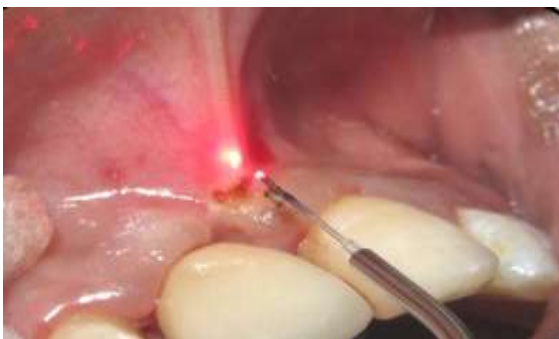

Fig. 13: Frenectomy done by laser

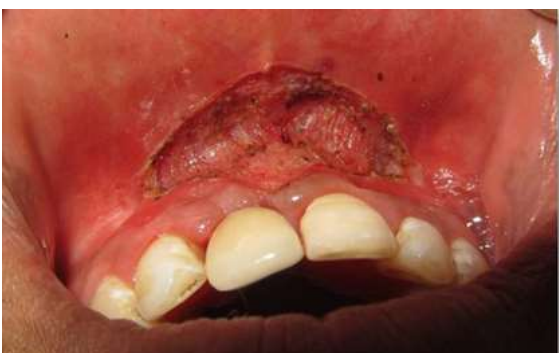

Fig. 14: Frenectomy done

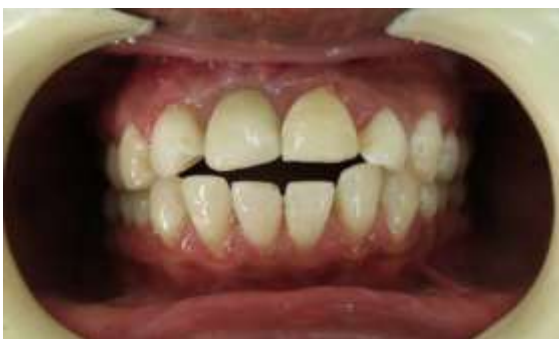

Fig. 15: Post operative picture

Discussion

GBR^(4,5) is a regenerative procedure which is based on the principle of guided tissue regeneration and involves the placement of a barrier membrane to protect

the blood clot and create a secluded space around the osseous defect enabling bone regeneration without competition from other tissues. Several barrier membranes and bone grafting materials have been successfully used in different animal and human studies to regenerate the lost bone around the implants.⁽⁶⁾

Autogenous bone is considered the gold standard for most applications, including GBR, as it contains osteocytes, stem cells and growth factors that leads to superior osteogenic and osteoinductive properties. However the need for a second surgery to harvest autogenous bone, its limited availability, and concerns about donor-site morbidity and graft resorption all affect its use.⁽⁷⁾

Further clinical studies have demonstrated that allogeneic bone grafts in conjunction with GBR procedures can be a viable alternative to autogenous grafts.^(8,9)

In the present case GBR alloplastic bone graft material Hydroxyapatite was used to achieve significant amount of bone regeneration. Hydroxyapatite has a calcium to phosphate ratio of 1.67, similar to that found in bone material. Hence it facilitated us in achieving better regeneration in comparison to any other alloplastic bone graft material. Various non resorbable as well as resorbable membranes have been used by different investigators to obtain GBR. In a previous study using a similar approach, very good bone fill at immediate transmucosal implants has been demonstrated when applying ePTFE membranes.⁽¹⁰⁾ A second surgical intervention was necessary to remove the non-resorbable membrane in that study. On the other hand bioresorbable membranes have not produced as promising results as non resorbable membranes. In a comparative study using bioresorbable and non-resorbable membranes, 98% defect resolution was found with the ePTFE membranes, whereas 89% was found for the bioresorbable polylactic acid/polyglycolic acid membranes.⁽¹¹⁾ In another study utilizing collagen membrane deep defects showed almost complete bone fill whereas shallow sites slightly lost bone. The probable reason for poor results shown by collagen membranes may be possibly due to short resorption time to allow complete bone fill.⁽¹²⁾ In the present case collagen membrane was used to achieve bone regeneration of 1.2 mm in a period of six months.

The final esthetic appearance of the patient was enhanced by carrying out Laser assisted perioplastic procedure of frenectomy to correct the abnormal frenal pull. Other treatment modalities include V-Y plasty, Z plasty, Miller technique etc.⁽¹³⁾ LASERS was chosen above all because it leads to improved epithelization and wound healing. The incision depth of laser ranges from 2 to 6 mm. Heat produced during use of laser causes coagulation, protein denaturation, drying, vaporization, and carbonization at the site of the energy absorption. This seal blood vessels and inhibit pain receptors at the incision location. Therefore, using

diode lasers was advantageous because of better control, potentially lower pain and inflammation, and improved wound healing.⁽¹⁴⁾

Therefore to conclude, Guided bone regeneration in this case resulted in successful augmentation of buccal cortical plate. The abnormal frenal pull was corrected using LASER assisted perioplastic surgery. The remote incision given at the time of implant placement resulted in conservation of the interdental papilla and its recreation after the prosthetic rehabilitation and thus resulted in better esthetic outcome.

References

1. Dahlin, C., Andersson, L. & Linde, A. (1991) Bone regeneration at fenestrated implants by an osteo-promotive membrane technique. A controlled clinical study. *Clinical Oral Implants Research* 2:159–165.
2. Dahlin, C., Lekholm, U., Becker, W., Becker, B., Higuchi, K., Callens, A. & van Steenberghe, D. (1995) Treatment of fenestration and dehiscence bone defects around oral implants using the guided tissue regeneration technique: a prospective multicenter study. *International Journal of Oral & Maxillofacial Implants* 10:312–318.
3. Hammerle, C.H.F. & Karring, T. (1998) Guided bone regeneration at oral implant sites. *Periodontology* 2000;17:151–175.
4. Artzi Z, Tal H, Chweidan H. Bone regeneration for reintegration in peri-implant destruction. *Compend Contin Educ Dent* 1998;19:17-20,22-3,26-8.
5. Lehmann B, Bragger U, Hammerle CH, Fourmouis I, Lang NP. Treatment of an early implant failure according to the principles of guided tissue regeneration (GTR). *Clin Oral Implants Res* 1992;3:42-8.
6. Zablotsky MH, Diedrich DL, Meffert RM. Detoxification of endotoxin- contaminated titanium and hydroxyapatite-coated surfaces utilizing various chemotherapeutic and mechanical modalities. *Implant Dent* 1992;1:154-8.
7. Esposito M, Grusovin MG, Felice P, Karatzopoulos G, Worthington HV, Coulthard P. The efficacy of horizontal and vertical bone augmentation procedures for dental implants - a Cochrane systematic review. *Eur J Oral Implantol* 2009;2:167-84.
8. Simion M, Jovanovic SA, Trisi P, Scarano A, Piattelli A. Vertical ridge augmentation around dental implants using a membrane technique and autogenous bone or allografts in humans. *Int J Periodontics Restorative Dent* 1998;18:8-23.
9. Fontana F, Santoro F, Maiorana C, Iezzi G, Piattelli A, Simion M. Clinical and histologic evaluation of allogeneic bone matrix versus autogenous bone chips associated with titanium-reinforced e-PTFE membrane for vertical ridge augmentation: a prospective pilot study. *Int J Oral Maxillofac Implants* 2008;23:1003-12.
10. Hammerle CHF, Bragger U, Schmid B, Lang NP. Successful bone formation at immediate transmucosal implants. *International Journal of Oral and Maxillofacial Implants*. 13,1998:522–530.
11. Simion, M., Misitano, U., Gionso, L. & Salvato, A. (1997) Treatment of dehiscences and fenestrations around dental implants using resorbable and non-resorbable membranes associated with bone autografts: a comparative clinical study. *International Journal of Oral and Maxillofacial Implants* 12:159–167.
12. Hammerle CHF, Lang NP. Single stage surgery combining transmucosal implant placement with guided

bone regeneration and bioresorbable materials. *Clin Oral Impl Res*. 12,2001;9–18.

13. Devishree, Gujjari SK, Shubhashini PV. Frenectomy: A review with the reports of surgical techniques. *J Clin Diagn Res*. 2012;6:587-1592.
14. Funde S, Baburaj MD, Pimpale SK. Comparison between Laser, Electrocautery and Scalpel in the Treatment of Drug-Induced Gingival Overgrowth: A Case Report. *IJSS Case Reports & Reviews* | March 2015 | Vol 1 | Issue 10.