

## Histomorphological study of salivary gland lesions: A study in tertiary care centre, Bangalore

Anushree CN<sup>1\*</sup>, Jayalakshmi VJ<sup>2</sup>, Manjunatha YA<sup>3</sup>

<sup>1</sup>Associate Professor, <sup>2</sup>PG Student, <sup>3</sup>Professor and HOD, Dept. of Pathology, Dr. B.R Ambedkar Medical College, Bangalore, Karnataka, India

### Article Info

Received: 29<sup>th</sup> July, 2018

Accepted: 5<sup>th</sup> December, 2019

Published Online: 9<sup>th</sup> August, 2019

**Keywords:** Salivary gland, Pleomorphic adenoma and Mucoepidermoid carcinoma.

### Abstract

**Introduction:** Salivary gland lesions are morphologically and clinically diverse group of lesions which is difficult task for histomorphological interpretation. Since salivary gland tumours are uncommon owing to limited experience with them. The salivary gland system comprises three pairs of major glands (parotid, submandibular and sublingual) and about 500-1000 lobules of minor glands dispersed in the submucosa of the oral cavity. Neoplastic and non-neoplastic lesions arises from major and minor salivary glands.

**Materials and Methods:** Present study was done for 3 years from June 2015 to June 2018. The study was done on 50 specimens from patients with salivary gland lesions which are referred to the department of pathology, DR. B R Ambedkar medical college, Bangalore, Karnataka. The gross examination was done after fixing specimen in 10% formalin and sections were stained with haematoxylin and eosin.

**Results:** Out of 50 cases, 35 cases are neoplastic, and 15 cases are non-neoplastic. Among 35 neoplastic lesions, 20 cases are benign, and 15 cases are malignant. Most common benign tumour of salivary gland is pleomorphic adenoma followed by Warthin's tumour. Most common malignant tumour of salivary gland is mucoepidermoid carcinoma followed by adenoid cystic carcinoma. Most common non-neoplastic lesion is chronic sialadenitis.

**Conclusion:** From the present study, it is evident that histomorphological examination is the mainstay for the diagnosis and categorization of neoplastic and non-neoplastic lesions of salivary gland.

### Introduction

The salivary glands present with a wide spectrum of lesions, comprising of non-neoplastic and neoplastic lesions. Neoplasms are not regularly observed in salivary gland, constitute under 1% of all tumors and epithelial tumors of 4% observed in the head and neck regions.<sup>1</sup> Non-neoplastic lesions include inflammatory disorder due to infection, autoimmune or granulomatous related, obstructive, idiopathic and developmental disorders. These non-neoplastic lesions clinically may mimic as tumors and pathological findings may have resemblance with other tumors of salivary gland.<sup>2,3</sup>

Salivary gland tumors may exhibit morphologic diversity between various tumor types and within tumors, parotid gland shows 80% tumors, submandibular gland is involved 10-15%. Benign tumors are more common in salivary gland, with pleomorphic adenoma being commoner.<sup>4</sup> Mucoepidermoid carcinoma is the most broadly perceived among malignant tumors.

### Materials and Methods

This study was conducted in department of pathology, Dr. B.R Ambedkar medical college, Bangalore, from June 2015 to June 2018 for 3 years.

An aggregate of 50 salivary gland specimens were analysed, the study incorporates both non-neoplastic and neoplastic lesions. Clinical details were gathered, and specimens were fixed in formalin, embedded in paraffin and sections are stained with routine haematoxylin and eosin. For diagnosis and confirmation microscopic examination is done. Mucicarmine and Alcian blue special stain done wherever necessary. Neoplastic lesions were classified according to the World Health Organization's histologic classification of tumors.

### Results and Observation

An aggregate of 50 salivary gland specimens were analysed. Out of 50 cases (Table 6), 35 cases are neoplastic, and 15 cases are non-neoplastic. Among 35 neoplastic lesions, 20 lesions were benign, and 15 lesions were malignant. Pleomorphic adenoma was first commonest benign tumor to be diagnosed in our study, second being Warthins tumor.

\*Corresponding Author: Anushree CN, Associate Professor, Dept. of Pathology, B.R Ambedkar Medical College, Bangalore, Karnataka, India

Email: [dranu77@gmail.com](mailto:dranu77@gmail.com)

<http://doi.org/10.18231/j.ijpo.2019.088>

Mucoepidermoid carcinoma was first commonest malignant tumor diagnosed in our study and second being adenoid cystic carcinoma. Commonest non-neoplastic lesion observed is chronic sialadenitis. Affected patients are between 15 to 70 years age group, transcendentally males were involved.

A maximum number of cases are seen in parotid gland constituting 33 cases (66%) trailed by the submandibular gland and minor salivary gland constituting 12 cases (24%) and 5 cases (10%) respectively (Table 1).

A maximum number of non-neoplastic lesions are seen in 15-30 years age group, benign lesions are in 30-50 age group and malignant lesions 50-70 age group. (Table 2). In our study males are commonly affected with a male to female proportion of 1.2:1 (Table 3).

Of the aggregate 50 salivary gland lesions, non-neoplastic lesions are 15 cases (30%) Neoplastic lesions are 35 cases (70%) (Table 4).

A predominantly seen are benign neoplasms of 20 cases (40%) and malignant cases are 15 (30%). Different types of lesions encountered are shown in Table 5.

**Table 1:** Location of lesion

	Parotid gland	Submandibular gland	Minor salivary gland	Total
Total number of cases 50	33	12	5	50
Percentage (%)	66	24	10	100

**Table 2:** Age wise distribution of salivary gland lesions

Lesions	10-19 Years	20-29 Years	30-39 Years	40-49 Years	50-59 Years	60-69 Years
Mucocele	1	2	0	0	0	0
Chronic sialadenitis	1	6	5	0	0	0
Pleomorphic adenoma	0	4	5	1	0	0
Warthin's tumour	0	0	1	2	3	0
Myoepithelioma	0	0	0	1	1	0
Basal cell adenoma	0	0	0	1	0	0
Lipoma	0	0	0	1	0	0
Mucoepidermoid carcinoma	0	0	0	2	2	4
Adenoid cystic carcinoma	0	0	0	1	2	2
Polymorphous low-grade adenocarcinoma	0	0	0	0	1	0
Squamous cell carcinoma	0	0	0	0	0	1
Total	2	12	11	9	9	7

**Table 3:** Sex predilection in salivary gland lesions

	No of cases	Percentage
Male	28	56%
Females	22	44%
Total	50	100%

**Table 4:** Incidence of neoplastic and non-neoplastic lesions

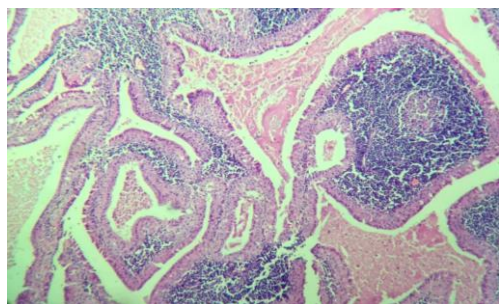
	Non-neoplastic	Neoplastic	Total
Total No of cases	15	35	50
Percentage (%)	30	70	100

**Table 5:** Spectrum of salivary gland lesions

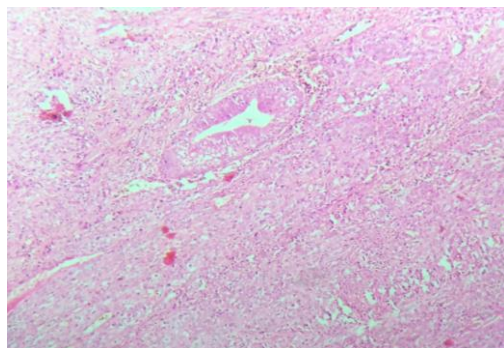
Lesions	Number of cases	Percentage
Mucocele	3	6%
Chronic sialadenitis	12	24%
Pleomorphic adenoma	10	20%
Warthin's tumour	6	12%
Myoepithelioma	2	4%
Basal cell adenoma	1	2%
Sialolipoma	1	2%
Mucoepidermoid carcinoma	8	16%
Adenoid cystic carcinoma	5	10%
Polymorphous low-grade adenocarcinoma	1	2%
Squamous cell carcinoma	1	2%
<b>Total</b>	<b>50</b>	<b>100%</b>

**Discussion**

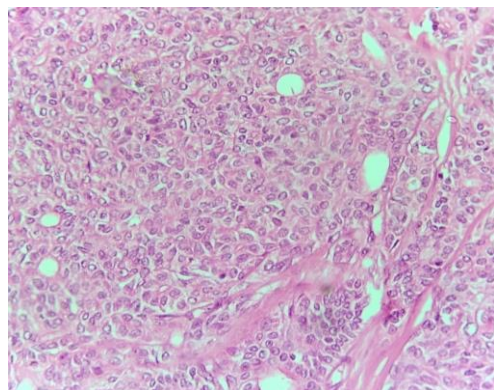
The salivary gland disorders represent a distinct group of diseases, tumors are relatively uncommon accounting for 3-10% of all head and neck neoplasm.<sup>5,6</sup> In the present study, we found a prevalence of neoplastic lesions (70%) over non-neoplastic lesions (30%) which were additionally featured by Ma'aita et al.<sup>7</sup> Among the 35 neoplastic lesions, benign tumors prevailed over the malignant tumors. This observation was equivalent to the studies including case series by Shrestha S, et al.<sup>8</sup>, Nepal A et al.<sup>9</sup> and Moghadam SA et al.<sup>10</sup> The Table 6 shows that majority of lesions were benign neoplasms and is similar to the other studies in the literature.



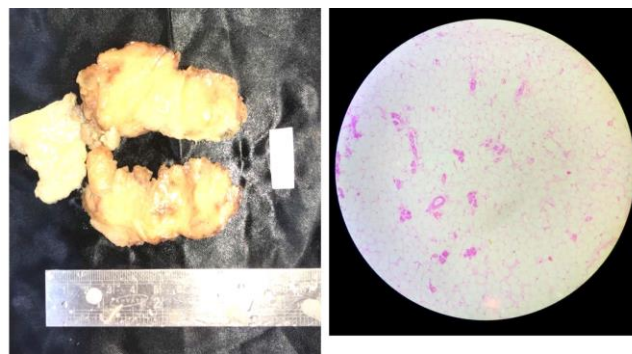
**Fig. 1:** Microscopic appearance of Warthin's tumor showing oncocytic lined epithelium and lymphoid stroma. H&E stain (10X)



**Fig. 2:** Microscopic appearance of Mucoepidermoid carcinoma showing squamoid cells and mucous cells. H&E stain (10X).



**Fig. 3:** Microscopic appearance of polymorphous low-grade adenocarcinoma showing malignant epithelial glands (40X)



**Fig. 4:** Microscopic appearance of Sialolipoma showing parotid acini and mature adipocytes (10X)

**Table 6:** Showing comparison of benign and malignant lesions

	Shrestha S et al, (2014) <sup>8</sup>	Nepal et al (2010) <sup>9</sup>	Moghadam SA et al (2010) <sup>10</sup>	Present study
Benign	62.5%	81%	84%	40%
Malignant	37.5%	19%	28%	30%

In this study of 50 lesions, among the neoplastic lesions, pleomorphic adenoma was the commonest benign tumor next commonest was Warthin's tumor. Mucoepidermoid carcinoma was commonest malignant tumor next commonest was adenoid cystic carcinoma.

In this study, males were commonly affected than females with a ratio of 1.2:1. This is in comparison with the studies reported by Ahmed et al,<sup>11</sup> and Erik G et al.<sup>12</sup>

Most commonly affected gland was Parotid (66%) in this study, next being submandibular gland (12%) and least commonly involved was minor salivary glands (10%). This is in correlation with the studies reported by Bashir. S. et al,<sup>13</sup> and T. Chatterjee et al.<sup>14</sup>

Literature additionally demonstrates that primary tumors of sublingual salivary gland are to a great degree uncommon.<sup>5</sup> In the studies revealed by Nagarkar et al<sup>15</sup> and Vargas et al,<sup>16</sup> benign tumor observed commonly in both major and minor salivary gland is Pleomorphic adenoma. In our study likewise, comparative findings observed pleomorphic adenoma being the common benign tumor at all the locations.

Malignant tumor most commonly encountered is Mucoepidermoid carcinoma accounting for 16%, Richardson et al<sup>17</sup> and Ali et al.<sup>18</sup> observed same findings in there study. There were 5 cases of adenoid cystic carcinoma. It is the second most common malignant salivary gland tumor in the present study. In Rewsuwan et al<sup>19</sup> study opposite to present study, reported adenoid cystic carcinoma as commonest malignant tumor.

**Conclusion**

In conclusion from the present study, it is evident that histomorphological findings are essential to differentiate neoplastic and non neoplastic lesions and to establish the final diagnosis, typing, grading and predicting prognosis of neoplasm.

**Conflict of Interest:** None.

**Source of Funding:** None.

## References

1. Luukka H. Salivary Gland Cancer in Finland Incidence, Histological Distribution, Outcome and Prognostic Factors. Turku, Finland: University of Turku; 2010.
2. Mohan H, Tahlan A, Mundi I, Punia RP, Dass A. Non-neoplastic salivary gland lesions: a 15-year study. *Eur Arch Otorhinolaryngol* 2011;268(8):1187-90.
3. Barnes L, Everson JW, Reuichart P, Sidrawsky D. WHO classification of tumours. Pathology and Genetics of Head and Neck Tumours. Vol. 9. Lyon: IARC Press; 2005. p. 209-81.
4. Spiro JD, Spiro RH. Salivary tumors. In: Shah JP, Decker SB, editors. Cancer of the Head and Neck. Hamilton: Decker BC Inc.; 2001. p. 240-50.
5. Eveson JW, Cawson RA. Salivary gland tumours. A review of 2410 cases with reference to histological types, site, age and sex distribution. *J Pathol* 1985;146:51-8.
6. Arotiba GT. Salivary gland neoplasms in Lagos, Nigeria. *West Afr J Med* 1996;15:11-7.
7. Ma'aitha JK, Al-Kaisi N, Al-Tamimi S, Wraikat A. Salivary gland tumors in Jordan: A retrospective study of 221 patients. *Croat Med J* 1999;40:539-42.
8. Shrestha S, Pandey G, Pun CB, Bhatta R, Shahi R. Histopathological pattern of salivary gland tumors. *J Pathol Nepal* 2014;4:520.
9. Nepal A, Chettri ST, Joshi RR, Bhattarai M, Ghimire A, Karki S; Primary Salivary Gland Tumors in Eastern Nepal Tertiary Care Hospital. *J Nepal Health Res Counc* 2010;8:31-4.
10. Saede Atarbashi Moghadam, FazeleAtarbashi Moghadam, Mehdi Dadfar. Epithelial Salivary Gland Tumors in Ahvaz, Southwest of Iran. *J Dent Res Dent Clin Dent Prospect* 2010;4:120-3.
11. Ahmad S, Lateef M, Ahmad R. Clinicopathological study of primary salivary gland tumors in Kashmir. *JK Practitioner* 2002;4(9):231-3.
12. Erik G. Cohen, Patel S G, Lin O, Boyle J O, Kraus D H. Fine-Needle Aspiration Biopsy of Salivary Gland Lesions in a Selected Patient Population. *Arch Otolaryngol Head Neck Surg* 2004;130:773-8.
13. Bashir S, Mustafa F, Malla H A, Khan A H, Rasool M, Sharma S. Histopathological Spectrum of Salivary Gland Tumors: A 10 Year Experience. *Sch J App Med Sci* 2013;1(6):1070-4.
14. Chatterjee MT, Panda PK. A Pathological study of benign and malignant tumors of salivary glands. *MJAFI* 2000;56:282-6.
15. Nagarkar Nitin M, Bansal Sandeep, Dass Arjun, Singhal Surinder k, Mohan harsh. Salivary Gland tumors: Our experience. *Indian J Otolaryngol Head and Neck Surg* 2004;56(1):31-4.
16. Pablo Agustin Vergas, Rene Gerhard, Vergilius J. F. Araujo Filiho and Ines Vieira de Castro; Salivary gland tumors in Brazillian population: A retrospective study of 124 cases. *Rev Hosp Clin Fac Med S Paulo* 2002;57(6):271-6.
17. Richardson GS, Dickason WL, Gaisford JC. Tumors of salivary glands; An analysis of 752 cases. *Plastic Reconstr Surg* 1975;55:131.
18. Naeem Sultan Ali, Ahmad Nawaz, Shaheryar Rajput, Mubasher Ikram. Parotidectomy: A Review of 112 Patients Treated at a Teaching Hospital in Pakistan. *Asian Pac J Cancer Prev* 2010;11.
19. Rewsuwan S, Settakorn J, Mahanupab P. Salivary gland tumors in Maharaj Nakorn Chiang Mai Hospital: A retrospective study of 198 cases. *Chiang Mai Med Bull* 2006;45:45-53.

**How to cite this article:** Anushree CN, Jayalakshmi VJ, Manjunatha YA. Histomorphological study of salivary gland lesions: A study in tertiary care centre, Bangalore. *Indian J Pathol Oncol* 2019;6(3):460-3.