

## Dual pathology a case report of yolk sac component in mature gastric teratoma

Hema AV<sup>1</sup>, Gautam B<sup>2\*</sup>, Seema B<sup>3</sup>, HR Chandrasekhar<sup>4</sup>, Rajashekar KS<sup>5</sup>

<sup>1,2</sup>Post Graduate, <sup>3,4</sup>Professor, <sup>5</sup>Professor and HOD, Dept. of Pathology, JJM Medical College, Davangere, Karnataka, India

### Article Info

**Received:** 9<sup>th</sup> February, 2019

**Accepted:** 6<sup>th</sup> March, 2019

**Published Online:** 9<sup>th</sup> August, 2019

**Keywords:** Teratoma, Alpha fetoprotein, Yolk sac tumour.

### Abstract

Gastric teratoma is a rare tumour accounting for less than 1% of all teratomas in pediatric age groups. We present a case of gastric teratoma in 33-month-old male infant who presented with abdominal pain for 2 months. Ultrasound of abdomen revealed a multi-cystic mass with mixed echogenicity arising from the lesser curvature of stomach. The mass was excised completely and sent for histopathological examination. Histopathology confirmed mixed germ cell tumour (gastric mature teratoma and yolk sac tumour). Serum AFP (alpha fetoprotein) and extensive sampling of the lesions can help in identification of other germ cell component.

### Introduction

Gastric teratoma accounts for less than 1% of teratomas in pediatric age groups. A majority of the lesions are seen in the neonatal period. Gastric teratomas are the most common teratomas of gastro-intestinal tract, with oropharynx and tongue being other common sites. Since report of the first gastric teratoma in 1922, about 112 cases have been documented in literature.<sup>1</sup>

### Case Report

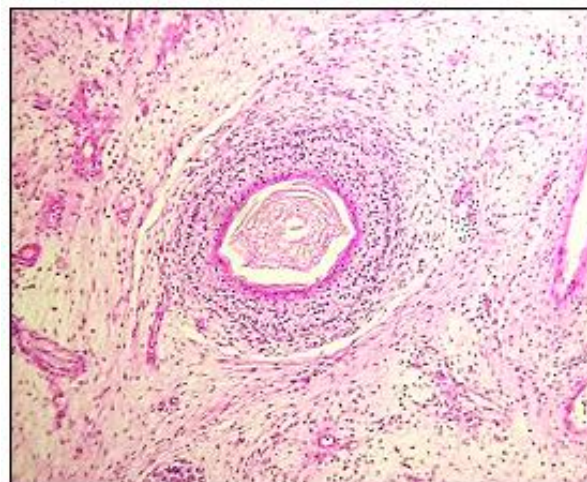
**Case History:** A 33-month-old male child presented with anaemia and pain abdomen for a duration of 2 months. Prior surgical history of laparotomy for similar complaints one and half year back. Previous histopathological report showed the lesion was diagnosed as immature gastric teratoma.

Per abdomen examination showed an intra-abdominal mass, predominantly in the left upper quadrant of abdomen. AFP (alpha fetoprotein) was significantly raised (559.8 IU/ml). Ultrasonography showed a multi-cystic lesion with mixed echogenicity attached to lesser curvature.

Operative findings showed a multi-cystic lesion displacing the stomach anteriorly and pancreas laterally. A complete excision of the tumour was performed. Gross examination of the lesion revealed an encapsulated lesion measuring 15x12x8, on cut section mass had a solid-cystic areas with a variegated appearance along with foci of cartilage, sero-mucinous secretions, area of necrosis and haemorrhage.

Light microscopy showed derivatives from all three germ cell layer. Endodermal components such as smooth muscles, intestinal wall, respiratory epithelium and pancreatic acini were seen. Mesodermal components such as cartilage and ectodermal component in the form of stratified

squamous epithelium with keratin was also seen. Focal areas of yolk sac tumour component composed of tumour cells in alveolar and trabecular pattern having vesicular nuclei and inconspicuous nucleoli. Pathognomic finding of Schiller Duval body was also observed. No angiolymphatic invasion was appreciable. A final diagnosis of mixed germ cell tumour (mature gastric teratoma with yolk sac tumour (YST)) was done.

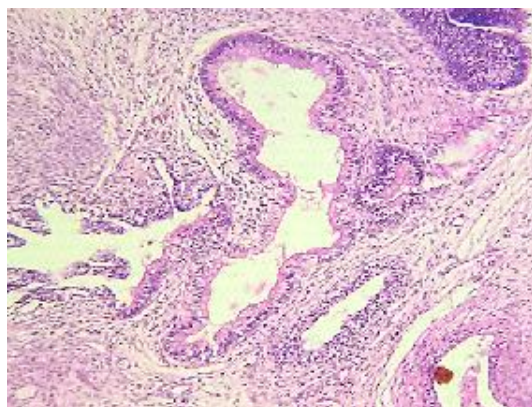
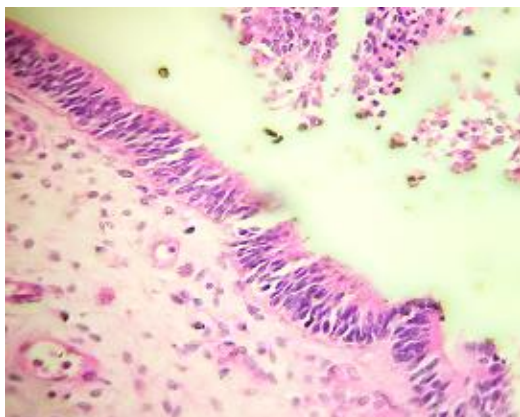


**Fig. 1:** Photomicrograph showing mature teratoma with ectodermal component- stratified keratinizing squamous epithelium, low power magnification (100x, H&E stain)

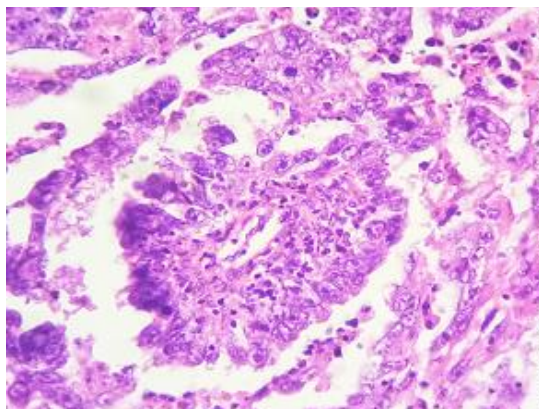
\*Corresponding Author: Gautam B, Professor, Dept. of Pathology, JJM Medical College, Davangere, Karnataka, India

Email: [gb781227@gmail.com](mailto:gb781227@gmail.com)

<http://doi.org/10.18231/j.ijpo.2019.095>



**Fig. 2 & 3:** Photomicrograph showing mature teratoma with endodermal component pseudostratified ciliated columnar epithelium and intestinal mucosa, low power magnification (100x, H&E stain)



**Fig. 4:** Photomicrograph showing Schiller duval body, higher power magnification (400x, H&E stain)

### Discussion

Teratomas are the most frequently encountered neoplastic germ cell lesion in paediatric age group. Paediatric teratomas are most frequently seen in the sacrococcygeal region (60%–65%), followed by mediastinum (11.7%), gonads (10%–20%) and retroperitoneum (5%).<sup>1</sup>

The site of gastric teratoma is variable but frequently seen arising from greater curvature followed by posterior wall of the stomach. The lesion grows centrifugally but in the

current case it was seen arising from the lesser curvature which is less common.<sup>1</sup>

The lesion usually presents clinically as a palpable abdominal mass in the epigastric region, abdominal distension and features of intestinal obstruction and melena.<sup>1,2</sup>

Similar to teratomas at other sites, gastric teratomas are neoplastic lesions derived from all germ layers. The lesions can be subtyped into immature, mature, and teratomas with malignant transformation.<sup>1</sup> Teratomas with malignant transformation is used only when the lesion contains at least one malignant germ cell element.<sup>2</sup>

Gastric teratomas form a distinct subset of teratomas with an unusual male predominance (> 95%) and is typically unrelated to congenital anomalies.<sup>2</sup>

The first gastric teratoma was reported by Eusterman and Sentry in 1922.<sup>1,3,4</sup> The current case is a mixed germ cell tumour composed of a mature gastric teratoma along with a yolk sac tumour.

Ukiyama *et al.* published a case report of a Yolk sac tumour (YST) seen following resection of a neonatal immature gastric teratoma<sup>5</sup> the literature on gastric teratomas with malignant composition is limited. In addition, literature on recurrence of gastric teratomas as a malignant lesion has not been reported.<sup>6,7</sup>

In the current case, the patient provided prior surgical history for management of an immature teratoma, 28 months back. Ukiyama *et al.* suggests that immature teratomas pose a challenge with regard to management as case the data on the lesion is limited and in cases with inadequate sampling, another germ cell lesion (microscopic foci of YST) could be overlooked leading to suboptimal patient therapy. The presence of YST is important and should be reported as the lesion is linked to the malignant potential of the lesion, as well as considered to be a predictor of recurrence in paediatric immature teratoma.<sup>5</sup>

Thorough sampling of these neonatal germ cell tumours is necessary to identify all components and provide optimal patient management.

Presence of glomerular differentiation and absence of pathognomic Schiller-Duval bodies pose a diagnostic difficulty in identification of yolk sac component in mixed germ cell tumours.<sup>1</sup> Elevated serum AFP concentration greater than 100 ng/dl is greatly indicative of a focus of YST. At times, a preoperative elevated serum AFP level may be the only indicator suggestive to the presence of a focus of YST. Serum AFP is an invaluable tool to diagnose and assess treatment response in follow-up of cases with gastric teratomas.<sup>1,8</sup>

Gastric teratomas can recur even 2 decades after resection of primary. Hence, an extensive and extended follow up period is recommended for these patients.<sup>1</sup>

### Conclusion

Gastric teratoma is a very rare tumour occurring in neonatal period and infancy, and is extremely rare beyond early childhood. It is almost always benign and has an overwhelming male preponderance. Thorough specimen

sampling is essential to detect malignant germ cell components. Non reporting other germ cell components in gastric teratomas can result in ineffective treatment and recurrence of lesion. Serum AFP is invaluable in initial detection as well as follow up of the patients with a mixed germ cell neoplasm. Surgical resection is the mainstay of therapy and clinicians are advised to perform long term follow-up as the lesion is known to recur, even after 2 decades.

**Conflict of Interest:** None.

**Source of Funding:** None.

## References

1. Parvin S, Sengupta M, Mishra P K, Chatterjee U, Banerjee S, Chaudhuri M K. Gastric teratoma: A series of 7 cases. *J Pediatr Surg* 2016;51:1072-7.
2. Mathur P, Gupta R, Prabhakar G, Agrawal L D, Rao R S, Goyal R B. Gastric teratoma in children: Our Experience. *Formosan J Surg* 2015;48:86-3.
3. Kharga B, Kumar V, Prabh P S, Sundeep P T, John S K. *J Clin Diagn Res* 2014;8:185-6.
4. Sharif M, Mirza B, Ijaz L, Iqbal S, Sheikh A. Immature Gastric Teratoma: A Rare Tumour. *APSP J Case Rep* 2010;1:17.
5. Mandelia A, Mutt N, Lal R, Prasad R. Yolk Sac Tumour of Stomach: Case Report and Review of Literature. *J Indian Assoc Pediatr Surg* 2018;23:232-3.
6. Bourke CJ, Mackay AJ, Payton D. Malignant gastric teratoma: case report. *Pediatr Sur Int* 1997;12:192-3.
7. Ravikumar VR, Ragupathy R, Das L, Palanimuthu M, Ravi N, Sekar PG, Vimala R. Gastric teratoma in an infant. *J Pediatr Surg* 1986;21:948.
8. Yaji P R, Joshi S, Kinhal V, Ravishankar T H, Jayaprakasha G, Melapure A, Reddy R, Desai M, Venkatesh B. Gastric teratoma in an infant: rare case report and discussion. *Indian J Surg* 2013;75:152-4.

**How to cite this article:** Hema AV, Gautam B, Seema B, Chandrasekhar HR, Rajashekar KS. Dual pathology a case report of yolk sac component in mature gastric teratoma. *Indian J Pathol Oncol* 2019;6(3):497-9.