

# Revascularization of a necrotic, infected, immature permanent molar with apical periodontitis: a case report

Pallavi Vashisth<sup>1</sup>, Vatsala V<sup>2</sup>, Sathyajith Naik<sup>3</sup>, Mousumi Goswami Singh<sup>4</sup>

## ABSTRACT

<sup>1</sup>Reader,

<sup>2</sup>Senior lecturer,

<sup>3</sup>Professor and Head,

Dept. of Pedodontics, Institute of Dental Sciences, Bareilly

<sup>4</sup>Professor, Dept of Pedodontics, ITS Greater NOIDA

### Address for Correspondence:

Dr. Pallavi Vashisth

Dept. of Pedodontics, Institute of Dental Sciences, Bareilly

Email: pallavivashisth@yahoo.in

Received: 17/02/2015

Accepted: 06/07/2015

## INTRODUCTION

Pulpal necrosis of an immature permanent tooth poses many potential complications. Rapidly progressing dentinal caries or traumatic injuries in the permanent teeth of young patients lead to pulp inflammation and / or necrosis and apical periodontitis, which subsequently interrupt the development of the incompletely formed roots. The presence of an open apex and thin fragile dentinal walls presents a problem that complicates the clinical management of pulp and periapical disease.<sup>1</sup>

The traditional techniques of chemo-mechanical instrumentation and disinfection of the root canal system used in mature teeth are limited by the immature tooth's anatomy.<sup>2</sup> The mechanical cleaning and shaping of a tooth with blunderbuss canal are difficult, if not impossible. The thin, fragile lateral dentinal walls can fracture during mechanical filing and the large volume of necrotic debris contained in a wide root canal is difficult to completely disinfect. Many blunderbuss canals with flaring walls cannot be obturated and sealed by orthograde methods and might require apical surgery and retrograde sealing of the canal.<sup>3</sup>

The traditional techniques of chemo-mechanical instrumentation and disinfection of the root canal system used in mature teeth are limited by the immature tooth's anatomy. The open apex is difficult or impossible to seal with conventional root filling methods because of the absence of an apical stop. Furthermore, the arrested development of the dentinal walls at the time of pulp necrosis leaves a weak tooth with thin dentinal walls that are susceptible to fracture. The purpose of the paper is to present the case of a patient wherein revascularization of the necrotic infected pulp space of an immature permanent mandibular molar was induced by stimulation of a blood clot from the periapical tissues into the canal space. The treatment approach can help rescue infected immature teeth by physiologically strengthening the root walls.

**Key words:** Pulp revascularization, Immature apex, Apexification.

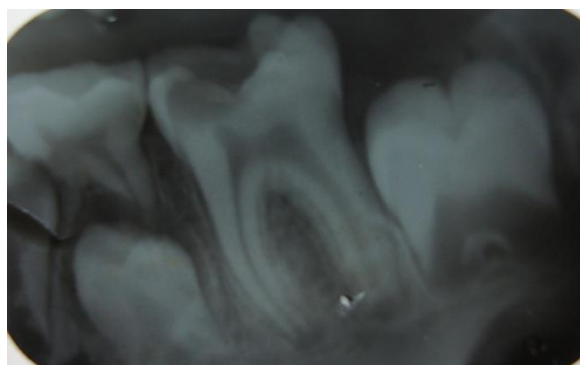
Many techniques have been suggested for induction of apical closure in pulpless teeth to produce more favorable conditions for conventional root canal filling. These techniques include surgery and retrograde sealing, calcium hydroxide - induced apical closure and placement of apical plug of mineral trioxide and gutta percha obturation but because of the thin dentinal walls, there is a high incidence of root fractures in teeth after apexification. Thus the concept of revascularization was introduced by Ostby in 1961. Nygaard- Ostby hypothesized that laceration of the periapical tissues until bleeding occurred might produce new vital vascularized tissue in the canal. He suggested that this treatment 'may result in further development of the apex'.<sup>4</sup> In 1966 Rule and Winter documented root development and apical barrier formation in cases of pulpal necrosis in children.<sup>5</sup> Since then there has been an ongoing research in this field. This case report add another example to dental literature supporting this treatment modality as a successful alternative to conventional procedure undertaken to treat necrotic, infected and immature permanent teeth.

## CASE REPORT

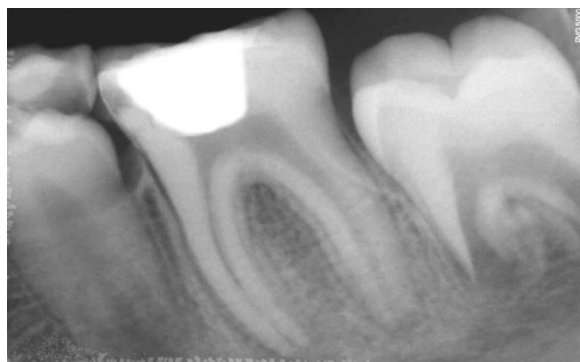A 8 year old female patient reported to the department with complaint of pain in mandibular left posterior tooth. Clinical evaluation revealed carious 36. Radiograph interpretation showed carious lesion approaching the pulp with open apices.(Fig 1) The tooth did not respond to cold testing with CO<sub>2</sub> ice, heat test, the tooth was tender on vertical percussion. The tooth was diagnosed with necrotic pulp. Access was obtained to the pulp space, where a necrotic pulp was confirmed clinically. The canal was instrumented

Access this article online	
Quick Response Code:	Website: <a href="http://www.its-jds.in">www.its-jds.in</a>
	DOI: 10.5958/2393-9834.2015.00011.X

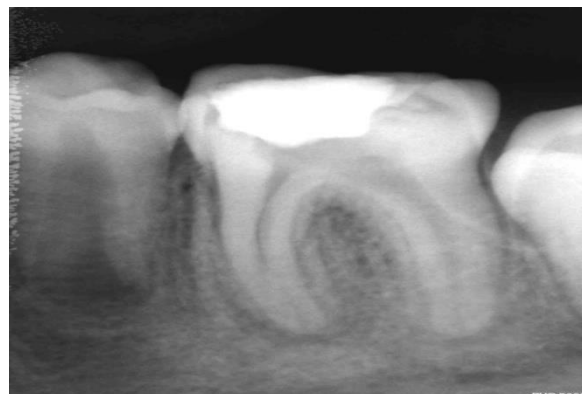
and irrigated copiously with 1.25% sodium hypochlorite and dried with sterile paper points. A creamy paste of equal proportions of metronidazole, ciprofloxacin and cefclor mixed with sterile water was applied to canal space. The access cavity was closed with cotton pellets and intermediate restorative material. The patient was asymptomatic when he returned for follow up treatment. The antibiotic paste was intact in the canal space and was irrigated away using 1.25% NaOCl and sterile water. No instrumentation of the canal space was performed. The apical tissues beyond the confines of the root canal were stimulated with sterile endodontic file to induce bleeding into the canal space. The blood clot was allowed to reach a level that approximated the cemento enamel junction. A cotton pellet moist with sterile water was applied over the blood clot. After this procedure permanent restoration with Glass Ionomer Cement was placed. At the 3- and 6 month follow- up evaluation, the patient was asymptomatic. (Fig 2) One year from the time of blood clot induction the tooth remained asymptomatic, with normal limits for percussion, palpation, pocket probing depths, and mobility. Radiographs revealed normal periapical structures with continued root development, and thickening of lateral aspects of dentinal walls of the root canals, reinforcing and strengthening the root. (Fig 3)



**Fig. 1: Preoperative radiograph showing carious 36, with open apices.**



**Fig. 2: 6 month follow- up showing continued root development.**



**Fig. 3: Radiograph at 12 months showing continued root development with apical constriction.**

## DISCUSSION

This report demonstrates the potential of non-vital infected teeth to undergo the procedure of revascularization and the same should be undertaken to avoid the undesired results of the conventional treatment options available. The open apex is difficult or impossible to seal with conventional root filling methods because of the absence of an apical stop. Furthermore, the arrested development of the dentinal walls at the time of pulp necrosis leaves a weak tooth with thin dentinal walls that are susceptible to fracture.<sup>(2)</sup> Bunchs and Trope in 2004 demonstrated the advantages of this treatment modality, which resulted in a radiographically apparent normal maturation of the entire root versus an outcome of only a calcific barrier formation at the apex after conventional calcium hydroxide- induced apexification.<sup>6</sup>

The rationale of revascularization is that if a sterile tissue matrix is provided in which new cells can grow, pulp vitality can be reestablished.<sup>3</sup> It is known that the infection control of microbial contamination from the root canal system is a precondition for successful root canal treatment and that the primary goal should be reduce the microbial load to a low level where tissue healing can occur.<sup>7</sup> Various combinations of topical antibiotics have the ability to disinfect carious dentin and necrotic, infected root canals. One combination that is effective against the bacteria commonly found in infected root canals is the use of ciprofloxacin, metronidazole and cefaclor.<sup>8</sup> But contradictory findings had been reported by Bezerra da Silva LA et al who evaluated in vivo the revascularization and the apical and periapical repair after endodontic treatment using 2 techniques for root canal disinfection (apical negative pressure versus apical positive pressure irrigation plus triantibiotic intracanal dressing) suggesting that the use of intra canal antibiotics may not be necessary.<sup>7</sup>

Different mechanism could be attributed to continued development of root: remnants of vital pulp cells at

the apical end of the root canal, presence of multipotent dental pulp stem cells,<sup>9</sup> stem cells from periodontal ligament which can proliferate within the root canal,<sup>10,11</sup> stem cells from apical papilla,<sup>12,13</sup> and presence of blood clot which being a rich source of growth factors could play an important role in regeneration.<sup>14</sup> The elongation of the root occurs by apposition of newly generated cementum – like tissue termed “intracanal cementum”. The generation of this tissue may occur despite the presence of inflammatory infiltration at the apex or in the canal.<sup>15</sup> There are several advantages of revascularization as observed from this as well as from the past studies. It requires a shorter treatment time, after control of infection, it can be completed in a single visit. It is also very cost- effective, because, because the number of visits is reduced and no additional material is required. Obturation of the canal is not required unlike in calcium hydroxide induced apexification, with its inherent danger of splitting the root during lateral condensation. However the biggest advantage is that of achieving continued root development and strengthening of the root as a result of reinforcement of lateral dentinal walls with deposition of new dentin/ hard tissue.<sup>3</sup>

The procedure is simple and may in near future replace the traditional treatment options including hard tissue barrier via calcium hydroxide or an artificial hard tissue barrier of MTA. We need to be constantly in touch with current concepts of advancements, take maximum advantage of the same, improve the standard of our specialty and serve the community in a better way.

## REFERENCES

1. Thibodeau B, Teixeira F, Yamauchi M, Caplan DJ, Trope M. Pulp revascularization of immature dog teeth with apical periodontitis. *J Endod.* 2007;33:680-89.
2. Thibodeau B. Case report: Pulp revascularization of a necrotic, infected, immature, permanent tooth. *Ped Dent.* 2009;31:145-48.
3. Shah N, Logani A, Bhaskar U, Aggarwal V. Efficacy of revascularization to induce apexification/apexogenesis in infected, nonvital, immature teeth: A pilot clinical study. *J Endod.* 2008;34:919-25.
4. Ostby BN. The role of the blood clot in endodontic therapy: an experimental biologic study. *Acta Odontol Scan.* 1961;120:324- 53.
5. Rule DC, Winter GB. Root growth and apical repair subsequent to pulpal necrosis in children. *Br Dent J.* 1966;120:586-90.
6. Banchs F, Trope M. Revascularization of an immature permanent teeth with apical periodontitis: new treatment protocol? *J Endod.* 2004;30:196-200.
7. Da Silva LAB, Nelson- Filho P, da Silva RAB, Flores DSH. Revascularization and periapical repair after endodontic treatment using apical negative pressure irrigation versus conventional irrigation plus triantibiotic intracanal dressing in dogs' teeth with apical periodontitis. *Oral Surg Oral Med Oral Pathol Oral Radiol Endod.* 2010;109: 779-87.
8. Sato T, Hoshino E, Uematsu H, Noda T. In vitro antimicrobial susceptibility to combinations of drugs on bacteria from carious and endodontic lesions of human deciduous teeth. *Oral Microbiol Immunol.* 1993;8:172-76.
9. Gronthos S, Brahim J, Li W et al. Stem cell properties of human dental pulp stem cells. *J Dent Res.* 2002; 81:531- 35.
10. Lieberman J, Trowbridge H. apical closure of non vital permanent incisor teeth where no treatment was performed: case report. *J Endod.* 1983; 9: 257- 60.
11. Nevin A, Wrobel W, Valachovic R, Finkelstein F. hard tissue induction into pulpless open- apex teeth using collagen- calcium phosphate gel. *J Endod.* 1977; 3:431-33.
12. Krebsbach P, Kuznetsov SA, Satomura K, Emmons RV, Rowe DW, Robey PG. Bone formation in vivo: comparison of osteogenesis by transplanted mouse and human marrow stromal fibroblasts. *Transplantation.* 1997; 63:1059-69.
13. Gronthos S, Mankani M, Brahim J, Robey PG, Shi S. Postnatal human dental pulp stem cells (DPSCs) in vitro and in vivo. *Proc Natl Acad Sci USA.* 2000; 97: 13625-30.
14. Wang Q, Lin XJ, Lin ZY, Liu GX, Shan XL. Expression of vascular endothelial growth factor in dental pulp of immature and mature permanent teeth in human. *Shanghai Kou Qiang Yi Zue.* 2007;16:285- 89.
15. Wang X, Thibodeau B, Trope M, Lin LM, Huang GTJ. Histologic characterization of regenerated tissues in canal space after revitalization/revascularization procedure of immature dog teeth with apical periodontitis. *J Endod.* 2010;36: 56-63.

**How to cite this article:** Vashisth P, Vatsala V, Naik S, Singh MG. Revascularization of a necrotic, infected, immature permanent molar with apical periodontitis: a case report. *J Dent Specialities.* 2015;3(2):180-182.

**Source of Support:** NIL

**Conflict of Interest:** All authors report no conflict of interest related to this study.