

## Atrophied maxilla restored with a pterygo-maxillary implant – a case report

Rahul Sharma<sup>1,\*</sup>, Jay Vikram<sup>2</sup>, Dhruv Anand<sup>3</sup>, Anurag Hasti<sup>4</sup>, Pradeep Sharma<sup>5</sup>

<sup>1,3</sup>Senior Lecturer, <sup>2</sup>Professor, <sup>4</sup>Reader, Dept. of Prosthodontics and Crown & Bridge, School of Dental Sciences, Sharda University, Greater Noida, Uttar Pradesh, India, <sup>5</sup>Senior Lecturer, Dept. of Oral & Maxillofacial Surgery, ITS Centre for Dental Studies & Research, Muradnagar, Ghaziabad, Uttar Pradesh, India

**\*Corresponding Author:**

Email: doczone.sharma@gmail.com

### Abstract

It is well documented that restoration of posterior atrophied maxilla with implants is a complex entity in itself. Since, implant placement in this area is often accompanied by sinus lift which itself is a morbid procedure with questionable success rate, a new approach of placement of implants in Pterygo maxillary area was explored.

The purpose of this article is to present a case report in which Pterygo-maxillary implant has been successfully placed to restore atrophied posterior maxilla without the sinus lift using 3D imaging technique - Cone Beam Computerised Tomography (CBCT). Thus, making it an easy procedure for placement of implants in the areas previously considered to be unapproachable.

**Keywords:** Pterygo Maxillary Implants, Atrophied Maxilla, Pterygoid Implants, Sinus Lift, Bone Augmentation

### Access this article online

**Website:**

[www.innovativepublication.com](http://www.innovativepublication.com)

**DOI:**

10.18231/2393-9834.2016.0019

### Introduction

The posterior region of the maxilla has many limitations for the placement of dental implants,<sup>1,2,3</sup> such as poor bone volume (usually a Class III or IV according to Lekholm and Zarb), the presence of the maxillary sinus and the difficulty in hygiene they entail.<sup>4,5</sup> In addition to these anatomic peculiarities, there is high occlusal loading in the molar regions in comparison with the other areas which leads to lower success rate than elsewhere in the maxilla or the mandible.<sup>6</sup> To resolve these problems, a variety of modalities have been reported in the literature like bone grafts, sinus lifts and altered implant locations like in zygoma and pterygoid region.<sup>1,2,7</sup> The use of pterygoid implants were described by Tulasne<sup>8</sup> and subsequently used by many other researchers. They are generally anchored in the pterygoid bone, however, in some studies they are placed in a more anterior position i.e. in the pterygo maxillary area, parallel to the posterior wall of the sinus. These implants have merits over other techniques as they allow anchorage in the posterior atrophied maxilla without sinus augmentations or bone grafts, achieving good stability and long-term success. In addition, cantilever extensions can be eliminated and axial loading is improved.<sup>9</sup> The literature describes two anatomic locations where implants are placed: the Pterygoid process (Fig. 1) and the Pterygo-maxillary region (Fig. 2).<sup>8</sup> This article describes the placement of implant in the left pterygo maxillary region.



**Fig. 1: An implant in the pterygoid process**



**Fig. 2: An implant in the pterygo-maxillary region**

### Case Report

A 53 year old female patient reported to Department of Prosthodontics with a chief complaint of difficulty in eating food. Intra-oral examination revealed 16 cantilevered with 15. Porcelain fused to metal (PFM) crowns in relation to 21, 22, 23, 24, 25 and 26 were present. 27 was grossly mutilated.

Lower arch was also restored completely with PFM crowns extending from 38- 47. Patient was advised to go for CBCT for evaluation of bone quantity and

quality for placement of implants in the region of 16, 17 and 27 (Fig. 3).

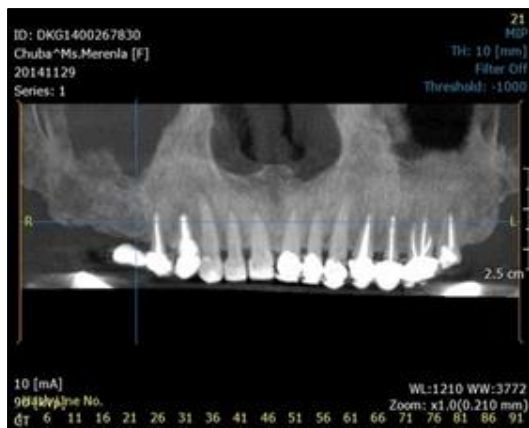

Fig. 3: Pre- operative radiograph

It was observed that root canal treatment of 14, 15, 24, 25, 26 and 27 was done. Periapical radiolucency was present in relation to 27.

Focal defect is noted in the crestal third of 17 region suggestive of partially remineralized socket. Coarse trabeculations were noted in 15 and 27 regions and normal to coarse trabeculations were noted in 16 and 17 region.

Table 1: Dimensions of bone available in the desired implant sites (Fig. 4, 5, 6)

S. No	Implant site	Width of Bone (mm)	Length of Bone(mm)
1	17	5.95	12
2	16	5.94	10.99
3	27	9.85	8.29

However, in the 27 region, the available bone width was corresponding to the width of grossly decayed 27. The height of the available bone was reduced further because of the radiolucency associated with 27.

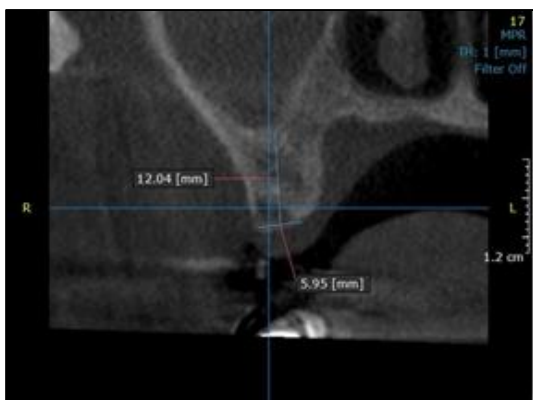


Fig. 4: CBCT section of 17

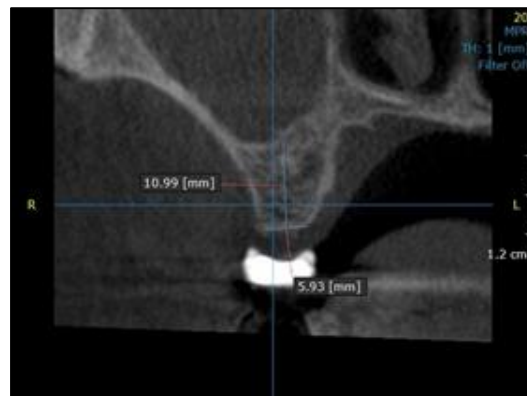


Fig. 5: CBCT section of 16

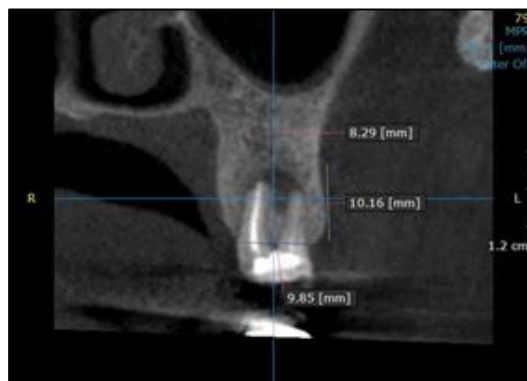


Fig. 6: CBCT section of 27

**Treatment plan**

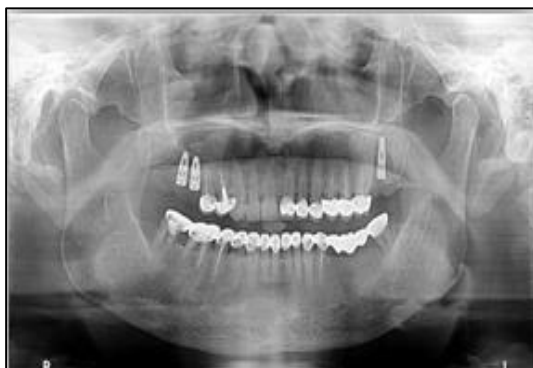Taking into account the findings of CBCT, following treatment plan was decided

1. Removal of the cantilever crown in relation to 16.
2. Placement of two implants in 16 and 17 regions (tapered Nobel Biocare - 4.3 X 10mm for both regions)
3. Extraction of 27 and immediate placement of implant through the extraction socket in the pterygo maxillary area (tapered Nobel Biocare - 4.3 X 16mm), since no sinus lift procedure was planned.
4. In the subsequent second stage surgery, healing abutments to be placed on the implants till the gingival collar is formed.
5. Implant level impressions for fabrication of PFM crowns.
6. Implant protected occlusion to be established by removing all cuspal contacts in eccentric movements and 15 µm disocclusion in centric occlusion.

**Procedure**

The cantilever on 15 was removed, mucoperiosteal flap was raised and osteotomy site was prepared for placement of implant according to the implant sizes as guided by the Cone Beam Computed Tomography (CBCT). Implants were placed in 16 and 17 region. The flap was approximated and sutured back for the second

stage surgery. 27 was atraumatically extracted and socket was debrided. It was noted that the socket was in close approximation to the distal root of 26. Since, the posterior sinus wall was tapering towards the roots of 27; osteotomy site for 27 region was prepared to get primary anchorage from the pterygo-maxillary area as guided by CBCT. Implant was placed in the pterygo-maxillary area distal to the maxillary sinus and the flap was approximated and sutured for second stage surgery. During subsequent follow-ups, healing was found to be satisfactory and patient was placed for second stage implant surgery for rehabilitation of missing tooth. (Fig. 7)



**Fig. 7: Post-operative OPG**

### Discussion

Pterygoid implants are inserted using a protocol that requires surgical expertise and detailed knowledge of the anatomy of that area. The implant is placed in the pterygoid plate of the Sphenoid bone, with an angulation between 35° and 55°, which depends on the floor of the maxillary sinus and the height of the bone available at the tuberosity region.<sup>9,10</sup> The distance from the internal maxillary artery to the lower end of the pterygomaxillary suture is 25 mm, as, the artery passes 1 cm above the pterygopalatine suture before entering the pterygopalatine fossa.<sup>11</sup> This is a safe working area for the operator because of the absence of vital structures in the insertion area. The placement of implants in the pterygo-maxillary region is within the maxillary tuberosity or parallel to the posterior wall of the sinus. The surgical procedure is comparable to that of implants anchored in the pterygoid process.<sup>12</sup> The angulation should be 10° to 20° to simulate the angulation of second molar/third molar. Bahat et al considered it necessary to have the patient's mouth open to a minimum of about 35 mm to achieve desirable implant angulation.<sup>7</sup> Both these implant location sites to restore the posterior maxilla have a distinct advantage over the conventional sinus lift procedure. Although, the procedures performed to increase the quantity of bone such as sinus lift gives good results but these procedures are always associated with complications like rejection of graft/implant and increase in overall morbidity of the patient.<sup>13,14</sup> In the

case of implants with sinus lift, longer period of healing is required before loading. Therefore, temporization of implants with bone augmentation is often contraindicated. This causes further discomfort to these patients. The pterygoid implants offer immediate loading solutions since the bone present in that region is predominantly cortical (Type I- Type II).<sup>8</sup> Therefore, it is observed that over the last few decades, given the excellent results achieved with pterygo-maxillary implants, this procedure has gradually established itself as not only a reliable treatment option but also one that offers good long-term results.<sup>15</sup> It is also considered as a rehabilitation treatment option in case of atrophic maxilla in the context of post-trauma, post-cancer and serious malformations.

### Conclusion

The newer radiographic tools like CBCT have enabled us to place implants in previously inaccessible areas like pterygomaxillary region. We are able to successfully restore the posterior atrophic maxilla without the augmentation of the deficient bone with sinus lift procedures. This procedure, like any other procedure has certain disadvantages like the site of implant placement is anatomically complicated and poorly understood. Further, inadequate mouth opening restricts both the placement as well as prosthetic restoration of implants in this area. Though, the results are promising, case selection is paramount and a thorough understanding of the risks involved with the procedure should be kept in mind.

### References

1. Penarrocha M, Carrillo C, Boronat A, Penarrocha M. Retrospective study of 68 implants placed in the pterygomaxillary region using drills and osteotomes. *Int J Oral Maxillofac Implants.* 2009;24:720–6.
2. Valeron JF, Valeron PF. Long-term results in placement of screw-type implants in the pterygomaxillary-pyramidal region. *Int J Oral Maxillofac Implants.* 2007;22:195–200.
3. Balshi TJ, Lee HY, Hernandez RE. The use of pterygomaxillary implants in the partially edentulous patient: a preliminary report. *Int J Oral Maxillofac Implants.* 1995;10:89–98.
4. Penarrocha-Diago M, Uribe-Origone R, Guarinos-Carbo J. Implant-supported rehabilitation of the severely atrophic maxilla: a clinical report. *J Prosthodont.* 2004;13:187–91.
5. Ridell A, Grondahl K, Sennerby L. Placement of Branemark implants in the maxillary tuber region: anatomical considerations, surgical technique and long-term results. *Clin Oral Implants Res.* 2009;20:94–8.
6. Balshi TJ, Wolfinger G, Balshi S. Analysis of 356 pterygomaxillary implants in edentulous arches for fixed prosthesis anchorage. *Int J Oral Maxillofac Implants.* 1999;14:398–406.
7. Bahat O. Osseointegrated implants in the maxillary tuberosity: report on 45 consecutive patients. *Int J Oral Maxillofac Implants.* 1992;7:459–67.
8. Eugenia C, David P, Maria P. Rehabilitation of the Atrophic Posterior Maxilla with Pterygoid Implants: A Review. *J Oral Implantology* 2012;38(1):461-66.

9. Balshi TJ, Wolfinger GJ. Management of the posterior maxilla in the compromised patient: historical, current, and future perspectives. *Periodontology*. 2000;33:67–81.
10. Graves SL. The pterygoid plate implant: a solution for restoring the posterior maxilla. *Int J Periodont Restor Dent*. 1994;14:512–23.
11. Nevins M, Mellonig JT. Implant therapy clinical approaches and evidence of success. Chicago, Quintessence 1998;2:198-201.
12. Wood RM, Moore DL. Grafting for the maxillary sinus with intraoral harvested autogenous bone prior to implant placement. *Int J Oral Maxillofac Implants*. 1988;3:209–14.
13. Parel SM, Branemark PI, Ohnelt LO, Svensson B. Remote implant anchorage for the rehabilitation of maxillary defects. *J Prosthet Dent* 2001;86:377–81.
14. Worthington P, Branemark PI. *Advanced Osseointegration Surgery. Applications in the Maxillofacial Region*. Chicago, Quintessence; 1992;3:182–8.
15. Nocini PF, Albanese M, Fior A, De Santis D. Implant placement in the maxillary tuberosity: the Summer's technique performed with modified osteotomes. *Clin Oral Implants Res* 2000;11:273–8.