

Conventional tooth supported overdenture with copings –Can it ever be overlooked?

Harchintan Kaur^{1*}, Vishwas Bhatia², Punit R.S. Khurana³, Abhijeet Buragohain⁴

¹Post Graduate Student, ²Professor, ³Professor and HOD, ⁴Post Graduate Student, Dept. of Prosthodontics, ITS Dental College, Hospital & Research Centre, Greater Noida, Uttar Pradesh, India

***Corresponding Author: Harchintan Kaur**

Email:dr.harchintankaur21@gmail.com

Abstract

Over denture is a one of the recommended treatment modality for aged patients with few remaining teeth with severely resorbed ridges. Root stumps under the denture base preserve further resorption of alveolar ridge which provides sensory feedback and improves the stability of the dentures. Moreover, the use of copings (short/long) and attachments on the remaining teeth after endodontic therapy enhances the retention of the denture. Success for the treatment depends on strategic selection of teeth. The present case report demonstrates the successful preservation of few remaining teeth to support tooth-retained overdenture. This treatment modality was selected considering the favorable inter ridge distance and economical status of the patient rather than complete extractions followed by complete denture or implant supported overdenture.

Keywords: Attachments, Overdenture, Removable partial denture, Severely resorbed ridges, Tooth-supported overdenture.

Introduction

DeVan stated: “Perpetual preservation of what remains is more important than the meticulous replacement of what is missing”.

Preventive prosthodontics emphasizes on the significance of procedure that can slow down or completely eliminate upcoming prosthodontic problems. One of the preventive treatment modality is overdenture. A completely edentulous patient undergoes phases of events i.e loss of individual tooth proprioception followed by progressive loss of bone resulting in transferring of load directly over the oral mucosa but most upsetting event is the loss of self-confidence in the patient. An over denture slows down the resorption, improves foundation area for denture followed by increase in masticatory efficiency.¹

Overdenture is defined as removable dental prosthesis which covers and rests on one or more remaining natural teeth, the roots of natural teeth, and/or dental implants; a dental prosthesis which covers and is partially supported by natural teeth, natural tooth roots, and/or dental implants.”²

Principle of over denture concept is rehabilitation after removing few remaining natural teeth with complete denture had not been the most acceptable treatment modality. Preventive prosthodontics emphasizes mainly on the significance of any procedure which slows down or completely eliminates any further prosthodontic problems. Therefore, over denture is one of the logical method for a dentist which can be used in preventive prosthodontics.³

It is indicated in patients who have lost remaining natural teeth. especially in younger age, generalized attrition, Cleft palate, congenital anomalies like microdontia, partial anodontia, Amelogenesis imperfecta, Dentinogenesis imperfecta and Maxillofacial trauma.⁴ Overdentures are contraindicated in patients who are mentally and physically unstable with compromised dexterity, un-cooperative and financially weak patients.⁴ General considerations during diagnosis and treatment planning are favorable crown root ratio,

adequate inter-occlusal clearance for placement of artificial teeth and for securing radicular attachments of overdentures.^{1,4}

Case Report

A 60-year-old male patient visited Department of Prosthodontics, and Oral Implantology of I.T.S Dental College, Greater Noida, with problem in chewing due to few missing teeth. The case history did not reveal any relevant finding that could affect the prosthodontic treatment. Intraoral examination revealed sound periodontal support and favorable crown root ratio. The teeth present in the maxillary ridge were 11, 12, 21, and 25. On radiographic examination, they were found to have good bone support and long roots. No significant mobility and periapical pathology was noticed. Different treatment options i.e conventional complete denture, implant supported overdenture and tooth supported overdenture were given to the patient.

As per the economic status as well the inter-ridge distance of the patient, it was planned to fabricate a maxillary tooth-retained overdenture and a mandibular conventional denture. An OPG was done, Intraoral and Extraoral photographs were taken and diagnostic casts were made (Fig. 1,2). After taking consent from patient, it was planned to retain maxillary teeth, proceed with intentional RCT to obtain favorable crown-root ratio followed by metallic copings (Fig. 3).

Primary impression for the mandibular arch with impression compound was made (Y-Dent, MDM corp.). For maxillary teeth, intentional RCT was done followed by tooth preparation, retraction and impression with addition silicone (Aquasil, Dentsply) (Fig. 4). Maxillary cast was obtained and sent to the laboratory for the metal coping fabrication on abutments i.e 11, 12, 21 and 25.

After cementing the copings, patient was recalled after 3 days and impression with hydrocolloid impression material (Tropicalgin, Zhermack; Germany) was made.

Customized special tray was fabricated with self-cured acrylic resin for the maxillary and mandibular arch (DPI, Zahnsply). Border molding for both the arches was done with low fusing compound. (DPI Pinnacle). Final impressions for the mandibular and maxillary arch with zinc oxide eugenol impression was made (DPI Impression Paste) (Fig. 5). Master casts were obtained in Type IV gypsum (Vel-mix, Kerr). Abutments were blocked out with wax. Record base was fabricated. Block out of abutments prevent the fracture of abutments at the time of removal of the temporary record base during dewaxing. Occlusal rims for maxilla-mandibular relations were fabricated and recorded.

Rims were transferred onto the semi-adjustable articulator with the help of face-bow (Fig. 6) and teeth arrangement was done. Phonetics, vertical and centric relation and finally esthetics were evaluated in the patient's mouth (Fig. 7). Vertical dimension was verified with centric and eccentric contacts. Patients approval was taken, and the fabrication of the final prosthesis with heat-cured acrylic resin was done (Travelon Hi, Dentsply). Post-finishing, polishing and occlusal equilibration, final tooth supported maxillary and mandibular complete denture prosthesis insertion was done (Fig. 8).

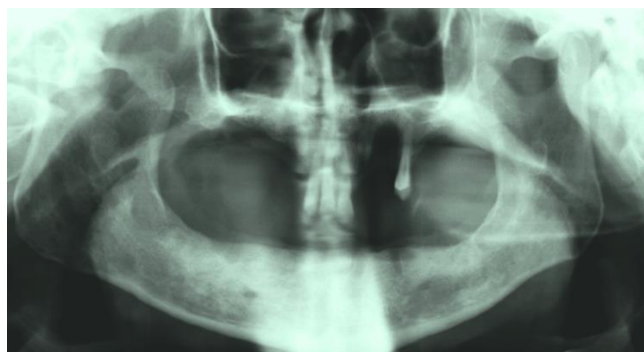


Fig. 1: Pre- operative OPG

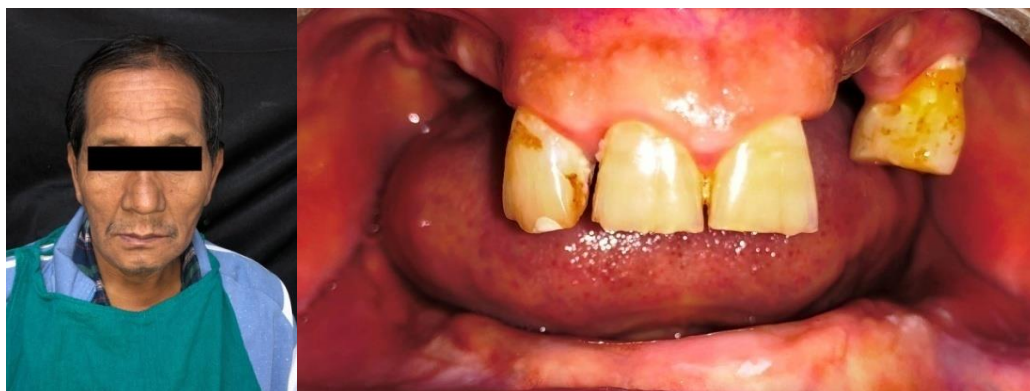

Fig. 2: Extraoral and intraoral photographs

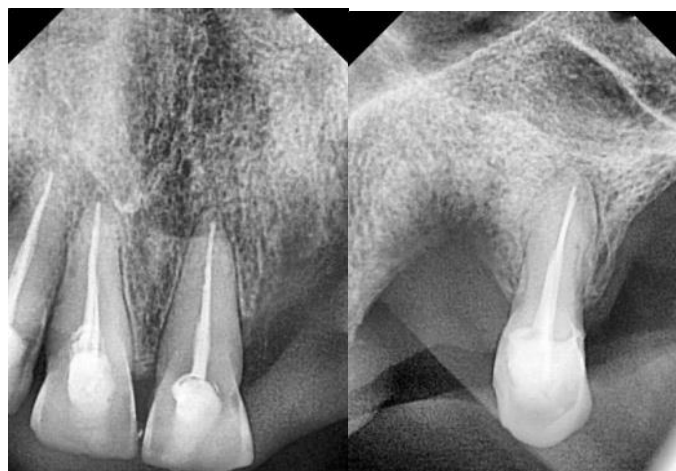

Fig. 3: Post-endo RVG

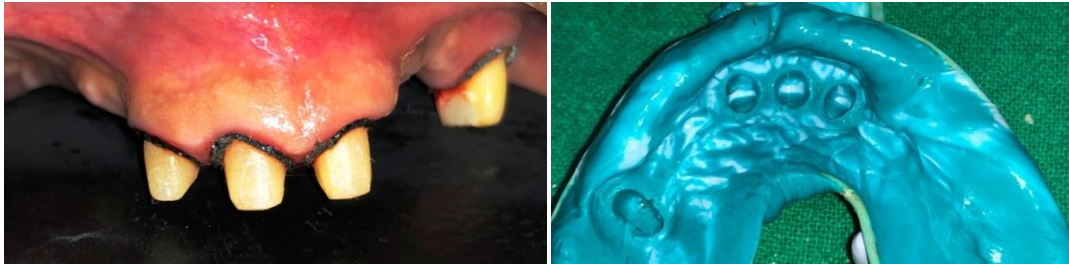

Fig. 4: Prepared tooth with gingival retraction followed by putty and light body impression

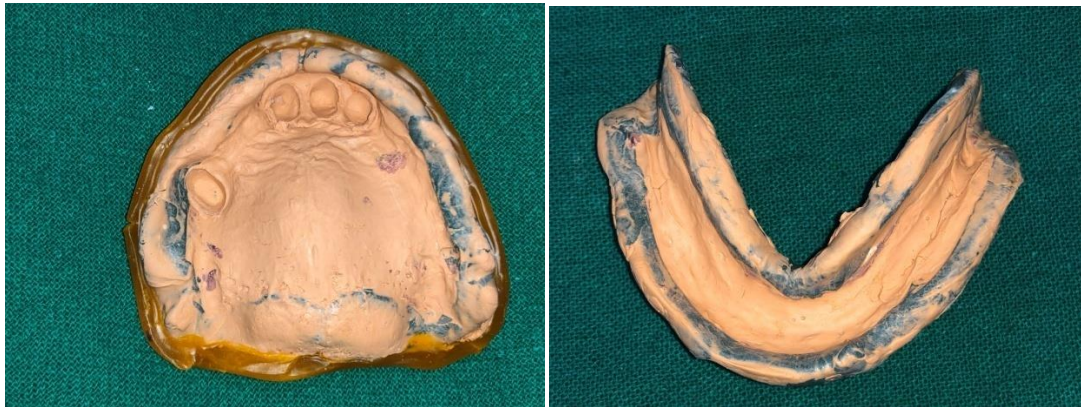

Fig. 5: Maxillary and mandibular final impression



Fig. 6: Maxillomandibular relation

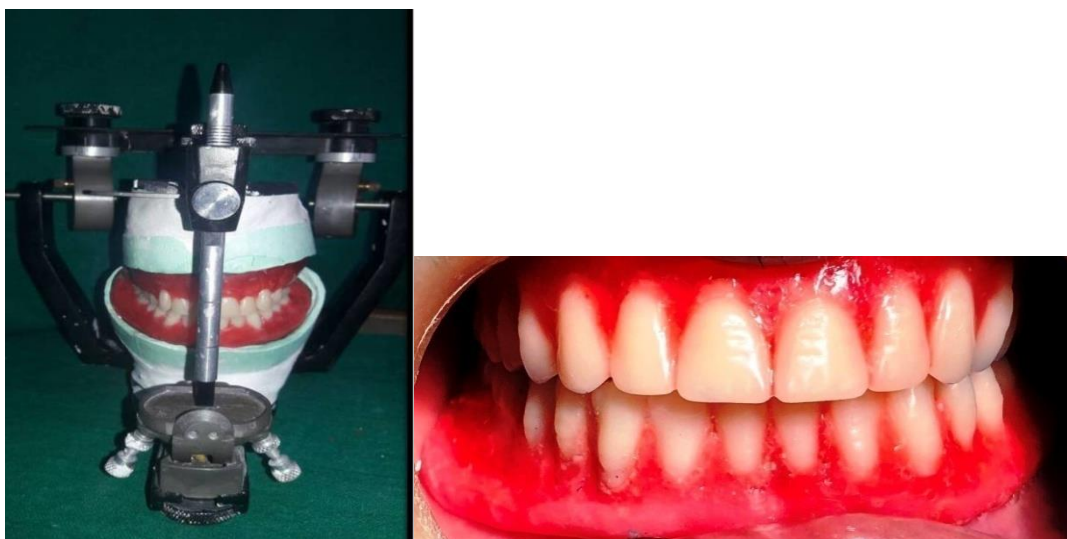

Fig. 7: Try in

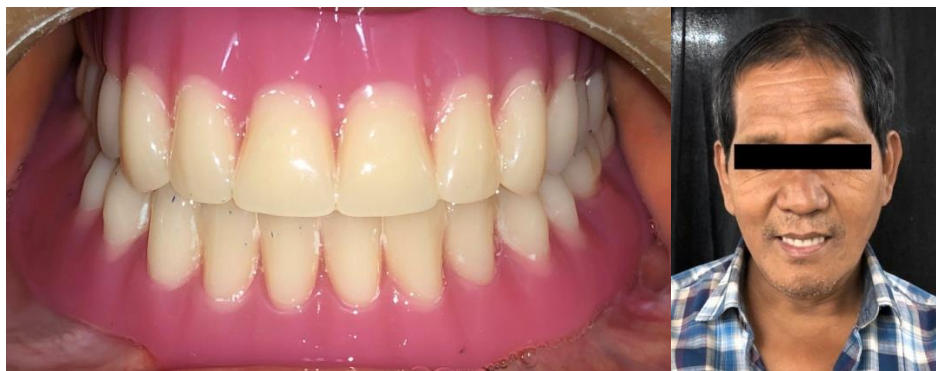

Fig. 8: Final denture insertion

Discussion

The prospect of losing all teeth can have great psychological impact for any patient. It also brings down patient's confidence and make them dependent on others. In such situations, overdenture as one of the preventive treatment option has been incorporated in dental practices due its innumerable advantages.^{1,4} Crum and Rooney graphically reported in study about an average vertical bone loss of 0.6 mm in the mandibular anterior part of overdenture patients with the help of cephalometric radiographs whereas, 5.2 mm vertical bone loss in complete denture patients.⁵ Miller concluded that resorption of alveolar bone depends upon three variables that is the character of the bone, host factor and the trauma to the structures.⁶ Overdenture helps in reducing shrinkage of surrounding alveolar bone and reducing pressure on the alveolar ridge.^{7,8} The benefit of overdenture prosthesis is that proprioception is maintained,⁹ existence of tactile sensitivity with dimensional discrimination and canine response. Average threshold of the tactile sensitivity was found to be 10 times in complete denture wearers on exposure to a load than in completely edentulous patients.¹⁰ Rissin et al compared patients for their masticatory performance with natural dentition, conventional complete denture and over denture. They concluded that chewing efficiency of over-denture patients was one-third higher than that of complete denture patients.¹¹

Conclusion

The tooth supported- over denture has many benefits and applications as compared to complete denture. Its key success depends upon various factors like proper selection of the case. Prosthodontic rehabilitation of such cases provide the patient with good esthetics and function, but also psychologically boosts the confidence of the patients as natural teeth are present.⁷

Conflict of Interest: None.

References

1. Samra RK, Bhide SV, Goyal C, Kaur T. Tooth supported overdenture: A concept overshadowed but not yet forgotten!. *J Oral Res Rev* 2015;7:16-21.
2. Glossary of Prosthodontic Terms 9th edition. *J Prosthet Dent* 2017;117(5S):e1-e105.
3. Winkler S, Essentials of Complete denture Prosthodontics. 3rded.AITBS; 2015
4. Heartwell CM Jr, Rahn AO. Syllabus of Complete Denture. 4th ed. Philadelphia: Lee and Febiger; 1986.
5. Crum RJ, Rooney GE Jr. Alveolar bone loss in overdentures: A 5-year study. *J Prosthet Dent* 1978;40:610-3.
6. Miller PA. Complete dentures supported by natural teeth. *Tex Dent J* 1965;83:4-8.
7. Prakash VS, Shivaprakash G, Hegde S, N. Four and two tooth supported - Conventional over denture: Two case reports. *Int J Oral Health Sci* 2013;3:61-4.
8. Boucher's, Prosthodontic treatment for edentulous patients, 13th edition.
9. Thayer HH. Overdentures and the periodontium. *Dent Clin North Am* 1980;24:369-77.
10. Manly RS, Pfaffman C, Lathrop DD, Keyser J. Oral sensory thresholds of persons with natural and artificial dentitions. *J Dent Res*1952;31:305-12.
11. Rissin L, House JE, Manly RS, Kapur KK. Clinical comparison of masticatory performance and electromyographic activity of patients with complete dentures, overdentures, and natural teeth. *J Prosthet Dent* 1978;39:508-11.

How to cite the article: Kaur H, Bhatia V, Khurana PRS, Buragohain A. Conventional tooth supported overdenture with copings – Can it ever be overlooked? *J Dent Specialities* 2019;7(1):45-8.