

Immediate Loading with Flapless Implant Surgery for Rehabilitation of Single Bound Edentulous Space

Nidhi Bhatia¹, Shweta Bali², Meenu Taneja Bhasin³, Priyanka Aggarwal⁴, Vaibhav Joshi⁵, Shweta Sinha⁶

¹PG Student, ²Professor and Head, ³Reader, ^{4,5,6}Senior Lecturer, Dept. of Periodontics and Oral Implantology, Santosh Dental College and Hospital, Ghaziabad, UP

***Corresponding Author:**

Email: drnidhibhatia@gmail.com

Abstract

This case report presents rehabilitation of single bound edentulous site with flapless implant surgery and immediate loading with Osstem TIII implant.

Introduction

Development of newer and finer techniques is a hallmark of all surgical specialties. Implant dentistry is nonetheless behind when advances are concerned. Over the years there has been an inclination towards minimally invasive implant technique as it is less time consuming, more esthetic and less invasive way to restore dentition. Of the various minimally invasive techniques, flapless techniques are gaining popularity over the older conventional techniques of full thickness flap reflection. The dental literature has documented that more invasive the surgical procedure is, higher the likelihood of losing both alveolar bone and soft tissue, including dental papilla.

Flapless implant surgery is now a predictable procedure with high success rate. William et al suggested that implants placed without flap reflection remain stable and exhibit clinically relevant osseointegration similar to implants placed with flapless procedure.⁽¹⁾ However, when using this surgical technique several challenges must be taken into consideration, such as the generally 'blind' status that flapless implant placement represents. Therefore, it is mandatory to select patients appropriately and evaluate bone anatomy.⁽²⁾

The loss of bone width cannot be determined on 2-dimensional traditional radiograph and difficult to evaluate clinically.⁽³⁾ The improvements in radiological technologies and dental implant treatment planning software can help the clinicians to acquire a 3-dimensional images of potential implant sites before surgery. By using 3 dimensional (3D) radiographic techniques, such as computerized tomography (CT), anatomic limitations, bone morphology and the surgical site underneath the soft tissue can be evaluated precisely. Therefore, it is now possible to pre-surgically determine with a high degree of accuracy and with 3D view, the best position for implant placement and to plan the implant position and inclination, based on the final prosthetic outcome.⁽⁴⁾

Osseointegrated dental implants have traditionally been placed in accordance with a 2- stage protocol.

Early attempts to load the implant earlier were associated with increased failure rates. This meant the patient had to wait a significant time before prosthesis placement and often had to wear suboptimal provisional prosthesis. In 1990 the first investigation was published suggesting that osseointegrated implants could be loaded early or immediately in selected patients.⁽⁵⁾

The benefits of "Immediate Function" are shortened treatment time, better clinical efficiency and less trauma to the patient and better patient acceptance.⁽⁶⁾

Material and Method

A 34 year old female with missing teeth reported to Department of Periodontics and Oral Implantology, Santosh Medical & Dental College and hospital, Ghaziabad, NCR Delhi.

The patient had 46 missing and desired rehabilitation with implant. After taking proper medical history the patient was sent for blood investigations and CBCT. The CBCT report revealed sufficient amount of bone was present with respect to 46 region (Fig. 1 and 2). After evaluating the CBCT, and keeping in mind that it is a flapless procedure an implant of diameter 4.5 and length 11.5 was selected to be placed. The patient understood the procedure and signed a written informed consent.

On the day of the surgery, the patient received prophylactic antibiotic therapy of amoxicillin (1gms) one hour prior to the surgery. The surgical field was prepared using povidone iodine solution and the areas were anesthetized using 1:2,00,000 local anesthesia.

In the recipient implant sites, a core of soft tissue was removed from over the crestal bone, with the help of a tissue punch (Fig. 3). The implant osteotomy was performed, guided by a surgical stent. (Fig. 4) Pilot drill was used to establish the depth and align the long axis of the implant recipient site. Site was subjectively felt at initial drilling to be characterized by medium or soft.

Then a series of drills were used sequentially according to manufacturer's instructions to widen the

osteotomy site. To be immediately loaded implant had to be inserted at a minimum torque of 35Ncm. To achieve this resistance to implant insertion was objectively recorded with a motor torque device, which was set at 35Ncm. Once the motor stopped, the implant was manually inserted with torque wrench. Once the implant was inserted rigid abutment was placed and

tightened at a torque of 30 Ncm(Fig. 5).

Immediately after the surgery provisional crowns were fabricated with the help of a pre-fabricated surgical stent and temporization material (Fig. 6). Provisional restoration was immediately delivered and implant provisionally loaded.

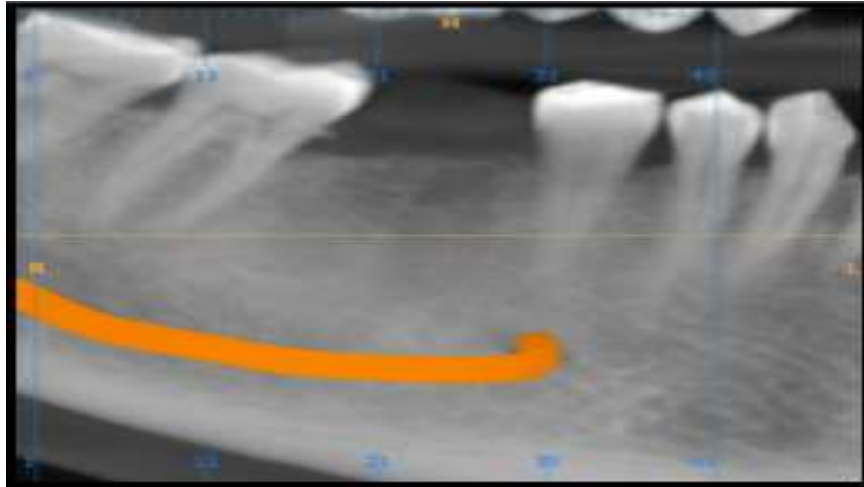


Fig. 1 Pre-operative CBCT, 46 Region

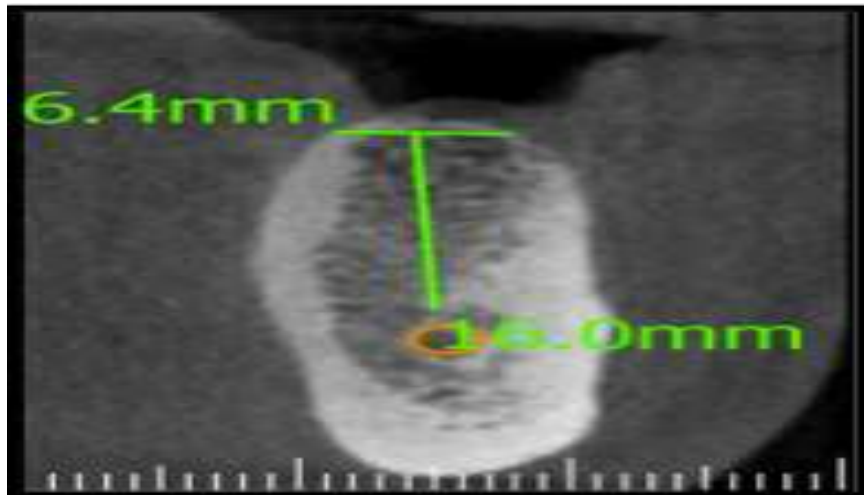


Fig. 2 Pre-operative CBCT, Cross section, 46 Region

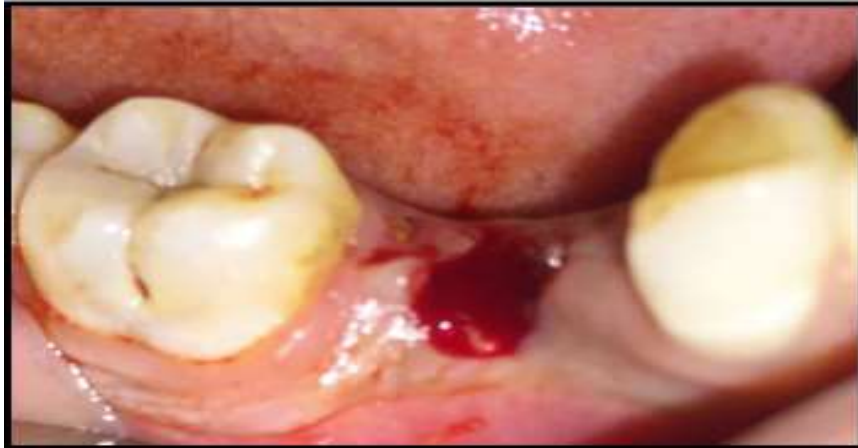

Fig. 3: Core of Soft Tissue Removed with Tissue Punch

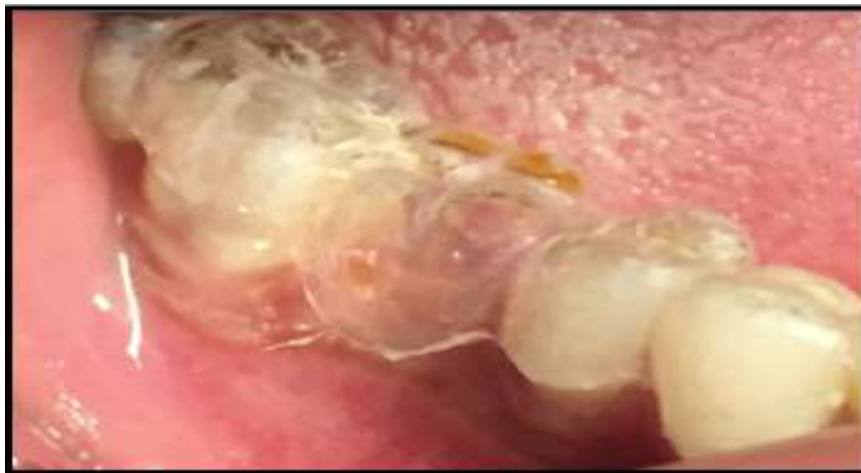

Fig. 4: Surgical Stent

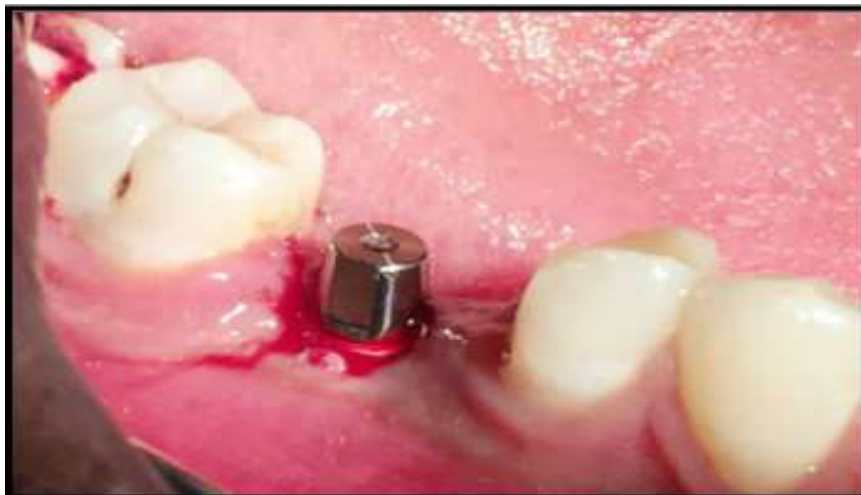

Fig. 5: Rigid Abutment

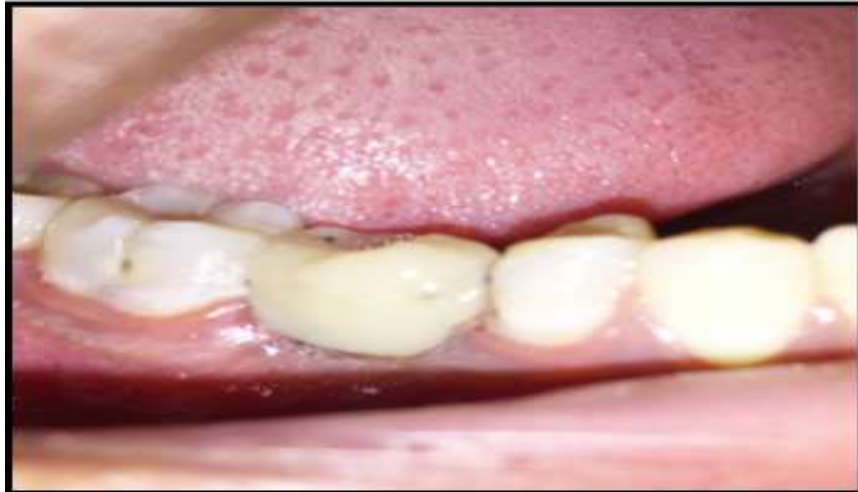

Fig. 6: Provisional Prosthesis Delivered

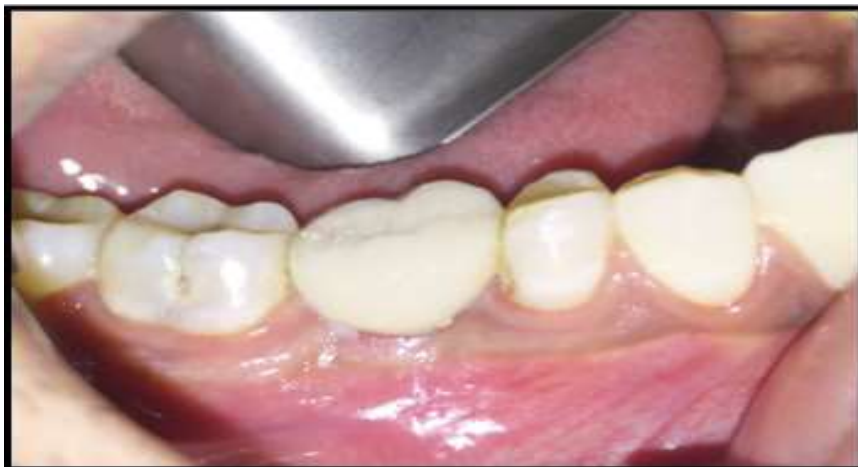

Fig. 7: Final Prosthesis Delivered on 14th Day

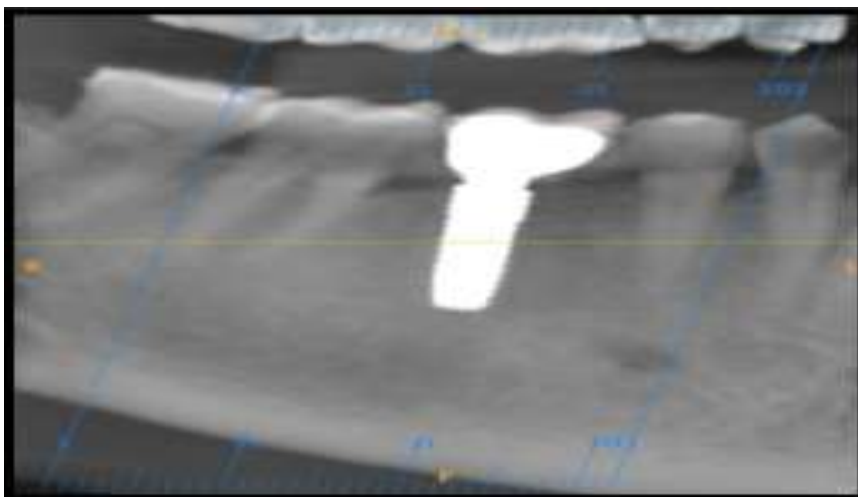


Fig. 8: Post loading CBCT, 46 Region

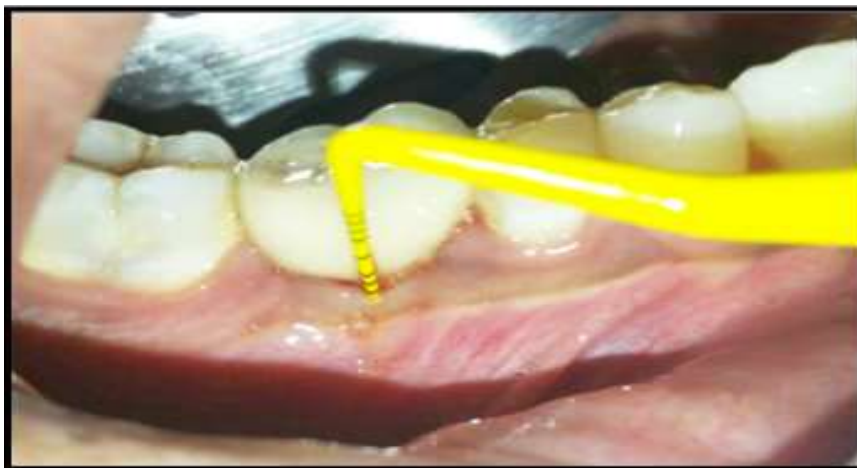

Fig. 9: Recording of Soft Tissue Parameters

Post-Surgical Instructions: After surgery patient was instructed to apply ice pack on the surgical site and was discouraged for spitting for 24 hours and for brushing at the site. Antibiotics were prescribed for 5 days post-operative. Analgesics were prescribed to be taken during meals twice a day. Along with this soft diet was advised.

The patient was called for a follow up the next day.

Prosthetic Phase: On the 12th day the provisional restoration was removed and an abutment level impression was taken with silicone rubber base impression material for fabrication of final prosthesis. The final prosthesis was delivered on the 14th day and kept in centric contact with no excursive contacts. (Fig. 7). A CBCT was done after loading which was considered as baseline. (Fig. 8)

The Outcome Measures Evaluated Were:

Clinical Parameters

- ✓ Implant Mobility: It was measured at the time of loading using two dental instruments handles placed on the buccal and palatal aspects of the crown by a method described by Ericsson et al.⁽⁶⁾
- ✓ Post-surgical pain and post- surgical swelling: Patient self-reported post-surgical pain and swelling: the level of postoperative pain and swelling was recorded. The patients were seen 3 days after implantation procedure for a check up to assess the degree of pain that they felt. Pain and swelling was scored according to the following ordinal scale.⁽⁴⁾
 - 0 – No pain/swelling
 - ✓ Mild pain/swelling
 - ✓ Moderate pain/swelling
 - ✓ Severe pain/swelling
 - ✓ Plaque Index (PI).⁷
 - ✓ Probing Pocket Depth (PPD)

PI and PPD was evaluated at the time of loading, 4 months and 8 months (Fig. 9).

Radiographic Parameter: Crestal bone level on buccal, lingual, mesial and distal aspects of the implants were measured considering using the apex of the implant as the reference point upto the crest, with the help of a CBCT. Radiographic parameters were assessed at the time of loading, at 4 and 8 months.

Results

The probing pocket depth at end of 8 months was 1mm. The plaque index at the end of 8 months was 0.33. The patient reported pain score was 1 and patient reported swelling was 0. The mean crestal bone loss at the end of 8 months was found to be 0.7mm.

Conclusion

Immediate loading of dental implants in selected patients can be as successful as waiting for a conventional healing time when implants of adequate lengths are placed with insertion torques superior to 32 Ncm.⁽⁶⁾

From a patient's perspective it would be ideal to obtain a functional fixed prosthesis on the same day of implant placement, with a minimal surgical intervention as it would reduce discomfort, treatment time and costs if the risk of implant failures is not increased.⁽⁵⁾