

## Masseter Cysticercosis: A Rare Presentation

Deepshikha Rathore<sup>1,\*</sup>, Piyush Arora<sup>2</sup>, Sumita Kaswan<sup>3</sup>, Raj Rathore<sup>4</sup>

<sup>1</sup>Oral Pathologist, Deepshikha Dental Clinics, Jodhpur, <sup>2</sup>Reader, Department of Oral Pathology,

<sup>3</sup>Vice-Principal, Prof. & Head, Jodhpur Dental College, Jodhpur,

<sup>4</sup>3<sup>rd</sup> Year PG Student, Department of Conservative & Endodontic Dentistry, Vyas Dental College & Hospital, Jodhpur

**\*Corresponding Author:**

E-mail: deepshikhadeora@gmail.com

### ABSTRACT

*Cysticercosis is a disease of helminthic origin rarely affecting the humans. Tapeworm may reach humans via infected pork. Disease goes undetected until it evokes a foreign-body type reaction. Radiography and computed tomography helps in provisionally identifying the disease process. Treatment includes surgical removal of the diseased tissue and supportive antibiotic with corticosteroid therapy.*

**Keywords:** *Cysticercosis, Masseter Muscle, Surgical Enucleation*

Access this article online	
Quick Response Code:	Website: www.innovativepublication.com
	DOI: 10.5958/2395-6194.2015.00008.9

### INTRODUCTION

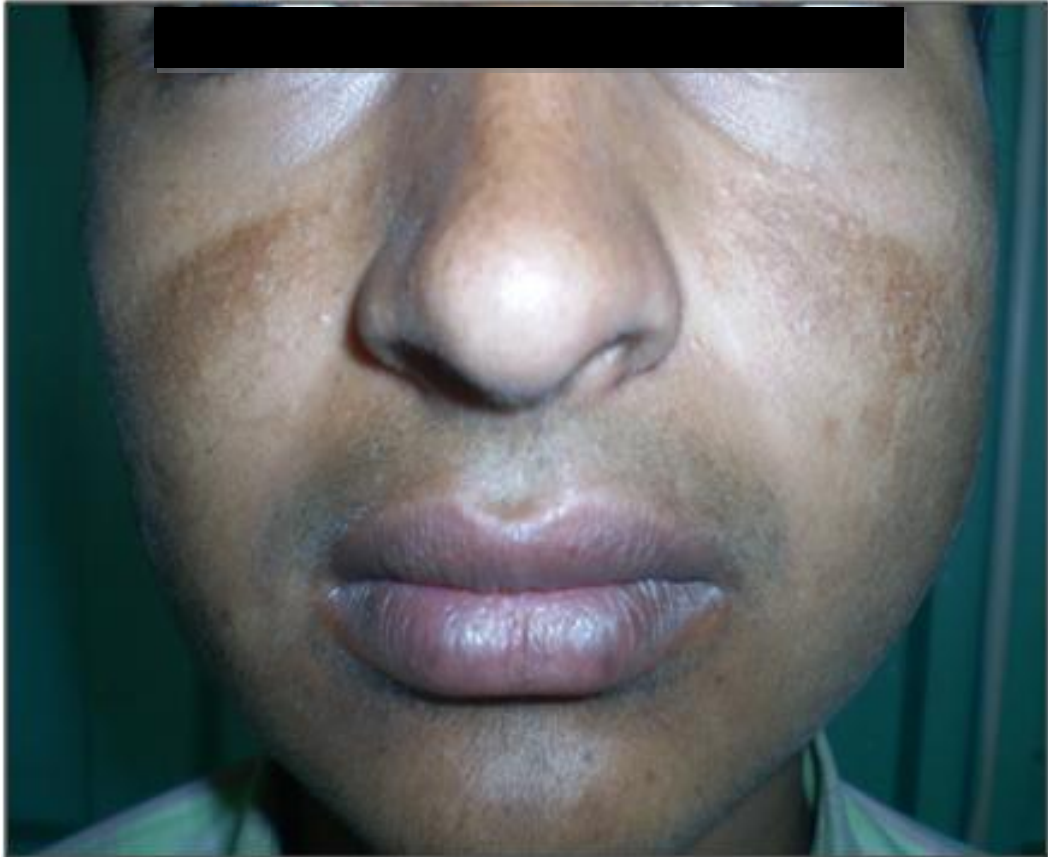Cysticercosis is a helminthic disease caused by larval form of taeniasolium also known as pork tapeworm. This disease is caused by ingestion of eggs of parasite through contaminated food (mainly pork meat) and water.<sup>1,2</sup> Disease is frequently seen in Asian countries along with Russia and Mexico.<sup>3,4</sup> Cysticercosis commonly infests subcutaneous tissues, brain, muscles, heart, liver, lungs and peritoneum<sup>2,5</sup> but is rarely seen involving oropharyngeal regions. Rare cases show involvement of tongue followed by upper and lower lip, oral mucosa, submandibular and submental region. Ingested eggs of the parasite reach intestine. From intestine larva migrate to brain, muscle, eyes or lungs. The disease may remain asymptomatic for years and gets detected by seizures, painful nodules and swelling.<sup>3</sup>

### CASE REPORT

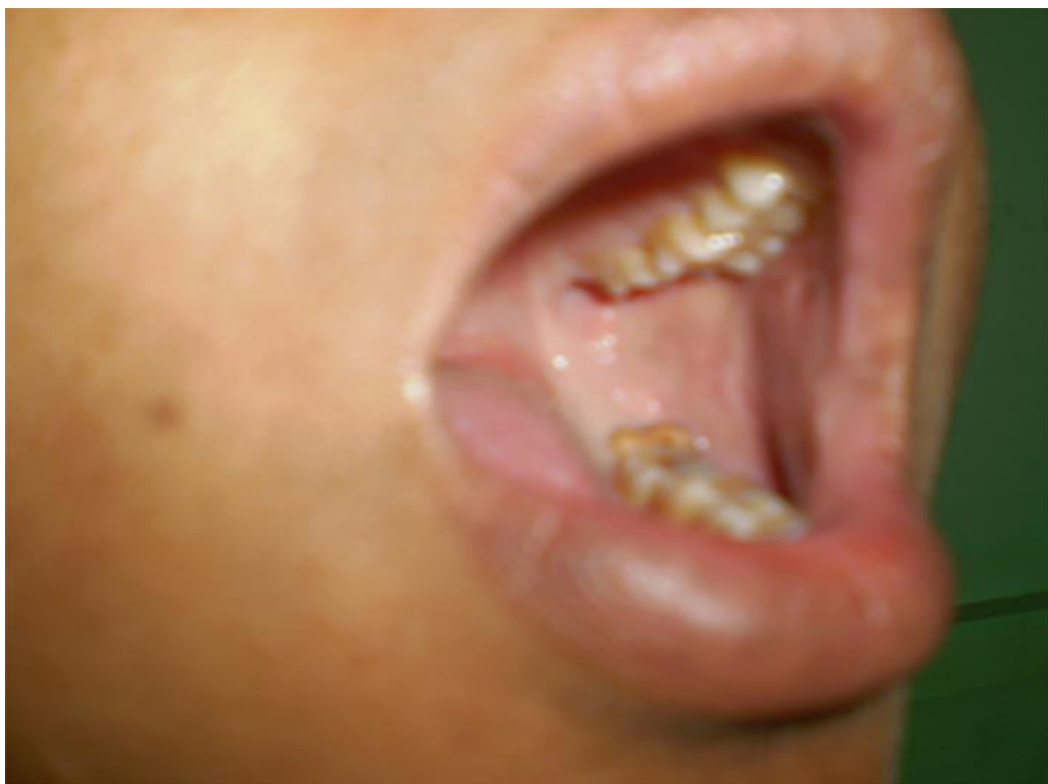A 16 Year old patient reported to the Department of General Medicine, MDM Hospital, Jodhpur, India with

an extraoral swelling on the lower half of left side of face (Fig. 1). The case was then referred to the Oral Pathologist for further review. The swelling was slow-growing and asymptomatic for two months. Two weeks back patient experienced pain along with rapid increase in size of swelling. Clinical examination revealed a large swelling of approximately 4×6 cms, extending from the outer canthus of the left eye to the lower border of the mandible and medially from the nasolabial fold to the ear pinna laterally. On palpating the swelling was firm, tender and non fluctuant. No intraoral manifestation could be seen (Fig. 2). Other systemic findings were negative.

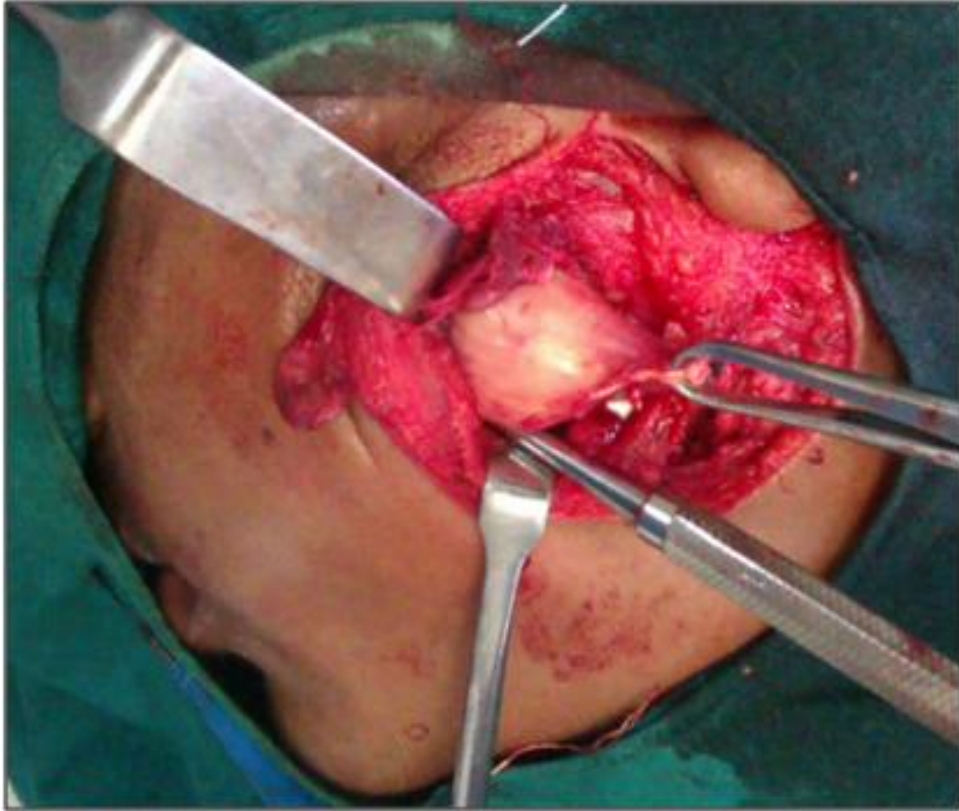Clinical findings were indicative of a benign growth as it was freely mobile and not fixed to the underlying tissues. Surgical enucleation was performed and the diseased mass was enucleated in toto by careful dissection of masseteric muscle preserving its tendon attachments and minimal invasion (Fig. 3). Specimen was sent for histopathological examination (Fig. 4). Microscopic examination revealed a cystic lesion containing degenerated parasitic larva (Fig. 5). The cavity wall was formed of a dense collagenous capsule that comprised of foreign body type giant cells. Infiltration of chronic inflammatory cells was also seen. The larva showed thick integument and myxomatous inner stroma. Based on the histopathological findings diagnosis of “oral cysticercosis” was given.



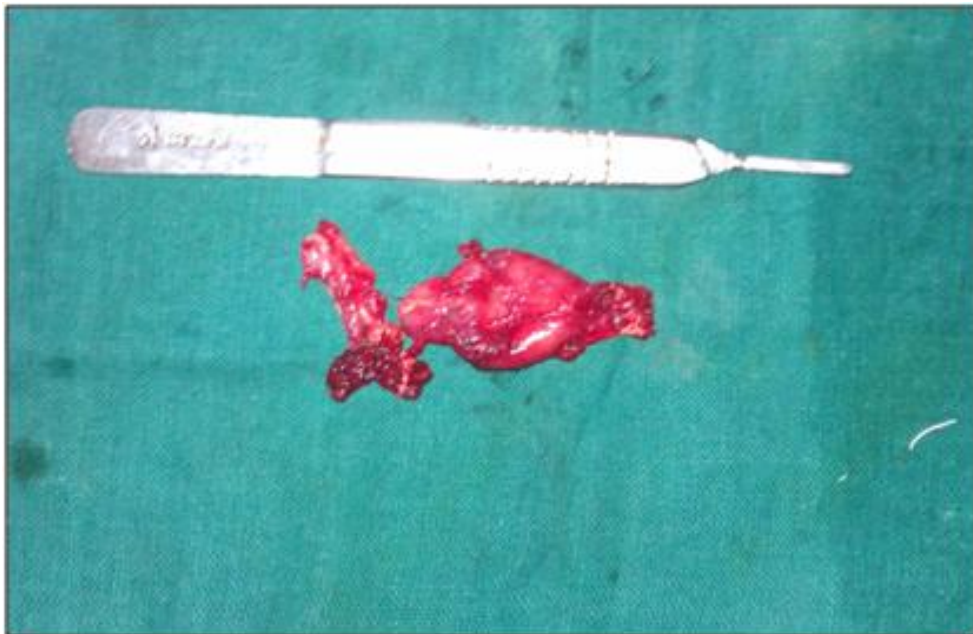
**Fig 1: Clinical photograph showing large swelling on the left side of the face**



**Fig 2: Clinical photograph showing normal appearing left buccal mucosa**

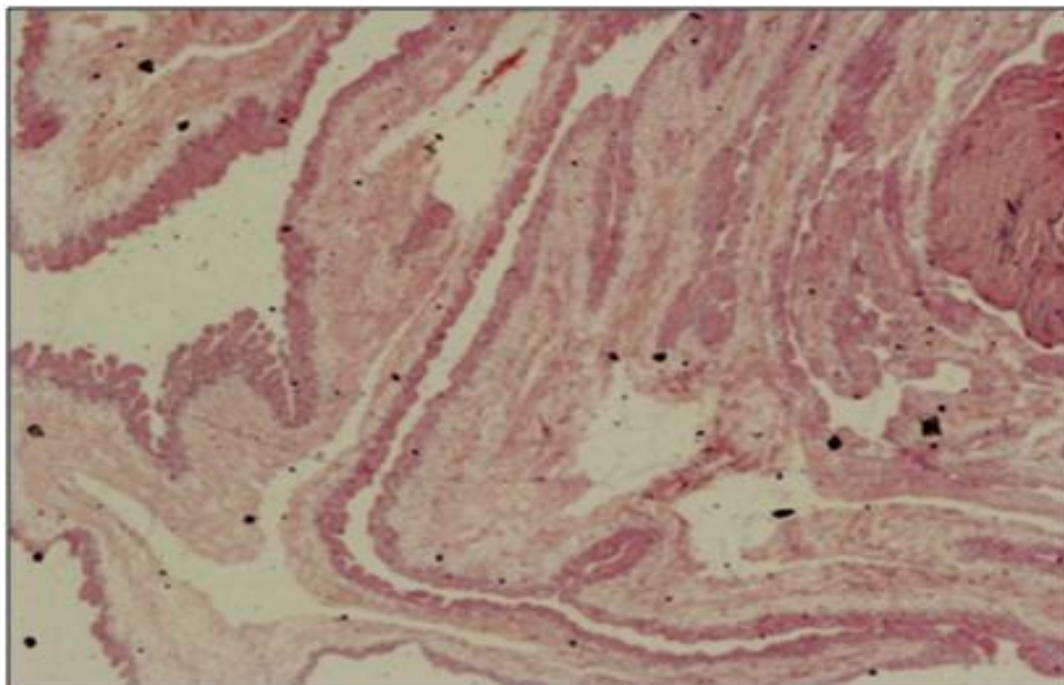


**Fig 3:** Photograph showing surgical exploration of the lesional tissue in preauricular region



**Fig. 4:** Picture showing gross specimen of about 4×2 cms size with supporting connective tissue.





**Fig. 5: Photomicrograph showing larval body with cystic area showing papillary growth and inflammation**

## DISCUSSION

Cysticercosis can reach human chain by ingestion of adult tapeworms or larvae infesting meat of other animals. Humans are the intermediate host and pigs are the definitive hosts for the parasite. The disease is endemic in South America, Asia and Africa.<sup>6,7</sup>

Colonization phase is symptomless or show mild malaise and fever. This latent organism remains inactive for long time. Involvement of CNS may produce headaches, acute obstructive hydrocephalus, seizures and nodules.<sup>8</sup>

The most commonly involved intraoral sites are tongue (42.15%), lips (26.15%) and buccal mucosa (18.9%).<sup>2,7</sup> The involvement of masseter muscle is extremely rare.

Radiographic examination, FNAC, ultrasonographic examination and serology are valuable tools for the identification of disease extent and treatment planning. Histopathologic examination leads us to the definitive diagnosis of the parasitic infection. Radiographically skeletal muscles reveal oblong calcific specks of cysticerci along the muscle fibres giving characteristic rice-grain calcification appearance.<sup>9</sup> Cysticercosis in cytology shows the tegument layer of the larva, hooklets and inflammation in parts of fragments.<sup>10,11</sup> In ultrasonography due to dead larva, inflammatory mass around the cyst is seen.<sup>1</sup> Immunodetection by ELISA (enzyme-linked immunosorbent assay) or EITB (enzyme-linked immune electrotransfer blot) is achieved by the presence of antibodies in the serum.<sup>12</sup>

The treatment of oral cysticercosis is surgical excision. Praziquantel and albendazole are used to treat cysticercosis, especially in patient with disseminated cysticercosis or where surgical excision is risky or not

possible, such as in neurocysticercosis.<sup>13</sup> The oral lesion was the only sign in our patient. Complete enucleation of the lesion was carried out for the patient in this case. Histological examination showed cysticercus surrounded by inflammatory cells.

## CONCLUSION

In the present case report patient had no systemic manifestations except tender swelling on the left side of face. Cysticercosis involving the muscles in the oral cavity is very rare. Appropriate medication, surgical intervention and follow up ensures cure of the lesion. Diagnostic modalities like radiographs, FNAC, ultrasonography, serology provide significant data for diagnosis of the infection but histopathologic examination provides definitive diagnosis.

## REFERENCES

1. Mittla A, Das D, Iyer N, et al. Masseter cysticercosis – a rare case diagnosed on ultrasound. *Dentomaxillofacial Radiology* (2008) 37, 113–116.
2. Chaurasia RN, Jaiswal S, Gautam D, et al. Masseter muscle cysticercosis: a common disease with uncommon presentation. *BMJ Case Rep* 2013. doi:10.1136/bcr-2013-009127.
3. Shrestha S, Shakya M, Shrestha S. Intraoral cysticercosis of the masseter muscle- a rare finding; correlation of histopathology with MRI and USG. *Journal of Chitwan Medical College* 2014; 4(8): 44-47.
4. Singh S, Chhabra S, Aggarwal G, et al. Oral cysticercosis- a rare presentation. *Asian Pacific Journal of Tropical Medicine* 2011;1:587-588.
5. Kulkarni PG, Palakurthy P, Muddana K, et al. Oral Cysticercosis- A diagnostic dilemma. *Journal of Clinical and Diagnostic Research*. 2015;9(6):01-02.

6. K Kumar, A Bansal, H Rai, et al. A Rare Case Of Oral Cysticercosis. *The Internet Journal of Infectious Diseases*. 2010;9:1-5.
7. Elias FM, Martins MT, Foronda R, et al. Oral cysticercosis: case report and review of the literature. *Rev Inst Med Trop* 2005;47(2):95-98.
8. Garcia HH, Evans CAW, Nash TE, et al. Current consensus guidelines for treatment of cysticercosis. *ClinMicrobiol Rev* 2002;15: 747-56.
9. Hawk MW, Shahlaie K, Kim KD, et al. Neurocysticercosis: a review. *SurgNeurol* 2005;63 (2): 123-32.
10. Saran RK, Ratan V, Rajaswansi A, et al. Cysticercosis of oral cavity: report of five cases and a review of literature. *Int J paediat Dent* 1988; 8:273-278.
11. Kamal MM, Grover SV. Cytomorphology of subcutaneous cysticercosis, A report of 10 cases. *Actacytol* 1995;39: 40-43.
12. Patel K, Shah M, Patel B, et al. Subcutaneous oral cysticercosis. *National Journal of Community Medicine* 2011;2: 311-313.
13. Del Brutto OH, Sotelo J, Roman GC. Therapy for neurocysticercosis: a reappraisal. *Clin Infect Dis* 1993;17:30-5.