

Current concepts in diagnosis and management of Grave's orbitopathy: An overview

Shushil Kumar Aggarwal^{1,*}, Rajendra P. Maurya²

¹Assistant Professor, Department of ENT, ²Assistant Professor, Department of Ophthalmology, Institute of Medical Sciences, Banaras Hindu University, Varanasi

***Corresponding Author:**

Email: doc.sushil.pgi@gmail.com

Abstract

Dysthyroid orbitopathy or Thyroid associated orbitopathy (TAO) is a heterogeneous autoimmune orbital inflammatory reaction typically manifested in middle age. The various orbital presentations are lid retraction proptosis, dry eyes, strabismus, diplopia, restriction in extraocular movement and compressive optic neuropathy. The mainstay of therapy for the severe cases remains surgical decompression of the orbital contents into an adjacent space. With the advent of nasal endoscopes, endoscopic decompression has now become the procedure of choice for thyroid associated orbitopathy. Orbital decompression surgery has been indicated in patients with compressive optic neuropathy, severe corneal exposure and cosmetic deformity due to proptosis. In this article, we have done a systematic review of the current published literature to have an outlook about the current concepts, diagnosis and management of thyroid-associated orbitopathy (TAO).

Keywords: Graves' orbitopathy², Proptosis⁴, Orbital decompression³, Endoscopic orbital decompression¹

Introduction

Graves's orbitopathy (GO) also called dysthyroid orbitopathy or thyroid-associated orbitopathy (TAO), is an autoimmune multisystem disorder. The symptoms of Graves orbitopathy is due to immune complex deposition and inflammatory cell infiltration of the orbital fat and muscles and subsequent fibrosis causing an increase in the intraorbital contents leading to proptosis and other symptomatology.¹ T CD4+ lymphocytes are stimulated by auto-antigen, secreting cytokines which stimulate the fibroblasts. Endomysial fibroblasts produce glycosaminoglycane/ mucopolysaccharides which attract fluid in retroorbital space contribute to the inflammatory process and periorbital and muscle oedema, ultimately leading to degeneration of extra ocular muscles followed by fat replacement.²

The clinical features of TAO include watering, photophobia, proptosis, exposure keratitis, diplopia and visual loss. Proptosis is one of cardinal sign of Graves' orbitopathy (GO) which may be unilateral or bilateral (symmetrical Fig. 1 or asymmetrical Fig. 2). Dysthyroid orbitopathy can have four important manifestations. First, cosmetic deformity resulting from proptosis. Second, exposure keratopathy resulting from the inability to close the eyelids. Third, progressive diplopia resulting from impaired extra-ocular

muscle function and last, optic neuropathy resulting from apical orbital crowding and optic nerve compression or its vasculature from the enlarged extra-ocular muscles.³

Depending on degree of inflammatory activity dysthyroid orbitopathy can be divided in two stage 1. Active stage characterized maximum inflammatory changes like interstitial oedema of extraocular muscle and orbital tissue and 2. Inactive stage/ fibrotic end stage characterized by absence or minimal scarring. The first-line treatment in the active stage GO is the immunosuppression with systemic steroids or orbital radiotherapy. Systemic steroids may improve the symptoms but they may have to be continued at high doses for many months. The drawback with steroids is that signs and symptoms often return when the medication is stopped.³ External beam irradiation is efficacious for treating the neuropathy but it do not significantly improve the proptosis. Immunosuppressive agents are still in experimental stage and may have potentially serious side effects.

The mainstay of therapy for the severe cases of TAO remains surgical decompression of the orbital contents into an adjacent space. Orbital decompression for dysthyroid orbitopathy has traditionally been performed either through an external or transantral approach. With the advent

of intranasal endoscopes, the endoscopic orbital decompression approach has now become possible. For acute sight-threatening Grave's disease, surgery is the mainstay of treatment and also the direct and effective way to treat orbital apex syndrome. Ocular recession from endoscopic decompression alone ranges from 2mm to 12mm (average 3.5mm) and concurrent lateral decompression along with endoscopic decompression provides extra 2mm of globe recession.⁴

The goals of the orbital surgery⁵ should be

1. To widen the orbital confinements and reduce the intra-orbital pressure, thus relieving the optic nerve compression.
2. To eliminate the corneal exposure.
3. To correct the cosmetic disfigurement

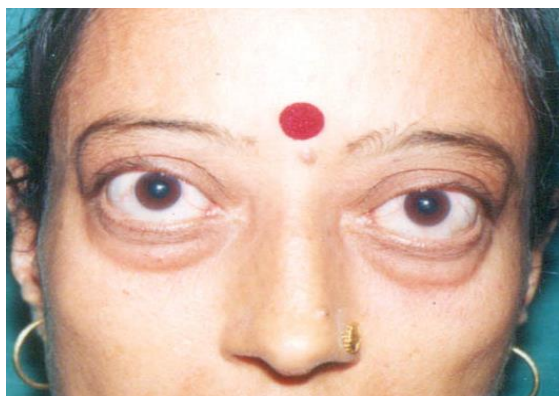

Fig. 1: Bilateral symmetrical proptosis

Pathophysiological mechanisms implicated in optic nerve involvement:

The orbit is an enclosed cone-shaped compartment bounded by bone posteriorly and by the orbital septum anteriorly. The latter being a tight structure, allows only limited forward displacement of the eye in response to increased orbital volume, such as what occurs in TAO. The intact orbital septum can withstand experimental pressures of 50mmHg and up to 120mmHg in some cases.⁶ Orbital pressure is measured to be 3–6mmHg in healthy individuals and at 7–15mmHg in TAO patients.⁷ The final common pathway to visual loss in orbital compartment syndrome appears to be damage to the optic nerve fibres. Compression of optic nerve or its blood supply by the increased orbital contents in TAO especially by the hypertrophied intraocular muscles cause this. Inadequate blood flow in the posterior ciliary arteries, the central retinal artery or vein, or the vasa nervorum of the optic nerve results in a

variety of clinical presentations, including ischaemic optic neuropathy, central retinal artery or vein occlusion, or slow cavernous optic nerve degeneration. The most widely accepted pathophysiologic mechanism for optic nerve involvement is compression of the nerve or its blood supply by the orbital contents in the orbital apex, mainly the extra ocular muscles (EOMS). Many studies have shown a relationship between muscle size, restriction of motility, and DON, while proptosis itself did not correlate well with the risk for DON. Because of the potential risk for blinding DON requires immediate intervention. Studies have correlated intraocular muscle size and restriction of ocular motility with incidence of optic neuropathy. Proptosis does not correlate well with the risk of optic neuropathy. Because of the potential risk of blindness due to dysthyroid optic neuropathy, this condition should be managed urgently.

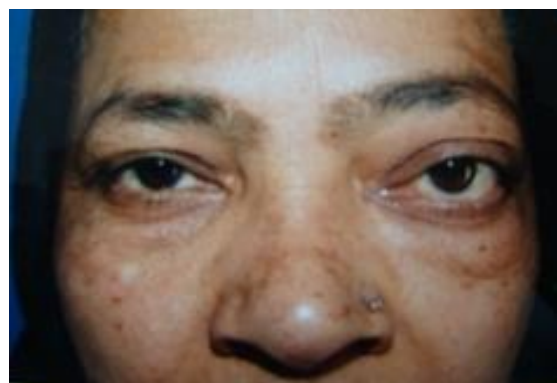

Fig. 2: Asymmetrical proptosis with the hypertropia in primary gaze in the left side

Diagnosis and role of imaging techniques:

Diagnosis of TAO is confirmed by measuring visual evoked potentials (VEP). If it shows increase in latency or reduction in amplitude, the diagnosis is confirmed. If these patients are not diagnosed early and treated aggressively, 30% of them may suffer irreversible loss of vision.⁸ In conjunction with the typical clinical signs of TAO, ultrasonography is sufficient to diagnose the condition. If B scans show enlarged muscle bellies with normal tendon size, the clinical diagnosis of TAO is confirmed. Internal muscle reflectivity in A- and B-scans may be inversely proportional to disease activity.^{9,10} Further information especially concerning the anatomical details and morphologic changes of the orbital soft tissues in the orbital apex can be assessed by computed

tomography (CT) (Fig. 3 & 4) or magnetic resonance imaging (MRI). Magnetic resonance imaging (MRI) can be used to differentiate radiographically between active and inactive diseases. In TAO, the extra-ocular muscles are iso-intense to normal muscle on T1-weighted MRI and hyperintense on T2 depending on the degree of edema (Fig. 5a & b). The absence of edema may demonstrate a fibrotic phase. The correlation of water content (edema) and inflammatory activity can also be detected with MRI short-term inversion recovery (STIR) sequencing. Latest results on the predictive value of the signal intensity ratio (SIR) in MRI-TIRM suggest a correlation between SIR and the clinical activity score (CAS). To differentiate patients with active from inactive eyes disease a cut-off value of >2.5 at 1.5 Tesla was determined.¹¹ The disadvantage of MRI is the poor visualization of bony structures, making it less suitable as a preparatory assessment for decompression surgery. In comparison, CT displays an excellent view of the bony orbit and paranasal sinuses; information that is mandatory if orbital decompression surgery is being considered.

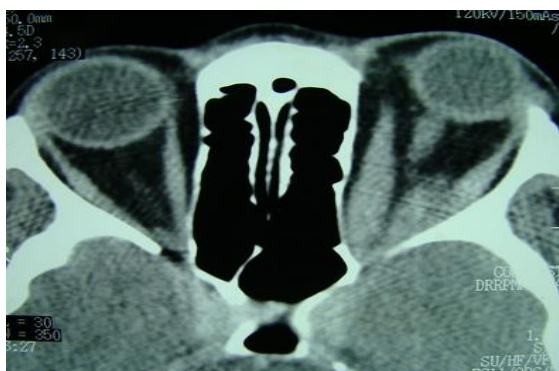

Fig. 3: Axial CT scan through mid-orbit showing left eye, thickening of the medial and lateral rectus muscles with tendon sparing. Asymmetrical changes

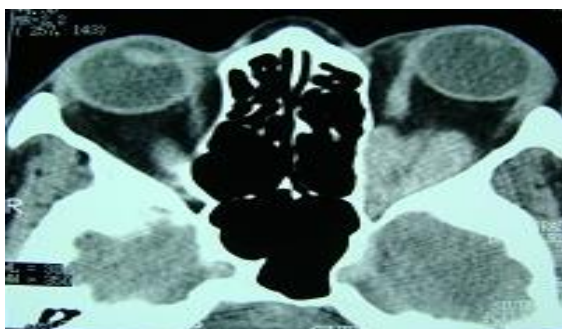
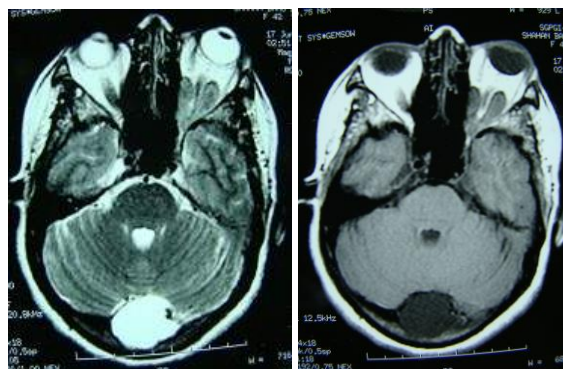


Fig. 4: Axial CT Scan through orbit showing orbital apex syndrome



(a) (b)
Fig. 5: Axial T1-w sequence (a) and Axial T2-w sequence (b) showing thickened rectus muscle and amount of exophthalmos

Criteria for orbital decompression:

Treatment of TAO requires an accurate assessment of disease activity, temporal progression, and severity. The aim of diagnosis is to differentiate the active stage—which represents a potential threatening of visual functions—from the inactive “burnt-out” stage of the disease.

Active moderate or severe congestive orbitopathy usually asks for immediate intervention, whereas active mild orbitopathy may only require supportive measures and a period of observation to discover whether disease is improving or worsening.^{12,13}

Sight-threatening dysthyroid optic neuropathy (DON) occurs in about 5% of patients with Graves' disease. Clinical findings can be loss of visual acuity or colour vision deficiency, visual field defects, relative afferent papillary defect, or optic disc swelling. DON can be confirmed by visual evoked potentials with a significant increase in latency and/or reduction of amplitude. Without treatment, irreversible visual loss occurs in 30% of these cases.⁸ Older age, male gender, and smoking are important factors associated with an increased risk for DON.^{14,15}

Wakelkamp et al.¹⁶ demonstrated in a randomized clinical trial that in the event of DON immediate decompressive surgery does not result in a better outcome compared to medical immunosuppressive treatment. Therefore high-dose intravenous methyl prednisolone therapy is recommended as the first-line treatment. However, if medical treatment does not improve visual functions within a few days or if there is a further deterioration, surgery appears to be the only way to avoid persistent visual loss due to optic nerve atrophy. The apical syndrome with congestion of

the optic nerve in the orbital apex is best treated by a mechanical decompression that addresses the location of the compressive component, that is, by resection of the medial wall in the deep orbit. In those rare instances where DON occurs in the absence of apical compression, increased orbital pressure may be a causative factor in the sense of an orbital compartment syndrome. Appropriate imaging techniques, for example, MRI, are mandatory for differentiating DON caused by apical compression or by compartment syndrome. In the absence of DON, elective reconstructive surgery for exophthalmos reduction or to relieve diffuse retrobulbar pressure sensation is usually considered after ophthalmological findings have been stable for at least 3–6 months. Early rehabilitative orbital decompression does not improve surgical outcome and is associated with a higher risk of induced motility problems.¹⁷ In general, if orbital decompression is needed, it has to be performed before EOM or eyelid surgery because it can affect both extra-ocular muscle balance and eyelid position.¹⁸

Orbital decompression techniques:

History

Earliest report of orbital decompression was published by Dollinger in 1911.¹⁹ He adapted Kroenlein's technique²⁰ for removal of an orbital dermoid cyst to decompress into the subtemporal fossa. The trans-frontal orbital roof decompression advocated by Naffziger in 1931 allowed access to orbital apices of both sides and hence was very useful in managing bilateral disorders. The drawback was that proptosis reduction was not impressive. This procedure was also time consuming as it required assistance from neurosurgeon on the table. Communication of orbit with cranial contents leads to the development of pulsating proptosis.²¹ Sewall's medial approach, introduced in 1936, involved the removal of the medial orbital wall by an external ethmoidectomy including, if necessary, the ethmoid cells and any air cells in the roof of the orbit as far back as the sphenoid sinus, thus allowing the orbital contents to expand medially towards the nose.²² Hirsch in 1950 used the technique described by Lewkowitz to perform inferior orbitotomy by removing the floor of the orbit through Caldwell – Luc approach.²³ A combined approach described by Walsh and Ogura

in 1957 involved a transantral Caldwell-Luc decompression of the medial and inferior orbital walls, which avoided external incisions.²⁴ This approach was widely accepted and used by many surgeons until the early 1980s. However, the high incidence of postoperative diplopia and infraorbital hypoesthesia and even pain were notable complications²⁵ that prompted the search for alternative approaches. With the popular use of nasal endoscope, the entire nasal cavity could be accessed easily under endoscopic vision. Kennedy et al.²⁶ in 1990 performed endoscopic decompression of orbit by removing the medial wall of the orbit under endoscopic vision. To maximize the degree of decompression obtained, he used a Walsh Ogura approach along with a lateral orbitotomy. Later, Michel et al. in 2001 popularized this technique.²⁷ Kennedy²⁶ listed a deviated nasal septum as a contraindication to the endoscopic approach. In our experience, some limited septal surgery can be carried out easily at the same time of the procedure without adding any significant morbidity. The main contraindication is probably coexisting sinonasal disease which needs to be treated before the endoscopic decompression.

Bony orbital decompression:

Bony decompression may involve single or multiple walls of the orbit. Kikkawa et al.²⁸ have proposed a “graded orbital decompression based on the severity of proptosis.” Using the categories defined by Kalmann,²⁹ these authors performed lateral orbital wall decompression with orbital fat removal if exophthalmos was less than 22 mm, additional medial wall decompression if exophthalmos was between 22 and 25 mm, and 3-wall decompression with removal of the orbital floor if exophthalmos was greater than 25 mm. The use of a coronal decompression has been detailed in various publications.^{29,30,31,32,33} In most cases 3-wall decompression is attempted, which results in very effective exophthalmos reduction and improved aesthetic outcome. The main advantage is that the incision can be hidden in patients with an adequate hairline. Hidden incisions are certainly preferable, but they can also be camouflaged by using an upper eyelid crease incision or swinging-eyelid approach for the lateral wall, an inferior fornix transconjunctival incision for the orbital floor, and a transcaruncular incision or endonasal approach for the medial wall. There has been a trend in recent years to

abandon the coronal approach in favour of the alternatives mentioned. As mentioned before two-wall decompression involving the medial wall and the medial aspect of the floor was still the most popular approach until the 1980s. The high incidence of postoperative diplopia because of an inferior globe displacement was avoided by preserving the inferomedial strut located at the junction of the maxillary and ethmoid sinuses.^{34,35} "Balanced" decompression of the medial and lateral orbital walls has gained recent popularity because it may also lessen the occurrence of induced strabismus.^{36,37} It is postulated that this approach may limit inferomedial displacement of the globe and produce an equivalent prolapse of the medial and lateral rectus muscles into the newly created space.³⁸

In a retrospective study Goldberg et al.³⁷ demonstrated that balanced decompression is not more effective compared to deep lateral wall decompression alone in terms of average proptosis reduction (4.5 mm). Interestingly, preoperative strabismus resolved spontaneously in 25% of cases in the balanced decompression group and in 60% of cases in the lateral decompression group. New-onset strabismus was found in 33% in the balanced decompression group compared to just 7% in the lateral wall decompression group. Goldberg et al.²⁷ used CT to calculate the volume of bone available for removal in the deep lateral bony orbit. The "extended lateral orbit" was subdivided into three areas: the "lacrimal keyhole" (area around the lacrimal gland fossa), the "basin of the inferior orbital fissure" (the portion of the zygomatic bone and lateral maxilla and the area around the inferior orbital fissure), and the "sphenoid door jamb" (the thick trigone of the greater wing of the sphenoid which borders the inferior temporal fossa laterally and the middle cranial fossa posteriorly). The "sphenoid door jamb" makes the largest contribution to the total bone volume (5.6mL) of the three areas potentially available for decompression. Proptosis reduction was as much as 6mm. The authors estimated that 0.8mm proptosis reduction might be achieved for every mL of bone removed.³⁹

In a recent publication Mehta and Durrani⁴⁰ presented their results after rim-sparing deep lateral wall decompression via canthal incision in 21 orbits where they found a comparable exophthalmos reduction of 4.8mm with worsening of preexisting diplopia in 1 patient (6%).

An additional alternative for improving the effect on aesthetic rehabilitation is the insertion of sub periosteal orbital rim on lay implants, which are mostly used to camouflage remaining proptosis after decompression surgery.⁴¹ Possible risks include lower eyelid restriction, implant infection, and visible implant edges. The usefulness of endoscopic techniques for medial orbital decompression is still under evaluation. In an early, small series Kennedy et al.²⁶ reported improvement in visual acuity and globe protrusion in 9 out of 16 orbits. Lund et al.⁴² showed mean improvements in axial proptosis of 4.4mm with an endonasal approach compared to 3.8mm with an external procedure. Metson and Samaha⁴³ published an average exophthalmos reduction of 3.5mm in a series of more than 100 patients. Worsening of strabismus after medial wall decompression is a well-known risk due to a shift of the muscle cone into the opened space of the ethmoid sinuses. Though Metson and Samaha⁴⁴ described the orbital sling technique to reduce the risk of motility disturbance following the endoscopic approach, medial wall decompression from our point of view should be reserved for patients with DON due to apical compression, or in the case of reconstructive surgery in patients with severe exophthalmos where maximal exophthalmos reduction is required. A prospective multicenter survey by the orbital surgeons of the EUGOGO group evaluated the outcomes of different techniques and approaches for orbital decompression for disfiguring exophthalmos being preferred around Europe.⁴⁵ They found exophthalmos reduction as a function of the number of orbital walls removed being increased by additional orbital fat resection. A significant improvement of quality of life was observed using the disease-specific quality of life questionnaire⁴⁶ with greatest improvement in the appearance score. As one might expect diplopia was the most common complication with a tendency of the swinging eyelid approach being beneficial compared to the other approaches. Whether stereotactic navigation in decompression surgery as described by Miller and Maloof⁴⁷ offers significant advantages remains to be proven.

Walsh – Ogura decompression:

Traditionally this procedure has been performed to manage Graves's ophthalmopathy. This surgery is performed via transantral Caldwell Luc approach. Two walls of orbit are removed i.e.

medial and inferior walls. Medial wall removal is difficult in this procedure as it is difficult to visualize lamina papyracea transantrally, hence it is virtually impossible to completely decompress medial wall of orbit.²⁴ This procedure is entirely not risk free. If too much inferior wall is taken down, it could cause hypoglobus (inferior displacement of orbit).

Fat Removal Orbital Decompression (FROD):

As been described by Duke Elder²¹ the futility of attempting to remove masses of orbital fat has been proved ever since the account published by von Graefe in 1864. Orbital fat excision may be performed alone or in combination with bony decompression, as mentioned above. FROD for TAO was first described by Olivari in 1988.⁴⁸ He reported "a significantly lower complication rate and higher success rate" compared with BOD after removal of 6mL fat on average.⁴⁹ FROD as primary treatment for exophthalmos seems to be particularly well suited for patients who have a predominant volumetric increase in orbital fat. Careful imaging, preferably with MRI, is needed to discriminate between the tissue entities. Trokel et al.⁵⁰ performed fat excision from the superior nasal and inferior temporal orbital fat compartments. It should be noted that the average volume of fat is about 8mL in a normal orbit but may be 10mL or more in TAO patients.

The authors demonstrated an average proptosis reduction of 1.8mm with orbital fat excision alone, and the greatest average reduction in proptosis (3.3mm) was produced in patients with preoperative Hertel measurements of greater than 25 mm. The original paper by Olivari⁴⁸ describes an average proptosis reduction of 6mm resulting from an average removal of 6.2mL fat. The author noted only a few complications, in particular a rate of new-onset strabismus of 4%. Reported side effects were few, being limited solely to ocular motility disturbances. Thereby main complications are temporary or even permanent motility problems, usually causing diplopia.

Lateral orbitotomy (lateral wall decompression):

This approach is credited with the maximum reduction of exophthalmos. Indications for this procedure include:

1. Esthetic rehabilitation for exophthalmos
2. Retrobulbar pressure
3. Exposure keratopathy/ Lagophthalmos
4. Dysthyroid optic neuropathy

Procedure

This surgery is ideally performed under general anesthesia. Skin incision begins at the lateral third of upper eyelid crease. It follows a sigmoid course over the zygomatic bone. Orbital rim is exposed by blunt dissection. Temporalis muscle in this area should also be removed till the periosteum becomes visible. This exposed periosteum is cut along the orbital rim and stripped away from the bone. Globe and orbital contents are transferred nasally using malleable retractors. Two osteotomies need to be performed to remove the lateral orbital wall. The first osteotomy is just above the fronto-zygomatic suture line and the next one is at the beginning of frontal process of zygoma. After complete removal of lateral orbital wall the average increase in orbital volume works out to 1.6 ml. Periorbita is opened now. Prolapsing fat can be removed. A small suction drain is placed behind the globe and the wound is closed in layers. Compression bandage is applied during first 24 hours. Amount of blood in the drain and pupillary reflex should be constantly checked during the first 24 hours after surgery. It should be borne in mind that intraocular bleeding can cause precipitous increase in ocular pressure compromising vision.

Complications of this procedure include diplopia, loss of vision due to bleeding and increase in intraocular tension, temporary numbness over zygomatico-temporal supply area of trigeminal nerve, mild oscillopsia during chewing and temporalis muscle wasting, etc

Endoscopic Medial wall decompression:

This procedure is still under evaluation. Since the approach is trans nasal, facial incision is avoided. The medial wall of orbit is rather thin in this area. After exenteration of ethmoidal air cells, this wall can easily be taken down allowing the orbital contents to prolapse into the nasal cavity. This procedure can be performed either under LA or GA. The nasal cavity is decongested. Complete uncinectomy and ethmoidectomy is performed.⁵¹ A wide middle meatal antrostomy is performed. The floor of the orbit and the posterior wall of maxilla should be clearly visible through the

antroostomy. A wide antroostomy will not get blocked even after the prolapsing orbital content fills the nasal cavity and maxillary sinus. Infraorbital nerve should be visualized using a 45° endoscope because this represents the lateral limit of bone resection. Frontal recess area should be cleared adequately. Transethmoidal sphenoidotomy should also be performed. Anterior limit of resection corresponds to nasolacrimal duct, while superior limit corresponds to the floor of anterior cranial fossa marked by the presence of ethmoidal arteries. Inferiorly resection should stop at the level of insertion of inferior turbinate. Author invariably removes middle turbinate to create more space for the prolapsing orbital contents.

Lamina papyracea should be completely skeletonized and removed using periosteal elevator. Lamina is removed carefully without traumatizing periorbital. It should completely be removed till the posterior ethmoids, close to the optic nerve where the bone is thicker. Only after fully exposing the periorbital, should it be incised to allow fat to prolapse into the nasal cavity and maxillary sinus cavity. Endoscopic decompression could achieve proptosis reduction up to 3 – 5 mm. Greater reduction can be achieved if combined with lateral orbitotomy.

It is very important to retain lamina papyracea in the region of frontal recess to prevent obstruction due to prolapsing orbital fat. Complications of this procedure include diplopia, sinusitis, frontal & maxillary sinus mucocele and CSF leak.

General guidelines for endoscopic orbital decompression in Grave's orbitopathy:

1. Only that portion of the floor should be removed that lies medial to the infraorbital nerve.
2. Postoperative diplopia can be avoided or reduced if a 10mm wide sling of fascia overlying the medial rectus muscle is preserved during orbital decompression.
3. Do not remove bone in the region of frontal recess, or the herniated fat may obstruct drainage of the frontal sinus. Several external approaches for decompression of the orbital walls have been described in the literature.^{23,52} Decompression of the medial orbital wall and the floor using an external ethmoidectomy incision is most commonly used in spite of the

fact that this approach provides limited access to the orbital apex. Endoscopic surgical technique allows excellent visualization of the landmarks and full decompression of the medial orbital wall which may be extended as far as the optic canal.²⁶ The thicker sphenoidal bone overlying the optic nerve may also be removed more safely using a drill. The inferior wall can be decompressed up to the infra-orbital nerve via a wide middle meatal antroostomy. The endoscopic approach avoids scarring and carries a much smaller risk for the nasolacrimal system and infra-orbital nerve. In Graves's orbitopathy, it is preferred to perform orbital decompression during a chronic phase. The incidence of improvement following endoscopic orbital decompression for Grave's orbitopathy ranges from 22% to 89%.⁵³ Postoperative deterioration of visual acuity occurs in less than 5% of patients.⁴

Complications associated with orbital decompression:

All the available surgical treatments are associated with some degree of diplopia which usually settles, but may require some muscle surgery. This was encountered in our study as well as others using a similar approach.^{42,51} Two other papers found similar increases using a different (trans-antral) approach.^{54,55} All patients were counseled preoperatively that squint and later lid surgery may also be required for optimum cosmetic result. The degree of decompression obtained in our cases, was independent of the pre-operative proptosis. This means that one does not have to allow the proptosis to become severe before operating in order to obtain an optimum decompression, instead surgical decompression should be considered when visual complications first appear or when the cosmetic disability of proptosis becomes significant. This does not agree with the findings of another study using a different (trans-antral) approach.⁵⁶ It is remarkable that all patients were strong supporters of the bilateral simultaneous operation and surgeons should consider this in mind during the initial consultation.

Endoscopic decompression of the orbit produces an effective reduction in proptosis. The average reduction in proptosis is about 3.70 mm using endoscopic technique as reported in various studies in the literature^{42,57} and comparable to the

reduction of 3 to 5.5 mm reported from the non-endoscopic Walsh Ogura technique.⁵⁸ The endoscopic approach offers the advantage of enabling a direct and complete access to the medial orbital wall (lamina papyracea), essential for safe and effective decompression of the orbit and the optic nerve. The transantral route on the other hand approaches the lamina papyracea obliquely, thus making the skull base more vulnerable to injury, and also restricting access to the posterior lamina papyracea. Though the orbital floor removal is more restricted endoscopically as compared to other open approaches, the disadvantage of a limited removal of the floor for correction of proptosis is overcome by an unparalleled removal of the medial wall. Besides, a more aggressive removal of the floor may increase the incidence of hypoglobus and diplopia and infraorbital nerve injury.^{52,59} Various reports in literature also mention that up to 69% of patients undergoing orbital decompression develop postoperative/worsening of pre-existing diplopia and thus all patients should be counseled accordingly prior to surgery.⁵⁹

The surgical methods advocated to avoid diplopia are preservation of a horizontal bony strut at the junction of the medial wall and floor of the orbit⁶⁰ and "balanced decompression" involving removal of both medial and lateral orbital walls^{61,62} so as to avoid the displacement of the orbit in any one direction. The endoscopic approach does not allow access to the lateral orbital wall, thus making it impossible to undertake the "balanced decompression" technique by a pure endoscopic approach. The alternate technique of preservation of the "infero-medial strut" too has proved unsuitable with endoscopic approach as there was difficulty in accessing the subperiosteal plane along the orbital floor with the endoscopic approach and may thus limit the surgeon in achieving a satisfactory decompression.

Conclusion

This approach appears to provide comparable results to traditional methods of orbital decompression while avoiding the morbidity of an external ethmoidectomy or Caldwell Luc procedure. It has the added benefit of less disruption to the patient social life compared to the staged procedure. However, it requires a surgeon with extensive experience in endoscopic sinus surgery.

A number of relatively safe surgical procedures for orbital decompression surgery currently exist, and the approach chosen will be governed by the experience available in the particular centre but should furthermore be tailored to the patient's needs. It is necessary to emphasize that proper decompression requires bracing or even removing the periorbit. The amount of proptosis reduction is influenced by preoperative Hertel values and is greater where exophthalmos is more severe. Current trends in orbital decompression surgery account for the patients preoperative characteristics and intend to limit major complications. These include new-onset diplopia or worsening of preexisting motility deficits related to muscular fibrosis due to TAO and visible and disturbing scars which can be reduced or even avoided by camouflaging incisions (e.g., upper skin crease incision or swinging eyelid approach). In the absence of DON we prefer the lateral wall decompression technique described above because of the following.

1. The operation can be performed by the orbital surgeon himself/herself.
2. Orbital anatomy can be readily visualized.
3. The duration of surgery is not unreasonable.
4. There is a low complication rate without major risks.
5. In particular, there is no significant change in motility.

The indications for surgery have been influenced as the understanding and management of TAO have improved. There is also an increasing appreciation of the facial disfigurement caused by clinical signs, mainly by severe exophthalmos followed by lid retraction. As surgical techniques become more refined, surgeons are better prepared to address this problem. Because of the improved technique and relatively low risk, the lateral technique is also currently used for aesthetic rehabilitation. In decompression for optic neuropathy, the key element is removal of the apical portion of the orbital walls, especially the medial wall. This is usually performed endoscopically in conjunction with an ENT surgeon. For the future a better understanding of the immunological and pathophysiological context of TAO should help to avoid severe and sight-threatening courses of the disease asking for aggressive surgical interventions in the active stage of the disease. But independently, the currently available surgical techniques overall represent safe techniques to

prevent blinding of the patient and furthermore to improve facial appearance and therefore to improve quality of life. During the past century various types of orbital decompression procedures have evolved. The fact that there are so many of these procedures stands testimony to the fact that none of these procedures are completely safe and results produced by them are not optima. With the advent of endoscopic approach to orbital decompression things have started looking up a bit. Endoscopic approaches can be used to decompress medial and inferior wall of orbit, thereby ensuring that orbital contents prolapse into the nasal cavity. Currently practiced procedures of orbital decompression include:

1. Lateral orbitotomy (Kronlein procedure)
2. Superior orbitotomy (Naffziger procedure)
3. Inferior orbitotomy (Walsh Ogura procedure)
4. Endoscopic orbital decompression
5. A combination of various orbitotomy procedures

Ophthalmologists prefer lateral orbitotomy because they are more oriented towards anatomy of the orbit and prefer external approach. Lateral orbitotomy produces the most optimal results in ophthalmologist's hands. Endoscopic orbital decompression is now being performed by otolaryngologists. Since this procedure is still evolving the judgment is not out on this procedure yet.

References

1. Brent GA. Clinical practice. Graves' disease. *N Engl J Med.* 2008;358:2594-605.
2. Jakobiec FA, Font RL. Orbit. In: Spencer W (Ed) *Ophthalmic Pathology.* Saunders, Philadelphia, 1986. p. 2765-2777.
3. Cawood T, Moriarty P, O'Shea D. Recent developments in thyroid eye disease. *BMJ* 2004;329:385-390.
4. Metson R, Dallow RL, Shore JW. Endoscopic orbital decompression. *Laryngoscope* 1994 Aug; 104(8 Pt 1):950-957.
5. Walsh TE, Ogura JH. Transantral orbital decompression for malignant exophthalmos. *Laryngoscope* 1957 Jun;67(6):544-568.
6. J. A. Fleishman, R. W. Beck, and R. O. Hoffman, "Orbital emphysema as an ophthalmologic emergency," *Ophthalmology* 1984; vol. 91, no. 11, pp.1389-1391.
7. V. Kratky, J. J. Hurwitz, and D. R. Avram, "Orbital compartment syndrome. Direct measurement of orbital tissue pressure: 1. Technique," *Canadian Journal of Ophthalmology* 1990; vol. 25, no. 6, pp. 293-297.
8. D. Char, *Thyroid Eye Disease*, Butterworth-Heinemann, Boston, Mass, USA, 3rd edition, 1997.
9. W. Schroeder, "Topographical diagnosis of orbital lesions with contact B-scan ultrasonography," *Klinische Monatsblätter für Augenheilkunde* 1978; vol. 172, no. 1, pp. 12-19.
10. M. F. Prummel, M. S. A. Suttorp-Schulten, W. M. Wiersinga, A. M. Verbeek, M. P. Mourits, and L. Koornneef, "A new ultrasonographic method to detect disease activity and predict response to immunosuppressive treatment in Graves ophthalmopathy," *Ophthalmology* 1993; vol. 100, no. 4, pp. 556-561.
11. E. C. Kirsch, A. H. Kaim, M. G. De Oliveira, and G. Von Arx, "Correlation of signal intensity ratio on orbital MRITIRM and clinical activity score as a possible predictor of therapy response in Graves' orbitopathy—a pilot study at 1.5 T," *Neuroradiology* 2010; vol. 52, no. 2, pp. 91-97.
12. W. M. Wiersinga and M. F. Prummel, "Graves' ophthalmopathy: a rational approach to treatment," *Trends in Endocrinology and Metabolism* 2002; vol. 13, no. 7, pp. 280-287.
13. L. Bartalena, L. Baldeschi, A. J. Dickinson et al., "Consensus statement of the European group on Graves' orbitopathy (EUGOGO) on management of Graves' orbitopathy," *Thyroid* 2008; vol. 18, no. 3, pp. 333-346.
14. G. B. Bartley, V. Fatourechi, E. F. Kadmas et al., "The treatment of Graves' ophthalmopathy in an incidence cohort," *American Journal of Ophthalmology* 1996; vol. 121, no. 2, pp. 200-206.
15. A. Eckstein, B. Quad beck, G. Mueller et al., "Impact of smoking on the response to treatment of thyroid associated ophthalmopathy," *British Journal of Ophthalmology* 2003; vol. 87, no. 6, pp. 773-776.
16. I. M. Wakelkamp, L. Baldeschi, P. Saeed, M. P. Mourits, M. F. Prummel, and W. M. Wiersinga, "Surgical or medical decompression as a first-line treatment of optic neuropathy in Graves' ophthalmopathy? A randomized controlled trial," *Clinical Endocrinology* 2005; vol. 63, no. 3, pp. 323-328.
17. L. Baldeschi, I. M. M. J. Wakelkamp, R. Lindeboom, M. F. Prummel, and W. M. Wiersinga, "Early versus late orbital decompression in Graves' orbitopathy. A retrospective study in 125 patients," *Ophthalmology* 2006; vol. 113, no. 5, pp. 874-878.
18. M. Schittkowski, N. Fichter, and R. Guthoff, "Strabismus surgery in thyroid ophthalmopathy—dose-effect relationships and functional results," *Klinische Monatsblätter für Augenheilkunde* 2004; vol. 221, no. 11, pp. 941-947.
19. J. Dollinger, "Die drickent last lung der augenhokle durch ent furnung der ausseren orbital wand bei hochgradiegen exophthalmos und konsekutwer hornhauerkronkung," *Deutsche Medizinische Wochenschrift* 1911; vol. 37, pp. 1888-1890.
20. R. Kroenlein, "Zur pathologie und operative behandlung der dermoidcysten der orbita," *Orbita* 1888; vol. 4, p. 149, 1888.
21. S. Duke-Elder and P. McFaul, "Orbital involvement in general diseases. I. Endocrine disorders, (Thyreotoxicosis and endocrine exophthalmos)," in *System of Ophthalmology* 1974; The Ocular Adnexa, S. Duke-Elder, Ed., p. 935, Henry Kimpton, London, UK.
22. E. Sewall, "Operative control of progressive exophthalmos," *Archives of Otolaryngology* 1936; vol. 24, p. 621.
23. O. Hirsch, "Surgical decompression of exophthalmos," *Archives of Otolaryngology* 1950; vol. 51, p. 325- 334.
24. T. E. Walsh and J. H. Ogura, "Transantral orbital decompression for malignant exophthalmos," *The Laryngoscope* 1957; vol. 67, no. 6, pp. 544-568.
25. L. Tallstedt, L. Lundblad, and A. Anggär, "Results of transantral orbital decompression in patients with thyroid

- associated ophthalmopathy," *Acta Ophthalmologica Scandinavica* 2000; vol. 78, no. 2, pp. 206–210.
26. D. W. Kennedy, M. L. Goodstein, N. R. Miller, and S. J. Zinreich, "Endoscopic transnasal orbital decompression," *Archives of Otolaryngology* 1990; vol. 116, no. 3, pp. 275–282.
 27. R. A. Goldberg, A. J. Kim, and K. M. Kerivan, "The lacrimal keyhole, orbital door jamb, and basin of the inferior orbital fissure: three areas of deep bone in the lateral orbit," *Archives of Ophthalmology* 1998; vol. 116, no. 12, pp. 1618–1624.
 28. D. O. Kikkawa, K. Pornpanich, R. C. Cruz, L. Levi, and D. B. Granet, "Graded orbital decompression based on severity of proptosis," *Ophthalmology* 2002; vol. 109, no. 7, pp. 1219–1224.
 29. R. Kalmann, "Coronal approach for rehabilitative orbital decompression in Graves' ophthalmopathy," *British Journal of Ophthalmology* 1997; vol. 81, no. 1, pp. 41–45.
 30. R. A. Goldberg, D. A. Weinberg, N. Shorr, and D. Wirta, "Maximal, three-wall, orbital decompression through a coronal approach," *Ophthalmic Surgery and Lasers* 1997; vol. 28, no. 10, pp. 832–843.
 31. M. Mourits, L. Koornneef, W. M. Wiersinga, M. F. Prummel, A. Berghout, and R. Van Der Gaag, "Orbital decompression for Graves' ophthalmopathy by inferomedial, by inferomedial plus lateral and by coronal approach," *Ophthalmology* 1990; vol. 97, no. 5, pp. 636–641.
 32. L. Baldeschi, "Small versus coronal incision orbital decompression in graves' orbitopathy," *Orbit* 2009; vol. 28, no. 4, pp. 231–236.
 33. L. Baldeschi, K. Mac Andie, C. Hintschich, I. M. M. J. Wakelkamp, M. F. Prummel, and W. M. Wiersinga, "The removal of the deep lateral wall in orbital decompression: its contribution to exophthalmos reduction and influence on consecutive diplopia," *American Journal of Ophthalmology* 2005; vol. 140, no. 4, pp. 642–647.
 34. D. A. Paridaens, K. Verhoeff, D. Bouwens, and W. A. Van Den Bosch, "Transconjunctival orbital decompression in Graves' ophthalmopathy: lateral wall approach ab interno," *British Journal of Ophthalmology* 2000; vol. 84, no. 7, pp. 775–781.
 35. K. L. Bailey, R. N. Tower, and R. A. Dailey, "Customized, single-incision, three-wall orbital decompression," *Ophthalmic Plastic and Reconstructive Surgery* 2005; vol. 21, no. 1, pp. 1–9.
 36. K. G. H. Van der Wal, J. G. A. M. De Visscher, R. J. Boukes, and B. Smeding, "Surgical treatment of Graves orbitopathy: a modified balanced technique," *International Journal of Oral and Maxillofacial Surgery* 2001; vol. 30, no. 4, pp. 254–258.
 37. R. A. Goldberg, J. D. Perry, V. Hortaleza, and J. T. Tong, "Strabismus after balanced medial plus lateral wall versus lateral wall only orbital decompression for dysthyroid orbitopathy," *Ophthalmic Plastic and Reconstructive Surgery* 2000; vol. 16, no. 4, pp. 271–277.
 38. D. E. Siracuse-Lee and M. Kazim, "Orbital decompression: current concepts," *Current Opinion in Ophthalmology* 2002; vol. 13, no. 5, pp. 310–316.
 39. R. A. Goldberg, "The evolving paradigm of orbital decompression surgery," *Archives of Ophthalmology* 1998; vol. 116, no. 1, pp. 95–96.
 40. P. Mehta and O. M. Durrani, "Outcome of deep lateral wall rim-sparing orbital decompression in thyroid-associated orbitopathy: a new technique and results of a case series," *Orbit* 2011; vol. 30, no. 6, pp. 265–268.
 41. R. A. Goldberg, A. E. Soroudi, and J. D. McCann, "Treatment of prominent eyes with orbital rim on lay implants: four-year experience," *Ophthalmic Plastic and Reconstructive Surgery* 2003; vol. 19, no. 1, pp. 38–45.
 42. V. J. Lund, G. Larkin, P. Fells, and G. Adams, "Orbital decompression for thyroid eye disease: a comparison of external and endoscopic techniques," *Journal of Laryngology and Otology* 1997; vol. 111, no. 11, pp. 1051–1055.
 43. R. Metson and M. Samaha, "Endoscopic orbital decompression," in *Manual of Endoscopic Lacrimal and Orbital Surgery* 2004; J. J. Woog, Ed., Butterworth-Heinemann, Philadelphia, Pa, USA.
 44. R. Metson and M. Samaha, "Reduction of diplopia following endoscopic orbital decompression: the orbital sling technique," *Laryngoscope* 2002; vol. 112, no. 10, pp. 1753–1757.
 45. M. P. Mourits, H. Bijl, M. A. Altea et al., "Outcome of orbital decompression for disfiguring proptosis in patients with Graves' orbitopathy using various surgical procedures," *British Journal of Ophthalmology* 2009; vol. 93, no. 11, pp. 1518–1523.
 46. C. B. Terwee, M. N. Gerding, F. W. Dekker, M. F. Prummel, and W. M. Wiersinga, "Development of a disease specific quality of life questionnaire for patients with Graves' ophthalmopathy: the GO-QOL," *British Journal of Ophthalmology* 1998; vol. 82, no. 7, pp. 773–779.
 47. M. J. Millar and A. J. Maloof, "The application of stereotactic navigation surgery to orbital decompression for thyroid associated orbitopathy," *Eye* 2009; vol. 23, no. 7, pp. 1565–1571.
 48. N. Olivari, "Transpalpebral decompression in Graves' disease," *Wiener Medizinische Wochenschrift* 1988; vol. 138, no. 18, pp. 452–455.
 49. N. Olivari, "Trans palpebral decompression of endocrine ophthalmopathy (Graves' disease) by removal of intraorbital fat: experience with 147 operations over 5 years," *Plastic and Reconstructive Surgery* 1991; vol. 87, no. 4, pp. 627–641.
 50. S. Trokel, M. Kazim, and S. Moore, "Orbital fat removal: decompression for Graves orbitopathy," *Ophthalmology* 1993; vol. 100, no. 5, pp. 674–682.
 51. Kennedy DW. Functional endoscopic sinus surgery technique. *Arch Otolaryngol Head Neck Surg* 1985;111:643-9.
 52. Golding-Wood PH. Trans-antral ethmoid decompression in malignant exophthalmos. *J Laryngol Otol* 1969; Jul 83(7):683-694.
 53. Hajek M. Pathologie und Therapie der entzündlichen Erkrankungen der Nebenhöhlen der Nase. 5th edn. Tranz Deuticke: Leipzig, 1962.
 54. McCord CD. Current trends in orbital decompression. *Ophthalmology* 1985;92:21-23.
 55. De Santo WL. The total rehabilitation of Graves ophthalmopathy. *Laryngoscope* 1980;90:1652-1678.
 56. Fatourechhi V, Bergstrahl EJ, Garrity JA, Bartley GB, Beatty CW, Offord KP, Gorman CA. Predictors of response to transantral orbital decompression in severe Grave's ophthalmopathy. *Mayo Clin Proc* 1994;69:841-848.
 57. Malik R, Cormack G, Mac Ewen C, White P. Endoscopic orbital decompression for dyscosmetic thyroid eye disease. *J Laryngol Otol*. 2008;122:593-7.
 58. Tjon F, Sang M, Knegt P, Wijngaarde R, Poulblon R, van der Schans E, et al. Transantral orbital decompression for Graves' disease. *Clin Otolaryngol Allied Sci*. 1994;19:290-4.

59. Shorr N, Neuhaus RW, Baylis HI. Ocular motility problems after orbital decompression for dysthyroid ophthalmopathy. *Ophthalmology*. 1982;89:323–8.
60. Wright ED, Davidson J, Codere F, Desrosiers M. Endoscopic orbital decompression with preservation of an inferomedial bony strut: Minimization of postoperative diplopia. *J Otolaryngol*. 1999;28:252–6.
61. Shepard KG, Levin PS, Terris DJ. Balanced orbital decompression for Graves' ophthalmopathy. *Laryngoscope*. 1998;108:1648–53.
62. Graham SM, Brown CL, Carter KD, Song A, Nerad JA. Medial and lateral orbital wall surgery for balanced decompression in thyroid eye disease. *Laryngoscope*. 2003;113:1206–9.