

An unusual presentation of traumatic optic neuropathy

Jayagayathri R.¹, Priyadarshini R.², Dayakar Yadalla^{3,*}, Jayashree B⁴

^{1,3}Medical Officer, ^{2,4}Fellow, Dept. of Orbit & Oculoplasty, Aravind Eye Hospital, Pondicherry

***Corresponding Author:**

Email: drdayakaryadalla@gmail.com

Abstract

Orbital Apex fractures are rare, but debilitating illness affecting vision and they are mostly associated with intracranial injury. We report a four year old child with isolated orbital apex fracture following trivial trauma to his right side of face, presenting 48 hours after injury. He was evaluated and found to have orbital apex fracture with optic neuropathy on right eye. Patient's mother was explained regarding the poor prognosis and no improvement was observed during follow-up. We highlight this case because of the lack of early diagnosis and need for full evaluation in suspected injuries in pediatric population.

Keywords: Orbital Apex fracture, Optic neuropathy, Pediatric orbital trauma

Introduction

Orbital fractures are rare, but debilitating illness affecting vision and cosmesis, these are consequences of mid third facial trauma usually after a high velocity road traffic accident; commonly it is associated with intracranial injuries. They may be accompanied with optic nerve injury and/or superior orbital fissure / orbital apex syndrome. We report a case of delayed management of traumatic orbital apex fracture with optic neuropathy causing vision loss.

Case Report

A four year old boy was brought to our hospital with alleged history of trivial trauma by the handle of bicycle 2 days back, sustaining injury to his right side of face with swelling and pain of right eye; patient was treated conservatively in a local hospital, and referred to our hospital for tertiary care. At presentation, patient had pain and on examination there was no perception of light in right eye (RE). Anterior segment examination revealed sub conjunctival haemorrhage. Pupil was 6mm dilated and relative afferent pupillary defect (RAPD) was noted, all extra ocular movements (EOM) were restricted in RE. Fundus examination and B-scan (to rule out retrobulbar haemorrhage) were normal in RE. LE was normal on examination. With this clinical scenario a provisional diagnosis of Traumatic optic neuropathy was made and patient was started on IV methyl prednisolone and antibiotics, inspite of the delayed presentation (>48 hours). CT brain and orbit was performed, which showed fracture of right lesser and greater wing of sphenoid bone (Fig. 1) extending into orbital apex in the lateral aspect with indentation over the optic nerve (Fig. 2), and no evidence of any intracranial haemorrhage. Patient was subjected to MRI brain and orbit in view of the nerve indentation, which confirmed the CT findings providing additional information of the fracture extension into orbital apex, optic canal and slightly indenting the nerve sheath complex with intra-neural bright signals (Fig. 3) suggestive of post traumatic optic neuropathy. Visual

evoked potential (VEP) showed delayed amplitude and prolonged latency in right eye. Neurosurgeon opinion was sought. Patient was continued on Topical antibiotic drops, oral steroids and was explained regarding the visual prognosis of RE. At 1 month follow up the patient was reviewed, examination revealed persistent total afferent pupillary defect, temporal disc pallor on fundus examination and regained extra-ocular movements on RE. Patient's parents were counseled regarding the poor visual prognosis and advised to take proper care of the LE.

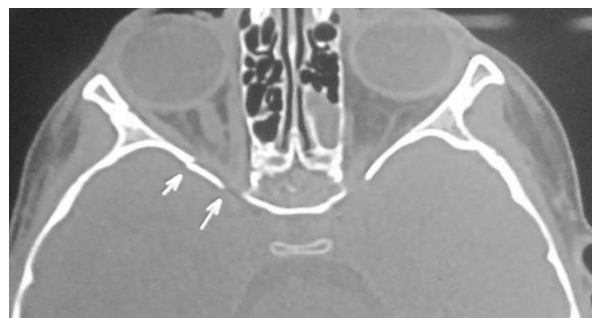

Fig.1: CT Orbit and Brain without contrast showing fracture Greater and Lesser wing of Sphenoid bone

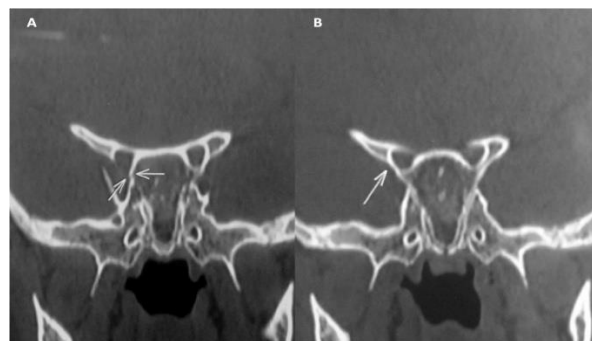


Fig. 2: CT Orbit and Brain without contrast showing A) Fracture orbital apex B) the Fracture extending to the lateral aspect of orbital apex with indentation of optic nerve

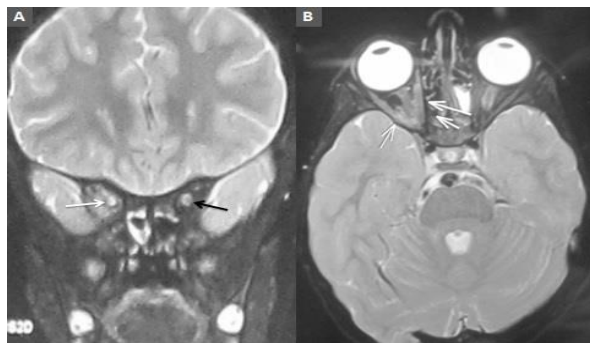


Fig. 3: MRI Orbit and Brain without contrast showing A) Loss of target sign in Right eye (white arrow), positive target sign in Left eye (Black arrow) B) Intra-neural bright signals in right eye

Discussion

Traumatic optic nerve injury occurs due to acute insult to optic nerve secondary to trauma (direct or indirect) and the visual loss may be partial or complete. The direct trauma results from injury to the optic nerve sheath by penetrating objects; whereas indirect trauma results from injury to either central retinal artery or vein or both, resulting in disc ischemia and loss of vision.⁽¹⁾ Traumatic Optic Neuropathy is noted in 0.5–2% of patients with closed head trauma. The common causes of traumatic optic neuropathy are sports injury, fall and road traffic accidents.⁽²⁾ Our patient had a trivial trauma with the handle of his bicycle with no signs of obvious intraocular or extraocular trauma except for mild ecchymosis of Right lower lid.

All pediatric patients should be evaluated completely because the chances of injuries to vital structures are high; because a) the internal organs are in close proximity when compared to adults, b) the increased cranial vault to facial skeleton ratio,⁽³⁾ c) higher proportion of cancellous bone, d) growing sutures and e) the immaturity of facial skeleton;⁽⁴⁾ further more poor patient cooperation is also one of the limiting factors in diagnosing pediatric injuries. RAPD is the main clue to the diagnosis,⁽⁵⁾ hence careful documentation of vision and RAPD should be done to avoid missing of pediatric ocular injuries. Since our patient had no obvious extraocular injury he was managed conservatively initially, but there was no improvement in symptoms. On our referral \approx 48 hours after injury, the patient presented with loss of vision and RAPD on right eye; and CT scan orbit of our patient revealed fracture orbital apex with optic nerve involvement. Therefore it should be kept in mind that even without external injuries orbital fracture can occur, mostly in pediatric population.⁽⁴⁾ CT brain and orbit is considered the gold standard study in pediatric population for evaluating bony anatomy of optic canals and paranasal sinuses; and to rule out intraocular haemorrhage.⁽³⁻⁶⁾ MRI is used in detecting optic atrophy and nerve sheath hematoma,⁽⁷⁾ in our case MRI was done

to look for optic neuropathy changes in optic nerve. Once the diagnosis of traumatic optic neuropathy is suspected the patient should be managed (observation/corticosteroid therapy/ orbital decompression) as per the clinical judgment. The International Optic Nerve Trauma study concluded that no clear benefit was found in mega dose corticosteroid or optic nerve decompression groups following traumatic optic nerve injury.⁽⁸⁾ A Cochrane review on corticosteroids in traumatic optic neuropathy also concluded that there was insufficient evidence to support their use, particularly more than 8 hours after injury.⁽⁹⁾ We started with pulsed dose of methyl prednisolone (250mg) twice daily for three days, expecting visual improvement. But unfortunately there was no improvement in vision; so the parent's were explained regarding the bad prognosis. Visual prognosis after Traumatic Optic Neuropathy depends on various factors such as velocity of impact, time duration from injury to treatment (< 8hrs), age of the patient (>40 years), visual acuity < 20/200, blood in the posterior ethmoidal cells and loss of consciousness during trauma.⁽¹⁰⁾ Our patient's injury was unnoticed for more than 24 hours due to poor patient co-operation; delayed treatment was initiated, but no improvement was noticed even after 1 month follow up. We would like to conclude that 1) proper assessment of visual acuity and documentation of RAPD should be done in all patients with orbital trauma, and 2) CT scan is the gold standard and it should be performed in case of doubt; thereby improving the standard of care in pediatric orbital trauma.

References

1. Renuka S, Chaitra S. Traumatic Optic Neuropathy - A Review. Kerala Journal of Ophthalmology 2008;1:9-17.
2. Paciuc M, Dalma-Weiszhausz J et al. Trauma: Closed-Globe Injuries. AAO, Nov 2015. Available from: <http://www.aao.org/pediatric-center-detail/closed-globe-injuries>.
3. Boyette JR, Pemberton JD, Bonilla-velez J. Management of orbital fractures: challenges and solutions. ClinOphthalmol 2015;9:2127-37.
4. Oppenheimer AJ, Monson LA, Buchman SR. Pediatric Orbital Fractures. Craniomaxillofac Trauma Reconstr 2013;6(1):9-20.
5. Behbehani R. Clinical approach to optic neuropathies. ClinOphthalmol 2007;1(3):233-46.
6. Juan M R, María F G V et al. Classification and epidemiology of orbital fractures diagnosed by computed tomography. Rev. Argent. Radiol 2013;77(2):139-46.
7. Bachi T H, Vicky S K, Supriya R. Traumatic optic neuropathy. Int J OtorhinolaryngolClin 2011;3(3):188-96.
8. Levin L A, Beck R W, Joseph M P, Seiff S, Kraker R. The treatment of traumatic optic neuropathy: the International Optic Nerve Trauma Study. Ophthalmology 1999;106(7):1268-77.
9. Yu-Wai-Man P, Griffiths P G. Steroids for traumatic optic neuropathy. Cochrane Database Syst Rev. 2007 Oct 17;(4):CD006032.
10. Carta A, Ferrigno L, Salvo M et al. Visual prognosis after indirect traumatic optic neuropathy. J NeurolNeurosurg Psychiatry 2003;74(2):246-8.

