

## Microbiological diagnosis of corneal ulcers in a tertiary care center in Mangalore – A prospective study

Sukumar TK.<sup>1,\*</sup>, Rekha Bloor<sup>2</sup>, Maya Nataranjan<sup>3</sup>, Neethu Kishor<sup>4</sup>

<sup>1</sup>Assistant Professor, DM Wayanad Institute of Medical Science, Wayanad, Kerala, <sup>2</sup>Professor & Head, <sup>4</sup>PG Student, Father Muller Medical College & Hospital, Mangalore, Karnataka, <sup>3</sup>Consultant Ophthalmologist, Dept. of Microbiology, Vasan Eye Care, Mangalore, Karnataka

**\*Corresponding Author:**  
Email: sukumartk@gmail.com

### Abstract

**Background:** Aim of this study was the isolation and identification of bacteria, fungus and parasites causing keratitis (corneal ulcer), in and around Mangalore. The cause of keratitis depends on many variables including age, sex and occupation, but the major variable is geographic location. Hence, the diversity of organisms causing keratitis in Mangalore was determined in this study.

**Materials and Methods:** A prospective study was carried out in patients suspected of having infectious corneal ulcer. In this study of 24 months duration, 33 samples were microbiologically profiled using routine smear and culture techniques.

**Result:** Of the 33 samples proceeded, fungal isolates predominated followed by bacteria. No specimen/sample was found to have parasite as the cause of corneal ulcer.

**Conclusion:** There are many causes of keratitis which can be broadly classified as infectious and non-infectious. Infectious causes are still the more common cause in a developing country like India. The pathogen causing corneal ulcer varies with geographic location and in South India the commonly isolated organism is fungi. Parasitic causes are more common in the developed world and are rare causes in our country. Similar studies will aid in the initiation of effective treatment and in preventing loss of vision.

**Keyword:** Keratitis, Corneal Ulcer, Unilateral Blindness.

### Introduction

Keratitis is a term used for inflammation of cornea due to infectious or non-infectious agents.<sup>(1-4)</sup> Microorganisms commonly cause infection when the mechanical defenses i.e., eyelids, eyelashes, tears, cornea are breached. However due to the virulence factors few microbes can cause infection even with intact mechanical and immune defence mechanisms.<sup>(1-4)</sup>

The corneal ulcers can be of two types - infectious or sterile i.e. without infectious organisms. These ulcers can result in corneal opacity which is the fourth largest cause of unilateral blindness and low vision.<sup>(5)</sup> The most common aetiology in India being trauma among the agricultural and manual labourers.<sup>(6,7)</sup>

The various causes of infectious corneal ulcers are as follows<sup>(1,8,9)</sup>

- a. **Bacterial corneal ulcers:** Bacteria are the most common cause of infectious keratitis in the western world. Staphylococci being the most commonly isolated bacteria followed by the gram negative rods. In India, data indicates Streptococci as the most common bacteria.
- b. **Fungal corneal ulcers:** Fungal infections of cornea usually follow trauma especially with vegetable matter. It is the most common cause of infectious keratitis in our country. According to a study by Rosa and colleagues in S. Florida, *Fusarium* species were the most common isolate followed by *Candida*, *Curvularia* and *Aspergillus*. In a study done in South India, *Fusarium* was the most common fungi isolated followed by *Aspergillus* species.<sup>(9)</sup>

- c. **Parasitic corneal ulcers:** More commonly isolated in the contact lens wearing population.

Ex - *Acanthamoeba*, *Onchocerca volvulus*.

### Materials and Methods

**Source:** The study was conducted in the Department of Microbiology, Father Muller Medical College and Hospital for a period of 24 months - August 2013 to July 2015. The samples were collected from Father Muller Medical College Hospital and also from Vasan Eye Care Hospital, Mangalore. Samples of all the corneal ulcer patients investigated during this period were included under the study.

**Exclusion criterion:** The following conditions were excluded from the study:- Viral keratitis, Exposure keratitis, Staph. marginal keratitis, Photokeratitis, Vernal keratoconjunctivitis, Mooren's ulcer, Thygeson superficial punctuate keratitis, Diffuse lamellar keratitis, Autoimmune keratitis.

**Method of collection:** Corneal ulcers suspected by the ophthalmologists to be of microbial aetiology were included in the study. All patients were examined under slit lamp microscope and corneal scrapings were taken from the advancing edge of the ulcer using a sterile Kimura spatula or by using a sterile Bard-Parker blade (NO-15), after instilling 1-2 drops of proparacaine hydrochloride. The most probable aetiology – Fungus/ Bacteria/ Parasite was determined by the ophthalmologists by clinical features and relevant history. The scrapings were then inoculated onto 5%

Sheep Blood Agar, Chocolate Agar for ulcers suspected to be caused by aerobic bacteria and into Robertson's Cooked Meat Broth (RCM) for anaerobic bacteria and Sabouraud's Dextrose Agar (SDA) when fungal aetiology was suspected. Inoculation was done in C formation for each scraping. The scrapings were also smeared onto 2-3 glass slides for staining and transported to laboratory immediately. All the inoculated media, that is, 5% Sheep Blood Agar, Chocolate Agar were incubated at 37°C and examined at 24, 48, and 72 hours for the presence of organisms.

After 48 hrs. of incubation of RCM, it was cultured onto 5% Sheep Blood Agar and Neomycin Blood Agar along with a metronidazole disc and incubated in anaerobic condition at 37°C. The plates were examined after 72hrs for any growth. Any growth with a zone around metronidazole disc was considered to be anaerobic growth and confirmed by Gram's staining.

The specific identification of bacterial isolates was done on the basis of Gram's staining, by microscopy and biochemical properties using standard laboratory criteria. The inoculated SDA media was incubated at room temperature and examined daily until three weeks for growth. Fungi were identified by their colony characteristics on SDA and by the morphological appearance of their hyphae and spores in lacto-phenol-cotton-blue stain.<sup>(10,11)</sup>

When parasitic aetiology was suspected by the ophthalmologist (*Acanthamoeba*), a part of the sample was first observed under microscope as simple wet mount and searched for motile amoebae. The remaining sample was inoculated into a Non Nutrient Agar plate, pre coated with bacteria (*E.coli*). The plate was then sealed with parafilm and it was incubated at 37°C. The plates were examined microscopically for amoebae/ thin linear tracks where amoebae have ingested the bacteria, every day for 10 days.

The samples were considered positive if any of the following criteria was met:-

- Growth of same organism demonstrated on two or more media.
- Consistent with clinical signs.
- Smear results confirms the finding from culture.

### Results and Discussion

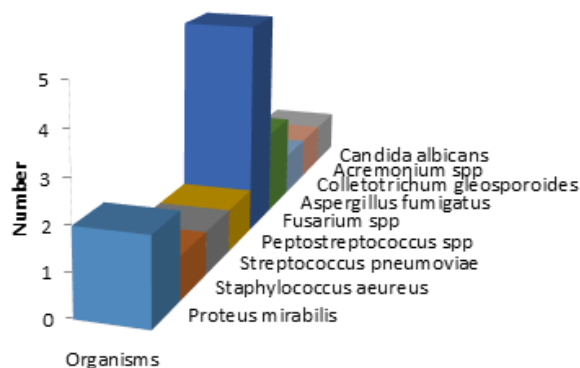
The study was done for two year duration and all the corneal ulcers satisfying the inclusion criteria were included. The present study showed the following results in the 33 samples proceeded.

**Microbiological diagnosis:** Microbiologically presumptive identification as Gram positive/ Gram negative bacteria was done by simple Gram's staining. For ulcers suspected due to fungus, additionally KOH (Potassium Hydroxide) mount was done to look for fungal elements. In total, smear positive samples outnumbered the culture positive samples. Staining

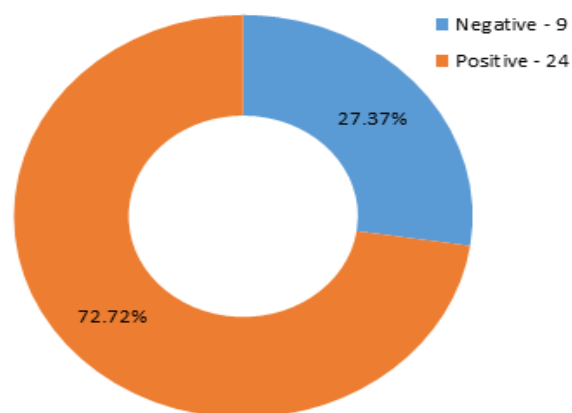
yielded 72.72% positivity rate i.e. 24 of 33 samples showed Gram positive/ Gram negative or fungal elements. Microbiological diagnosis by culture was achieved in 13 samples i.e. 39.39% of the samples. In this study, majority of the corneal scrapings grew Fungi (69%) and two cases had mixed growth.

**Table 1: Organisms Isolated**

Organisms	Frequency
<i>Proteus mirabilis</i>	2
<i>Staphylococcus aureus</i>	1
<i>Streptococcus pneumonia</i>	1
<i>Peptostreptococcus spp</i>	1
<i>Fusarium spp</i>	5
<i>Aspergillus fumigatus</i>	2
<i>Colletotrichum gleosporoides</i>	1
<i>Acremonium</i>	1
<i>Candida albicans</i>	1



**Fig. 1: Organisms Isolated**



**Fig. 2: Smear Positivity Rate**

Microbiological diagnosis was achieved in only 39.39% of the cases, even though 72.72% were smear positive. Review of literature indicated similar percentage in other studies. According to studies by MK Shouja et al,<sup>(12)</sup> Verena et al,<sup>(13)</sup> Behboodhi et al, the isolation rates were 40%, 43% and 49% respectively. In Schaeffer's study isolation rate was 86%.<sup>(14)</sup>

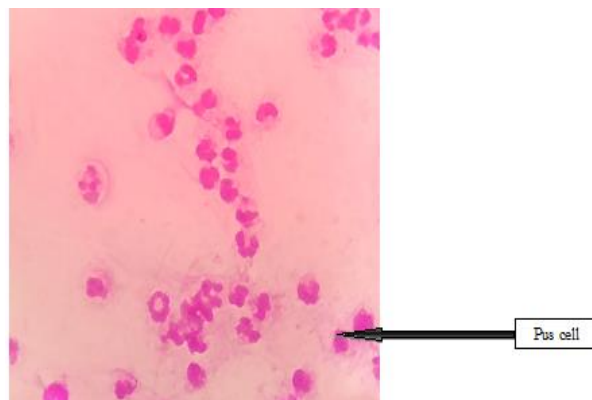
During the review of literature it was also noted that the most common organism causing keratitis is variable and depended on the geographic location.<sup>(6,32)</sup> Climate and occupation played the major part along with other variables like age and habits. In the studies done in western world the main organisms isolated were bacteria, followed by fungi and parasites.<sup>(6,8,9,15)</sup> Whereas, in few studies done in India, most of isolates were fungi in South India and bacteria in North India.<sup>(11,16)</sup> In this study, fungi was isolated in 76.92% of culture positive samples and definite fungal in 62.53% of all the culture positive samples. In a study by Leck et al,<sup>(15)</sup> definite fungal outnumbered definite bacterial isolates. i.e. 44% and 23.9% respectively.

Among the fungi, the most common fungi isolated was *Fusarium* spp followed by *Aspergillus fumigatus*. This is similar to the results obtained by a study done in Madurai by Sharma et al<sup>(17)</sup> where 51% were fungal isolates. The other fungi isolated in this study were *Colletotrichum gleosporoides*, *Candida albicans* and *Acremonium* spp. The fungi causing keratitis are usually ubiquitous in nature and are introduced by trauma by plant origin.<sup>(18)</sup> Hence most of the fungi isolated were *Fusarium* spp which is present in cereal crops and the patients were farmers who got injured during the reaping season. Similar results were obtained in studies by Shanthi J et al,<sup>(19)</sup> Bashir G et al,<sup>(20)</sup> Sharma S et al.<sup>(17)</sup>

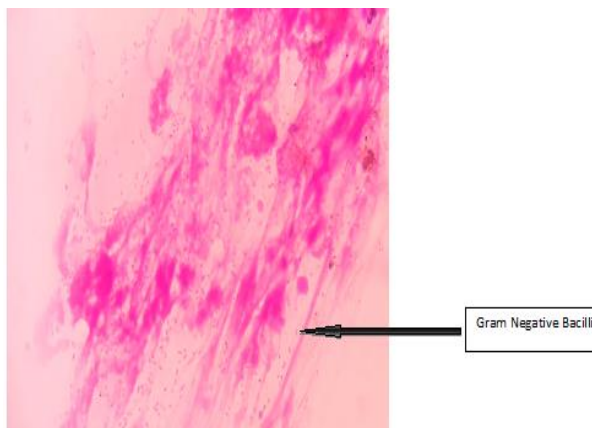
In this study, bacteria were isolated in only five of the thirteen culture positive samples, out of which, pure growth of bacteria was observed in only three samples. This result is similar to other South Indian studies where fungi formed the bulk of etiologic agent. But, bacteria was the most common agent of corneal ulcers in literatures from northern part of India and also the Western countries, which can be seen in the studies done by M K Shoja et al,<sup>(12)</sup> Ormerod LD et al,<sup>(21)</sup> Verena et al,<sup>(13)</sup> Bashir G et al,<sup>(20)</sup> JS Titiyal.<sup>(22)</sup> Among the bacteria, review of literature shows variability in organism that is commonly isolated. According to few studies, *Staphylococcus aureus* is the predominant organism isolate,<sup>(13,19)</sup> whereas, in few other studies *Staphylococcus* species like *epidermidis* was more common.<sup>(12,14,23)</sup> According to the observation of Bashir G et al<sup>(20)</sup> *Streptococcus pneumoniae* was the commonest bacteria. *Pseudomonas* was the common gram negative bacteria that was isolated in most of the studies<sup>(12,13,14)</sup> as opposed to this study, where the predominant gram negative bacteria isolated was *Proteus mirabilis*. The marked difference in results obtained regarding Gram negative bacteria can be explained by the fact that this study was done using samples obtained in a tertiary care centre, wherein most of the patients were either referred from other hospitals after failed attempted treatment or the patients had been administered antibiotics even before he/she came for consultation.

Also in this study, we were able to isolate an anaerobe, *Peptostreptococcus* species in a corneal ulcer due to penetrating injury. According to study by Izthak

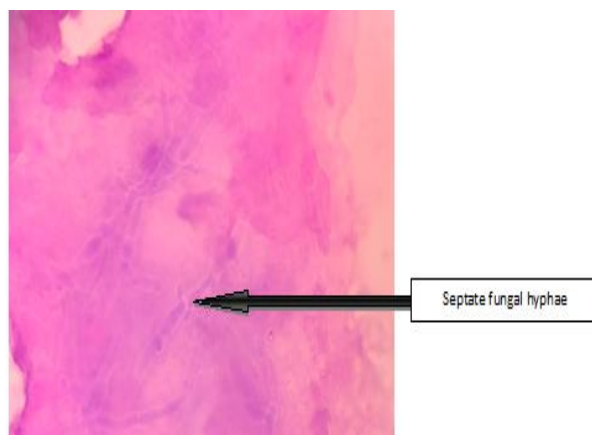
Brook, the anaerobes frequently isolated from corneal ulcers were *Propionibacterium* spp, *Peptostreptococcus* spp, *Clostridium* spp, *Prevotella* spp, and *Fusobacterium* spp.<sup>(24)</sup>



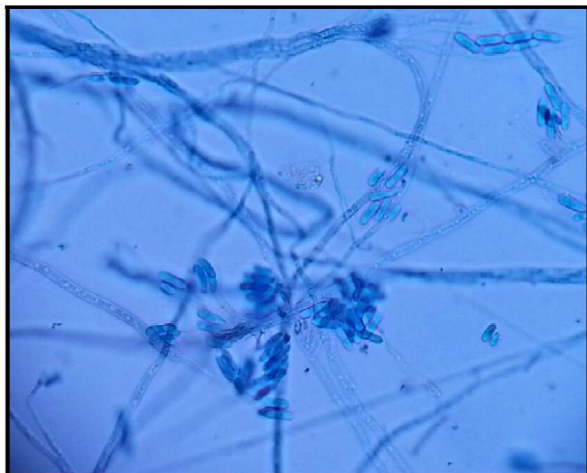**Fig. 3: Corneal ulcer scraping gram stain showing pus cells (oil immersion)**



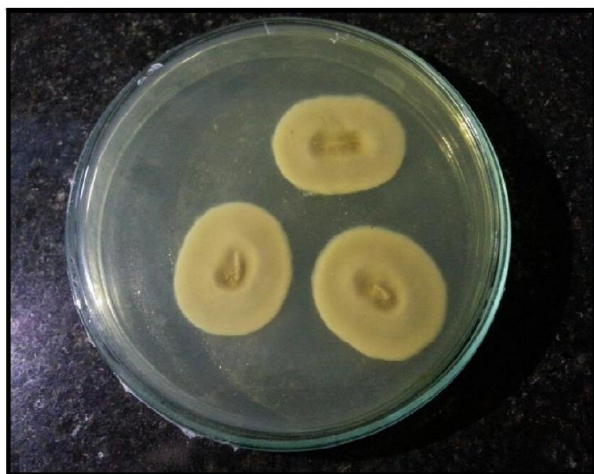**Fig. 4: Corneal ulcer scraping gram stain of bacterial aetiology (oil immersion)**



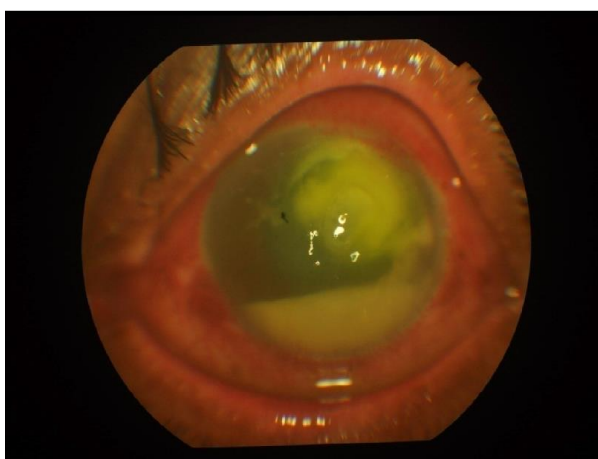
**Fig. 5: Corneal ulcer scraping of fungal aetiology (oil immersion)**



**Fig. 6: Lactophenol Cotton Blue Mount of Acremonium species**



**Fig. 7: Colletotrichum colonies in SDA media**



**Fig. 8: Corneal ulcer**

### Conclusion

The importance of corneal ulcer as the cause of unocular blindness cannot be over emphasized. Corneal ulcers are very common in a developing country like ours and it is of utmost importance to diagnose the

etiology rapidly for early institution of treatment and prevention of vision loss due to scarring.

### Reference

1. A K Khurana Diseases of the Cornea. In A K Khurana (ed). Comprehensive Ophthalmology. 4<sup>th</sup>. Publishers,2007.
2. Agarwal VB, Tsai RJ. Corneal Epithelial Wound Healing. Indian J Ophthalmol 2003;51:5-15,[Downloaded free from <http://www.ijo.in> on Thursday, July 09, 2015].
3. Akpek EK, Gottsch JD. Immune defence at the ocular surface. Eye (Lond) 2003;17(8):949-56.PMID:14631402.
4. Lily Therese K, Madhavan HN. Microbiological procedures of ocular infection, available@ <http://www.ijmm.org>.
5. A Vision 2020: The Right to sight India Publication. Murthy GVS, Das T (ed). Dec2011.New Delhi.
6. Gopinath U, Sharma S, Garg P, Rao GN. Review of epidemiological features, microbiological diagnosis and treatment outcome of microbial keratitis: Experience of over a decade. Indian J Ophthalmol 2009 Jul-Aug; 57(4):273-79.
7. Srinivasan M, Gonzales CA, George C, Cevallos V, Mascarehas JM, Ashokan B, Wilkins J. Smolin G, Whitcher JP. Epidemiology and aetiological diagnosis of corneal ulceration in Madurai, South India. BrJOphthalmol1997;81:965-71.
8. Bacterial Keratitis PPP. Preferred Practice Pattern© Guidelines 2013.
9. Barnes SD, Pavan D, Azad DT. Microbial Keratitis. In Mandell G L, Bennet J E, Doulin R(ed). Principles and Practice of Infectious Diseases, Volume 1, 7thEdition. Churchill Livingstone Publications:1539-55.
10. Henry D Isenberg, Marie P. Ocular cultures. Section 1. In 'Essential procedures for clinical microbiology'. ASM Press 1988, page: 1.13.1-1.13.6.
11. Tewari A, Sood N, Mehta DC. Epidemiological and microbiological profile of infective keratitis in Ahmedabad. Indian J Ophthalmol: 2012;60:267-272.
12. Shoja MK, Manaviat M. Epidemiology and outcome of corneal ulcer in Yazd Shaid Sadougi Hospital, Acta Medica Iranica 2004;42(2):136-141.
13. Prokosch V, Gatziofias Z, Tanos S, Tobias S. Microbiological findings and predisposing risk factors in corneal ulcers. Graefe Arch Clini Exp Ophthalmol Mar2012;250(3):369.
14. Schaefer F, Bruttin O, Zografos L, Crosier YG. Bacterial keratitis: a prospective clinical and microbiological study. Br J Ophthalmol 2001;85:842-47.
15. Leck AK, Thomas PA, Hagan M, Kaliamurthy J et al. Aetiology of Suppurative corneal ulcers in Ghana and south India and epidemiology of fungal keratitis.Br J Ophthalmol 2002;86:1211-15.
16. Ninama GL, Damodar R, Padhiyar NG, Javadekar TB. To study the causative organism responsible for corneal ulcer in SSG hospital Vadodara, Gujarat. National Journal of community Med 2011;237-40.njcmindia.org/uploads/2-2\_237-240.pdf.
17. Sharma S, Srinivasan M, George C. the current status of Fusarium species in mycotic keratitis in south India. Indian J Med Microbiol.1993;11(2):140-47.
18. Jagdish Chander. Oculomycosis in Text Book of Medical Mycology. (ed) Jagdish Chander.3rd edition. Mehta Publishers. New Delhi 2010.
19. Shanti J, Vanajapriya R, Balagurunathan R. Laboratory diagnosis and prevalence of corneal infections from a tertiary eye care hospital. Pelagia research library.

- Advances in Applied Science Research, 2012;3(3):1598-602. Available online at [www.pelagiaresearchlibrary.com](http://www.pelagiaresearchlibrary.com).
20. Bashir G, Shah A, Thokar MA, Rashid S, Shakeel S. Bacterial and fungal profile of corneal ulcers – a prospective study. *Indian J Pathol Microbiol* Apr 2005;48(2):273-77.
  21. Ormerod LD, Hertzmark E. Epidemiology of microbial keratitis in Southern California, a multivariate analysis. *Ophthalmology* 1987;94:1322-33.
  22. Titiyal JS, Negi S, Anand A, Tandon R, Sharma N, Vajpayee R B. Risk factors for perforation in microbial corneal ulcers in North India. *Br J Ophthalmol* 2006;90:686-89. [bj.o.bmj.com/content/90/6/686.full.pdf](http://bj.o.bmj.com/content/90/6/686.full.pdf).
  23. Kunimoto DY, Sharma S, Garg P, Gopinathan U et al. corneal ulcer in elderly in Hyderabad, South India. *Br J Ophthalmol* 2000;84:54-59.
  24. Brook I. Recovery of anaerobic bacteria from clinical specimen in 12 years at two military hospitals. *J.Clin.Microbiol* 1988;26(6):1181-88. [jcm.asm.org/content/26/6/1181.full.pdf](http://jcm.asm.org/content/26/6/1181.full.pdf).