

A cadaveric study of variations in the formation of median nerve

Ritu Agarwal¹, Samta Gaur^{2,*}, Sushma K Kataria³

¹Assistant Professor, ²Senior Demonstrator, ³Senior Professor & HOD, Dr. SN Medical College, Jodhpur, Rajasthan

***Corresponding Author:**

Email: deorasamta@gmail.com

Abstract

The median nerve is one of the commonest nerve showing variations from the level of its formation to its termination. This is an important region where anesthetist, plastic surgeon and oncologist land up with problems more frequently due to variations and the mismanagement will result if they are not aware of these variations. During the routine dissection of 13 cadavers in the Department of Anatomy, Dr. S N Medical College, Jodhpur we find out the variations in the formation of Median nerve. Three specimens show variation in our study, it is formed by more than two roots. There was normal pattern of formation, relation and course of Median nerve observed in rest of the cadavers.

These findings will provide anatomical knowledge for the reliable clinical correlation and surgeries.

Keywords: Median nerve, Variations, Cadaver.

Introduction

Median nerve is formed by the union of lateral root from lateral cord (C5, C6 and C7) and medial root from medial cord (C8 and T1) of brachial plexus lateral or antero-lateral to the 3rd part of axillary artery.⁽¹⁻⁴⁾ The root value of median nerve is (C5, 6, 7, 8, T1). The medial root derived from the medial cord, carries the fibers from C8, T1 after crossing axillary artery from medial to lateral, joins with the lateral root from the lateral cord, anterior to the third part of axillary artery.⁽⁵⁾ The median nerve runs on the lateral side of brachial artery in the arm. Variations in the formation of median nerve are common, more frequent and have been observed by different authors in India.⁽⁶⁻⁷⁾ Knowledge of these variations is essential for performing nerve repair, nerve transplant and reconstructive surgeries. Hence this study would be of great help to the plastic surgeons and orthopedic surgeons. Hence we undertook this study to find out the variations in formation of median nerve in Western Rajasthan populations.

Material and Method

The present study was conducted in the Department of Anatomy, Dr. S N Medical College Jodhpur, Rajasthan, India. The study was done on properly embalmed and formalin fixed adult human cadavers during routine dissection practice for undergraduate students. The routine dissection of 13 cadavers, including 9 males and 4 females were performed during undergraduate teaching of students in the department of anatomy to find out the variations in the formation, course and relation of the median nerve. Dissection was done on both the upper limbs of the cadavers. Variations were observed in three of the cadavers. It was properly cleaned and photographed for proper documentation.

The dissection of axilla and arm was done according to the methods described by Romanes in Cunningham's Manual of Practical Anatomy.⁽⁸⁾ The skin, superficial and deep fascia of the pectoral and axillary region were incised and reflected. The pectoralis major muscle was cut across the clavicular head reflected laterally to its insertion. Pectoralis minor was removed at its origin and reflected superiorly. Loose connective tissue, fat and lymph nodes from the axilla were removed to expose its contents. The brachial plexus and axillary vessels were exposed. The various components of brachial plexus in this region were delineated by careful fine dissection. Adequate care was taken to preserve its relations to important surrounding structures. Brachial plexus was studied systematically,

Observation and Results

During the routine dissection of 13 cadavers in the Department of Anatomy, Dr. S N Medical College Jodhpur we find out the variations in the formation of Median nerve. There was a variation observed in the formation of median nerve. Three specimens show variation in our study, it is formed by more than two roots. There was normal pattern of formation, relation and course of Median nerve observed in rest of the cadavers.

In the right axilla, the medial root was joined by one lateral root to form the main trunk of the median nerve and this was joined by a second lateral root which was given off from the lateral cord. The second root was joined the median nerve proximal to the union of the medial root and the first lateral root (Fig. 1). In the left axilla the arrangement was similar except the lateral cord gives communicating branch to the ulnar nerve and this communicates with median root of median nerve in front of third part of axillary artery (Fig. 2).

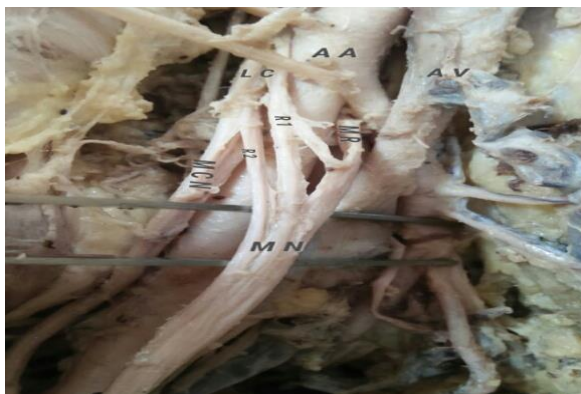


Fig. 1: Showing the formation of Median nerve by three root. (M N: Median nerve, L C: Lateral cord, M C: Median cord, R1: Additional root from lateral cord of median nerve, R2: lateral root of lateral cord of median nerve, M R: Median root from median cord of median nerve, MCN: Musculo-cutaneous nerve, AA: Axillary artery, AV: Axillary vein)

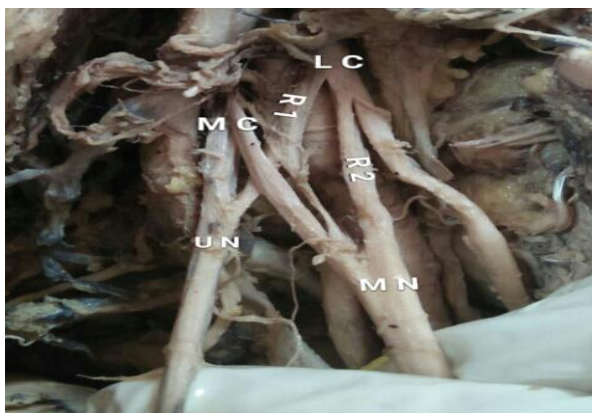


Fig. 2: Showing the formation of Median nerve by three root. (M N: Median nerve, L C: Lateral cord, M C: Median cord, R1: Additional root from lateral cord of median nerve, R2: lateral root of lateral cord of median nerve, M R: Median root from median cord of median nerve), C M: communicating branch to ulnar nerve. Note: figure 2 also showing the communication between root 1 of median nerve and ulnar nerve

Discussions

There are many variations of brachial plexus formation and its relations mentioned in Henry Hollinshed 1969.⁽⁹⁾ The formation of median nerve by three roots from lateral cord and one root from medial cord was found by Uzan et al. 2001.⁽¹⁰⁾ In the present case there are two roots from lateral cord in both the cadavers and one root from the medial cord.

There is also a communicating branch from the second root to the median nerve. There were three cases of unilateral variations of formations of median nerve reported by Satyanarayan et al. 2009.⁽¹¹⁾

There are many reported cases of variations in the formation of the median nerve and up to four roots can

contribute to its formation as opposed to the usual two roots. In a study done on 172 cadavers, Panday and Shukla⁽¹²⁾ report that in 7% of cases the medial root received communicating branches from the lateral or posterior cord in the formation of the median nerve.

Chauhan and Roy (2002) reported the formation of median nerve by two lateral roots and one medial root. Satyanarayana (2010) also reported that formation of median nerve by three roots, two from lateral cord and one from medial cord.

This corresponds with the present study where cadaver 1 and cadaver 2 show a variation in the formation by two roots from lateral cord and one from the medial cord. In present case there is no variation with the musculocutaneous nerve. The additional root LR 2 does not supply any muscle in the arm.

The surgeon has to keep these variations in mind especially during radical axillary dissection and shoulder arthroscopy wherever sparing of the nerve is mandatory.

Conclusion

Axilla is explored during various surgical, anaesthetic, orthopaedic and radiological procedures of upper limb, therefore knowledge of variation with respect to brachial plexus, its branches its relations with axillary artery and brachial artery is very important for medical professionals involved in treatment, surgeries and anaesthetic blocks in axilla or upper limb. The high median nerve entrapment symptoms may be used in differential diagnosis of unexplained clinical symptoms like sensory loss, pain, wakefulness and paresis. The knowledge of such rare median nerve variations is thus important for anatomists, anesthetists, radiologists and surgeons.

References

1. Turner WM. On some variations in the arrangements of the nerves of the human body. *Natural History Review* 1864;4:612-617.
2. Williams PL, Bannister LH, Berry MM, Collins P, Dyson M, Dussek JE, Ferguson D. *Nervous system* In: Gray's Anatomy. 38th Edition. Churchill Livingstone, Edinburgh. 1995; pp 1266-1274.
3. Williams PL, Bannister LH, Berry MM, Collins P, Dyson M, Dussek JE, Ferguson D. *Embryology and development* In: Gray's Anatomy. 38th Edition. Churchill Livingstone, Edinburgh. 1995; pp 231-232.
4. S.K. Pandey, Sushil Kumar. Anomalous formation of Brachial plexus cords and Median nerve. *J. Anat. Soc. India.* 2004;53:31-37.
5. McMinn RMH. *Upper limb*. In: Last's Anatomy. 8th Edition. Churchill Livingstone, Edinburgh. 1990; pp 82.
6. *Grays anatomy. The Anatomical Basis of Medicine and Surgery*. 38th Edition Edinburgh, London, New York, Philadelphia, Sydney, Toronto: Churchill Livingstone. 2000; pp.1266-1272.
7. Satyanarayana N, Guha R. Formation of median nerve by four roots. *J College of Medical Sci-Nepal*, 2008;5:105-107.
8. Krishnamurthy A, Nayak SR, Venkatraya Prabhu L, Hedge RP, Surendran S, Kumar M, Pai MM. The

- branching pattern and communications of musculocutaneous nerve. *J Hand Surg Eur*, 2007;32:560-562.
9. Romanes GJ. *Cunningham's Manual of Practical Anatomy*. Vol I 15th Edition, Oxford University Press, London. 1986; pp 67-74.
 10. Henry Hollinshed W 1969. *Anatomy for Surgeons*, 2nd Edition. Volume 3. New York, Evanston, San Francisco, London: Harper and Row. [3].
 11. Uzan A, Seelig LL Jr. A variation in formation of median nerve: communicating branch between musculocutaneous and median nerve in man. *Folia Morphocol (Warsz)*, 2001;60:99-101.
 12. Satyanartayan N, Vishvakarma N, Kumar GP, Guha R, Datta AK, Sunitha P. Rare variations in the formation of median nerve –embryological basis. *Nepal Med Col J*. 2009;11(4):287-290.
 13. S.K. Pandey, Sushil Kumar. Anomalous formation of Brachial plexus cords and Median nerve. *J. Anat. Soc. India*. 2004;53:31-37.
 14. Chauhan R, Roy TS. Communication between the median and musculocutaneous nerve – a case report. *JASI*, 2002;52:72–75.