

Diagnostic accuracy of MRI in Sonographically Indeterminate Adnexal lesions

Avichala Taxak^{1,*}, Aparna Vijaysinh Dodia², Palak Bhikhabhai Patel³, Harshad Shah⁴, Ashutosh Dave⁵

^{1,2,3}Radiology Resident, ⁴Professor & HOD, ⁵Professor, Dept. of Radiology, CU Shah Medical College & Hospital, Surendranagar, Gujarat

***Corresponding Author:**

Email: taxak.avichala@gmail.com

Abstract

Aims and Objectives:

- The purpose of this study is to assess the ability of MRI in diagnosis of Sonographically indeterminate adnexal lesions.
- To further characterize them in terms of content (solid, cystic, both solid-cystic), origin, tissue characterization (fat, blood, fibrous) and benign vs malignant potential.
- To elucidate the sonographic imaging features leading to indeterminate diagnoses.

Conclusion: Adnexa is a complex structure, a significant proportion of adnexal masses detected by sonography are indeterminate. Sonography remains the initial imaging modality of choice in the assessment of the female pelvis, because it is readily available, inexpensive, safe and quick. Despite the high sensitivity of US, it is rarely specific. This study revealed that sonography performed poorly for determining the origin of the mass, which is the essential first step in characterizing an adnexal mass. MRI with its high contrast resolution & tissue characterization capabilities, helps in accurately resolving these uncertainties.

Keyword: MRI, Comparative studies, Adnexal lesions, Female Pelvis.

Date of Acceptance: 24th April, 2017

Date of Manuscript Receipt: 17th February, 2017

Introduction

Adnexa in general refers to the accessory structures of an organ. In relevance to female pelvis, the term includes, the fallopian tubes and ovaries as well as associated vessels, ligaments, and connective tissue. Adnexal lesions are common in all age groups, but more common in the reproductive age group.

Diagnosis of adnexal mass is difficult and complex, for, it may be benign or malignant, and it's the risk of malignancy that propels for early, accurate and prompt diagnosis. Ovarian cancer is the commonest cause of death from gynecological malignancies and is the fifth commonest cause of cancer deaths in women.

A Sonographically indeterminate adnexal mass is the one that cannot be confidently placed into either the benign or malignant category, or the one for which the site of origin, remains to be established.

Sonography is the initial imaging study of choice in the evaluation of women with suspected adnexal masses because of its widespread availability, relatively low cost, and high sensitivity in the detection of masses.^(4,8,16) However, sonography is limited by its decreased specificity for the diagnosis of benignity, which can vary from 60% to 95% and result in as many as 20% of adnexal masses being classified as indeterminate.^(4,10)

Imaging of the indeterminate adnexal mass is now the most common indication for MRI. Not only is it helpful for problem solving in regards to the indeterminate adnexal mass, but it also provides an effective platform for treatment planning. This is extremely useful particularly in cases of younger

women, in whom exposure to ionizing radiation should be kept to a minimum.

Materials & Methods

A prospective study, carried out from April 2016 to August 2016, under which 50 patients were selected, who were assessed Sonographically and diagnosed as indeterminate lesions using GE LOGIQ P5 machine, then, assessed by using SIEMENS MAGNETOM ESSENZA 1.5T MRI machine for characterization.

Sonography was done using curvilinear transducer (4-8 MHz) and transvaginal probe (8-12 MHz) in Gray scale imaging and color doppler settings.

The routine MRI sequences applied were- coronal T2-weighted half-Fourier single-shot fast spin echo; axial T1-weighted spin echo; sagittal T2-weighted fast spin echo; axial T2-weighted fast spin echo and chemically selective fat suppression.

Inclusion Criteria

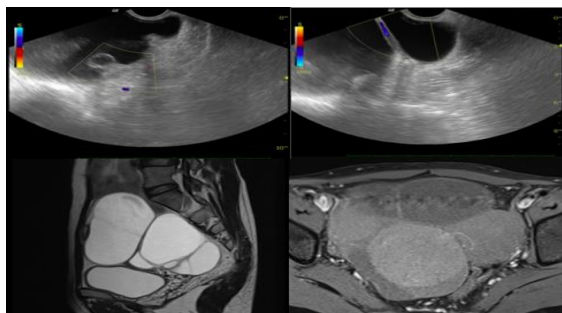
- Female patients of all age groups with lower abdominal or pelvic pain.
- All patients with clinical suspicion of adnexal pathology.

Exclusion Criteria

- Patients with uterine pathologies have been excluded from the study.
- Those patients who had contraindications for MRI investigation.

(Patients with metallic fragments, clips or devices in brain, eye & spinal canal, cardiac pacemakers, insulin pumps, neurostimulators & cochlear implants.)

- Patients who had a history of claustrophobia.



Benign Pathologies

Fig. 1: A 32 year female had complaints of diffuse abdominal pain and loss of appetite. USG shows e/o well defined multilocular cystic lesion with low level internal echoes and internal septations showing internal vascularity, seen in the right adnexa, possibility of Cystic Ovarian neoplasm could not be rule out. MRI elicits, e/o well defined multilocular lesion in the right adnexa, which is hypointense on T1WI with fat suppression and hyperintense on T2W images, with internal septations. Diagnosed as Mucinous Cystadenoma Ovary

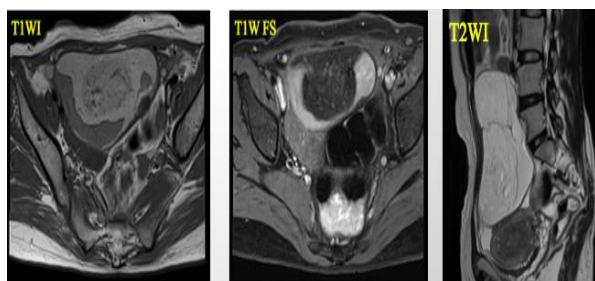


Fig. 2: A 27 year old patient presented with vague abdominal pain and vomiting. MRI shows, the lesion to be hyperintense on both T1W and T2W images, which gets suppressed on T1W Fat saturated images, along with the presence of surrounding hyperintense free fluid. - Ruptured Dermoid Ovarian Cyst

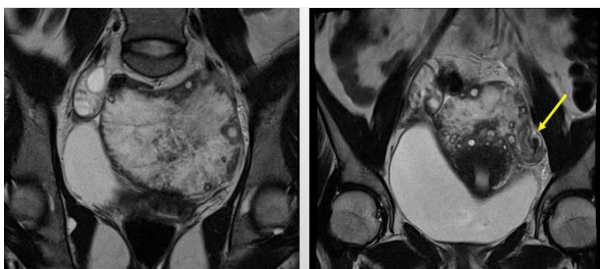


Fig. 3: A 18 year old patient presented with acute abdomen since 2 hours followed by nausea and vomiting. MRI demonstrates, an enlarged left ovary, with hypointense stroma on T2W images with multiple peripherally displaced follicles. Also e/o hypointense twisted vascular pedicle (arrow) seen. Right ovary appears normal. - Ovarian Torsion

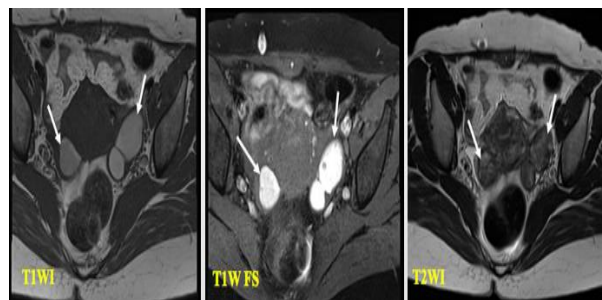


Fig. 4: A 23 year old patient presented with complaints of oligomenorrhea and chronic lower abdominal pain. Axial T2WI shows the lesion to be hypointense (shading), surrounded by follicles, however, on corresponding T1WI, it appears hyperintense, which doesn't suppress on T1 fat suppression images, suggesting presence of blood. - Endometrioma

Malignant pathology

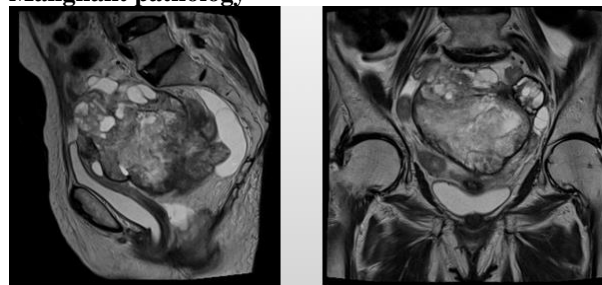


Fig. 5: A 55 year old patient came with complaints of palpable lump in pelvis along with loss of weight and appetite since 5 months. T2WI show e/o ill-defined heterogeneously hyperintense lesion in b/l adnexa, along with loss of fat plane between the lesion and rectum. Both ovaries not seen separately. - B/L Ovarian Malignancy

Discussion

Adnexal lesion has been a common issue in all the age groups, more common in reproductive age groups. Out of which 5-10% of women undergo surgery for suspicious adnexal masses, less than 15% of which prove to be malignant.⁽⁶⁾ Outwater and Dunton⁽¹³⁾ stated that unnecessary or inappropriate surgery was performed in 50-67% of benign cases because of suspicious sonography findings. In our study, 13 out of 50 patients were diagnosed as possible malignant etiologies, which turned out to be benign on further MRI characterization. This suggested that sonography has a poor specificity in diagnosing benign conditions (Table 4). However, with MRI we could accurately characterise these benign conditions. Thus, unnecessary or inappropriate surgery and follow up imaging can be avoided in such cases.

Table 1: Percentage distribution on the basis of tissue content

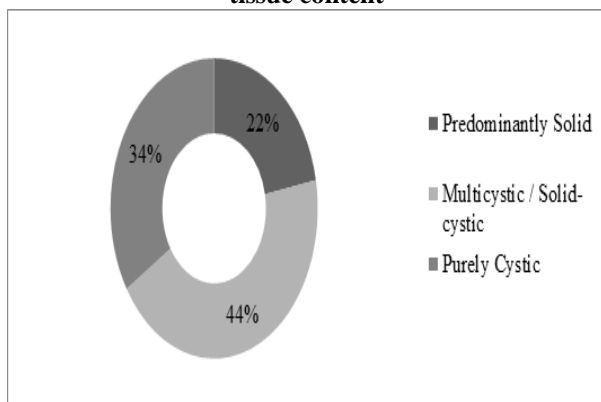


Table 2: Percentage distribution of the lesion on the basis of origin confirmed by MRI

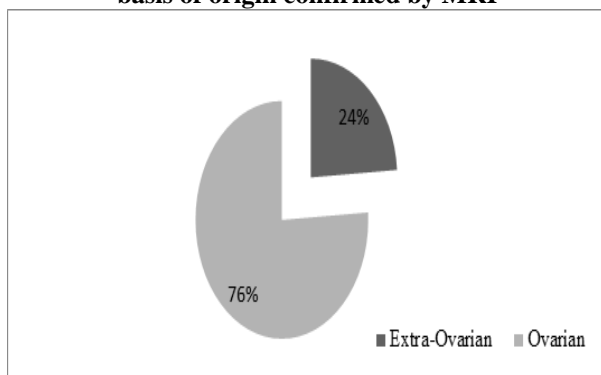


Table 3: Organ of origin of adnexal masses on US and comparison with MRI

Origin	On USG	On MRI
Ovarian	18/50	38/50
Tubal	6/50	8/50
Extra-ovarian	0/50	4/50
Indeterminate	26/50	0/50

Table 4: US features in multicystic / solid cystic masses

Feature	Frequency seen in total cases	Frequency seen in Benign cases	Frequency seen in Malignant cases
Septations/echoes	26/50	20/44	6/6
Papillary excrescences	12/50	8/44	6/6
Solid component	34/50	28/44	6/6

Table 5: Data distribution on the basis of nature of disease on MRI Final Diagnosis (Confirmed by MRI)

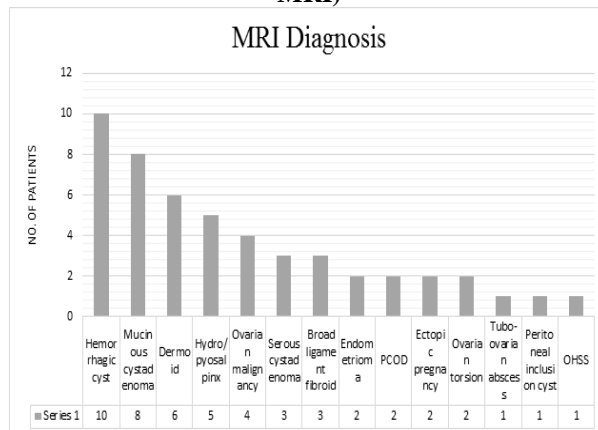


Table 6: Data distribution on the basis of nature of disease on USG v/s MRI

	Benign	Malignant
On USG	31	19
On MRI	44	6

Determining the organ of origin is the essential first step in characterizing an adnexal mass, in our study, sonography performed poorly in diagnosing the origin of the lesion (Table 3). The second essential step of characterizing an adnexal lesion, is accurate tissue characterization, which was poor for sonography and excellent of MRI in our study. In our study, predominantly (44%) found feature seen in the lesions was solid-cystic nature (Table 1).

Benign masses more often than not appeared complex on sonography, thereby mimicking a malignancy. For example, in our study two dermoid cysts, one endometrioma, one tubo-ovarian abscess and one ovarian torsion (Fig. 3) were incorrectly categorized as solid ovarian neoplasms on sonography. So, MRI was particularly useful in determining the character of these lesions. High signal intensity on T1W & low signal intensity ("T2 shading") on T2W images is highly specific for endometrioma^(4,13) (Fig. 4). Dermoid (Fig. 2) is typically hyperintense signal on both T1W and T2W images with characteristic low signal intensity on fat suppressed images.^(5,9) Features highly indicative of malignancy includes, irregular & thick septations of more than 3mm, solid component and papillary excrescences (Table 3).

Sensitivity and specificity of USG in determining the benignity of the lesion:

- Out of 50 patients, 44 were benign and 6 were malignant lesions
- Out of 44 benign lesions, 31 were true positives (TP) and 2 were false negative (FN).
- Out of 6 malignant lesions, 13 were false positive (FP) and 6 were true negative (TN).

So, Sensitivity would be $[\text{TP}/(\text{TP}+\text{FN})]*100 = [31/(31+2)]*100 = 93.93\%$

Specificity $[\text{TN}/(\text{FP}+\text{TN})]*100 = [6/(13+6)]*100 = 31.57\%$

However, because of the small sample size, selective patient recruitment, as only the patients with adnexal masses who were referred to us were recruited, and the overlap of categories for a mass to be indeterminate on sonography, a statistical analysis could not be performed.

The main aim of our study was to evaluate the ability of MRI to characterize and provide additional useful information in cases of indeterminate sonographic findings. Thus, the study concludes, that MRI is an excellent modality for characterisation of adnexal lesions.

Conclusion

This study revealed that sonography performed poorly for determining the origin of the mass, which is the essential first step in characterizing an adnexal mass. MRI with its high contrast resolution & tissue characterization capabilities, helps in accurately resolving these uncertainties.

Most indeterminate masses result from common benign conditions; so, unnecessary or inappropriate surgery can be avoided in such cases. For a few of such masses, which are malignant, instead of a 'wait and watch' strategy of repeat ultrasound, MR imaging results in a more timely diagnosis.⁽⁴⁾

References

- Rosemarie Forstner, Isabelle Thomassin-Naggara, Teresa Margarida Cunha, Karen Kinkel, Gabriele Marselli, Rahel Kubik-Huch, et al. ESUR recommendations for MR imaging of the sonographically indeterminate adnexal mass: an update. *Eur Radiol*, 2016; DOI 10.1007/s00330-016-4600-3.
- Spencer J, Ghattamaneni S. MR Imaging of the sonographically indeterminate adnexal mass. *Radiology*. 2010;256:677-694.
- Miller JC. Incidentally detected adnexal masses. *Radiol* 2007;5:1-4.
- Adusumilli S, Hussain HK, Caoili EM. MRI of Sonographically Indeterminate Adnexal Masses. *Am J Roentgenol* 2006;187:732-40.
- Imaoka I, Wada A, Kaji Y, Hayashi T, Hayashi M, Matsuo M, et al. Developing an MR Imaging Strategy for Diagnosis of Ovarian Masses. *Radiographics* 2006;26:1431-48.
- Sohiab SA, Mills TD, Sahdev a, Webb JAW, Trappen POV, Jacobs IJ, et al. The role of magnetic resonance imaging and ultrasound in patients with adnexal masses. *Clinical Radiology* 2005;60:340-8.
- Saini A, Dina R, McIndoe A, Soutter P, Gishen P, DeSouza NM. Characterizations of Adnexal Masses with MRI. *AJR* 2005;184:1004-9.
- Funt SA, Hann LE. Detection and characterization of adnexal masses. *Radiol Clin North Am* 2002;40:591-608.
- Jung SE, Lee JM, Rha SE, Byun JY, Jung JI, Hahn ST. CT and MR Imaging of Ovarian Tumors with Emphasis

- on Differential Diagnosis. *Radiographics* 2002;22:1305-25.
- Hricak H, Chen M, Coakley FV, et al. Complex adnexal masses: detection and characterization with MR imaging—multivariate analysis. *Radiology* 2000;214:39-46.
- Yu KK, Hricak H. Can MRI of the pelvis be cost effective? *AbdomImag* 1997;22:597-601.
- Sugimura K, Imaoka I, Okizuka H. Pelvic endometriosis: impact of magnetic resonance imaging on treatment decisions and costs. *Acta Radiol* 1996;3:66-8.
- Outwater EK, Dunton CJ. Imaging of the ovary and adnexa: clinical issues and applications of MR imaging. *Radiology* 1995;194:1-18. [Medline]
- Scoutt LM, McCarthy SM, Lange R, Bourque A, Schwartz PE. MR evaluation of clinically suspected adnexal masses. *J Comput Assist Tomogr* 1994;18:609-18.
- Hricak H. Current trends in MR imaging of the female pelvis. *Radiographics* 1993;13:913-9.
- DiSantis DJ, Scatarige JC, Kemp G, Given FT, Hsiu JG, Cramer MS. A prospective evaluation of transvaginal sonography for detection of ovarian disease. *AJR* 1993;161:91-94.
- Kier R, Smith RC, McCarthy SM. Value of lipid and water-suppression MR images in distinguishing between blood and lipid within ovarian masses. *AJR* 1992;158:321-325.
- Sassone AM, Ilan E, Tritsch T, Artner A, Westhoff C, Warren WB. Transvaginal Sonographic Characterization of Ovarian Disease: Evaluation of a New Scoring System to Predict Ovarian Malignancy. *Obstet Gynaecol* 1991;78:70-6.
- Hricak H. MRI of the female pelvis: a review. *Am J Roentgenol* 1986;146:1115-22.