

Impression techniques for removable partial dentures: A review

Reeta Jain^{1,*}, Supriya², Shweta³, Kimmi⁴

¹Professor & HOD, ^{2,3,4}PG Student, Dept. of Prosthodontics, GIDSR, Ferozepur, Punjab

***Corresponding Author:**

Email: rtjn132@gmail.com

Abstract

The use of the removable partial denture to restore the posterior edentulous space continues to be a viable treatment option for patients who are not candidates for cantilever fixed prosthesis or dental implants because of the nature of the remaining teeth and bony support, the anatomy of the residual ridges, or financial constraints. The construction of removable partial denture is a delicate procedure since the prosthesis is supported by two different tissues namely teeth and mucosa. The different resiliency of these supporting tissues may lead to instability of the prosthesis. This article reviews various impression techniques that aim to equalize the masticatory load between teeth and edentulous areas thus enhancing the stability of partial denture during function and preserving the residual oral structures.

Keywords: Removable partial denture, Dual impression technique, Functional impression, Distal extension.

Introduction

A partial denture impression is defined as “A negative likeness of a part or all of a partially edentulous arch”. The critical need for finely detailed and meticulously accurate impressions in the practice of partial denture prosthodontics does not need elaboration. Unless the cast upon which the prosthesis is to be fabricated is an exact replica of the mouth, the prosthesis cannot be expected to fit properly, and, of course, an accurate cast can only be obtained from an accurate impression. The impression for a removable partial denture differs from one for a complete denture in important respects.

The complete denture impression records soft tissue only. The partial denture impression must accurately register the relatively soft, yielding tissue (the oral mucosa) at the same time that it records a hard unyielding substance (the remaining teeth). The procedure is further complicated by the fact that the hard structures are irregular in contour as well as varying in their vertical postures relative to the occlusal plane. Because of this bell-shaped contour and variance of vertical alignment of the teeth, the impression material must be capable of entering into intimate contact with each crown surface of each tooth, withstanding the momentary distortion which occurs as the impression is withdrawn, and then instantly springing back to its original form without rupture or distortion. This elastic rebound of the impression material is an essential physical property which ensures that the teeth on the master cast are precisely accurate reproductions in every detail of their counterparts in the mouth. A partial denture made to fit such an exact replica will also fit the mouth.^(1,2)

Concepts and Rationale

The intermediary attachment medium between the abutment tooth and the alveolar bone is the periodontal

ligament; between the denture base and the residual ridge is the alveolar mucosa or mucoperiosteum. There is an obvious resiliency differential between these attachment media, with the periodontal ligament being essentially non-resilient and the alveolar mucosa exhibiting varying degrees of resiliency. The resiliency of the tissue-fitting surface of the denture base ranges from 0.4 to 2.0 mm, compared with the resiliency of 0.1mm for healthy periodontal tissue. The problem of achieving successful function of an RPD then becomes one of equilibrating this resiliency differential between the relatively non-resilient periodontal ligament of the abutment tooth and the more resilient mucosa covering the residual ridge.⁽²⁾

The problem of an anatomic impression in a distal extension condition is that the Removable partial denture would have optimum occlusal contact in rest but on clenching or under mastication, the denture base sinks down along with the displaced mucosa, both reducing the efficiency of mastication and torquing the abutment. Moreover when occlusal forces are applied, the denture base behaves as a harmful lever that rotates with the abutment teeth as fulcrum and concentrates the occlusal forces on a small area on the distal end of the edentulous ridge where the denture base terminates. This area is subjected to rapid resorption due to overload.

The solution = A functional impression

The objective of any functional impression technique is to provide maximum support for the removable partial denture bases. This allows for the maintenance of occlusal contact between both natural and artificial dentition and, at the same time, minimum movement of the denture base, which would create leverage on the abutment teeth.⁽²⁻⁴⁾

Impression Materials

- **Rigid materials**
 - Plaster of Paris
 - Metallic oxide pastes
- **Thermoplastic materials**
 - Modeling plastic
 - Impression waxes and natural resins
- **Elastic materials**
 - Reversible hydrocolloids (agar-agar)
 - Irreversible hydrocolloids (alginate)
 - Polysulfide impression materials
 - Silicone impression materials
 - Polyethers

The anatomic impressions technique

One stage impression method that records the hard and soft tissues at rest. Select a suitable perforated impression tray that is large enough to provide a 5-7 mm border thickness of the impression material. Built up the palatal portion of the maxillary impression tray. Position the patient in an upright position, with the involved arch nearly parallel to the floor. The lingual flange of the mandibular tray may need to be lengthened with beeswax in the retromylohyoid area or to be extended posteriorly, but it rarely ever needs to be lengthened elsewhere. Beeswax may need to be added inside the distolingual flange to prevent the tissues of the floor of the mouth from rising inside the tray. Place the patient in an upright position, with the involved arch nearly parallel to the floor. When using alginate hydrocolloid, place the measured amount of water (at 70°F) in a clean, dry, rubber mixing bowl (600ml capacity). Add the correct measure of powder. Spatulate rapidly against the side of the bowl with a short, stiff spatula. The impression material is being mixed and the tray is being loaded.^(1,3,5)

Factors influencing support of the distal extension base

- Quality of soft tissue covering edentulous ridge,
- Type of bone in the denture-bearing area
- Design of the prosthesis
- Amount of tissue coverage of denture base
- Anatomy of the denture-bearing area
- Type and Accuracy of the Impression Registration
- Fit of denture base
- Total Occlusal Load Applied.^(1,2)

Physiologic Impression Techniques

- ✓ McLean's technique
- ✓ Hindel's technique
- ✓ Functional reline technique
- ✓ Fluid wax technique - Altered cast technique
- ✓ Selected pressure technique- Altered cast technique

McLEAN'S Physiologic Impression

The need for physiologic impressions was first proposed by McLean. He realized the need for recording the tissues of the residual ridge in a functional form while capturing the remaining teeth in the anatomic form. To accomplish their objectives, they constructed a custom tray on a diagnostic cast. Spacer is not adapted. A functional impression was made using custom tray and a suitable impression material. A hydrocolloid "over-impression" was then made while maintaining the functional impression in its intended position. The greatest weakness of the technique was that practitioners could not produce the same functional displacement generated by occlusal forces.^(1,2)

Disadvantages

- The bite force exerted by the patient cannot be controlled by the operator. The bite force need not be same as the masticatory force
- The pressure exerted while making the over-impression need not be the same as the bite force. Hence difference in displacement. The denture base thus formed has the configuration of the displaced tissue and hence does not seat well or adapt to normal undisplaced mucosa.⁽⁶⁻⁹⁾

Hindel's Method

In response to the shortcomings in McLean's technique, Hindel and others modified the impression procedure which recorded the tissues under rest. They also developed modified impression trays for the second impression procedure. These trays had large holes in their posterior segments. As a result, the operator could apply finger pressure to the functional impression as the hydrocolloid impression was being made. The finished impression was a reproduction of the anatomic surface of the ridge and the surfaces of the teeth. The two were related to each other, however, as if masticating forces were taking place on the denture base. Hindel's technique records the residual ridge in its normal or rest state, but is related to the anatomic structures like teeth in a functional form.^(2,3)

Disadvantages

- Finger pressure does not simulate masticatory load.

Functional Reline Method

It consists of adding a new surface to the intaglio of the denture base. The procedure may be accomplished before the insertion of the partial denture, or it may be done at a later date if the denture base no longer fits the ridge adequately. The partial denture is constructed on a cast made from a single impression, usually irreversible hydrocolloid. This is an anatomic impression, and no attempt is made to alter it or produce a functional impression of the edentulous ridge. To allow room for the impression material

between the denture base and the ridge, space must be provided (Soft metal spacer).

An impression is made with a free-flowing zinc oxide-eugenol paste or a light-bodied elastomers. If errors in occlusion are slight, the correction may be accomplished in the mouth. However, in a majority of cases, it will be necessary to remount the partial denture on an articulator to correct the occlusion.^(1-3,7)

Fluid Wax Functional Impression

The fluid wax impression may be used to make a reline impression for an existing partial denture or to correct the edentulous ridge portion of a master cast.

The objectives of the technique are to obtain maximum extension of the peripheral borders while not interfering with the function of movable border tissues, to record the stress-bearing areas of the ridge in their functional form, and to record non-pressure-bearing areas in their anatomic form.

The most frequently used fluid waxes are Iowa wax and Korrekta Wax No.4. The impression wax flows sluggishly, and a thin layer of wax will flow less readily than a thicker layer. 1-2 millimeters of relief. It must remain in place 5 to 7 minutes to allow the wax to flow and to prevent buildup of pressure under the tray with resulting distortion or displacement of the tissue. Water bath is maintained at or close to 54°C (125°F to 130°F), into which a container of the wax is placed. At this temperature the wax becomes fluid. The wax is painted onto the impression tray with a brush.^(2,7-9)

The borders must be short by 2mm of all movable tissues, because the fluid wax does not have sufficient strength to support itself beyond that distance. Inaccuracies will develop if the wax is extended beyond that length.⁽¹⁻⁴⁾

Disadvantage

1. Time consuming
2. Impression with increased tissue displacement if time period not followed.

Selected Pressure Impression

This technique attempts to direct more force to those position of the ridge able to absorb the stress without adverse response and to protect the areas of the ridge least able to absorb force.

Procedure: For the mandibular posterior ridge, the crest of the ridge is not considered to be a pressure-bearing area. So the undersurface of the tray is relieved down to the metal retention struts. Framework tried in patient's mouth and then seated on the cast. Outline of special tray is penciled on the cast. On the metal framework the acrylic resin impression tray is fabricated. The mandibular impression tray is selectively reduced at the ridge crest - provides additional room for impression material and minimizes tissue displacement. Holes are made on the tray

corresponding to the crest of residual ridge and retromolar pad to allow escape of excess impression material. Border molding of the impression tray is done. Borders of impression are shortened by 1 to 1.5 mm and the whole inside of the impression, with exception of buccal shelf region is relieved by 1mm. Modeling plastic is removed from holes in the tray. Final impression is made with zinc oxide eugenol impression paste.

Altered Cast Procedure

Distal extension partial dentures constructed on one piece casts made from irreversible hydrocolloid in a stock tray exhibit more movement of the bases than do those constructed by the altered-cast procedure

In the altered cast procedure, the denture framework is fabricated on a one-piece cast and used as the base for a relieved individual tray which is then used to make a second impression of the edentulous tissues. Since the metal framework can be stabilized on the teeth while the impression is made, the mucosal tissues are in as nearly a state of rest as possible. The second impression is used to alter the cast in order to reproduce in the new registration, the relationship between the edentulous and the dentulous regions. Then, the altered cast is used to form the basal surfaces of the denture bases.^(10,11)

Single Tray Dual Impression Technique

The anterior teeth on the diagnostic cast are blocked out with three to four layers of asbestos paper. The cold-curing resin is adapted on the diagnostic cast to form the custom tray. An opening has been made around the teeth in the resin custom tray. Serial perforations surrounding the teeth allow the impression material to be attached to the tray. The custom tray is seated in the patient's mouth and the accessibility of the teeth is noted.

The border of the tray has been molded to be in harmony with the movements of the surrounding tissues. A zinc oxide and eugenol impression is made of the residual ridges. The final impression of the residual ridges is completed. An occlusion rim is constructed on the resin tray containing the final impression of the residual ridges. The maxillary and mandibular occlusion rims are in contact at the vertical dimension of occlusion. The mandible is in centric relation. The anterior part of the maxillary occlusion rim has been removed so that the irreversible hydrocolloid can be inrced through the opening in the tray while the residual ridges arc resisting occlusal forces. Irreversible hydrocolloid impression material has been forced through the opening in the tray. The single-tray dual-material impression is completed (Fig. 1). A close-up view of the two materials just distal to the abutment tooth shows that the tissue is under occlusal load. The master cast has been recovered from the final impression.^(1,2)

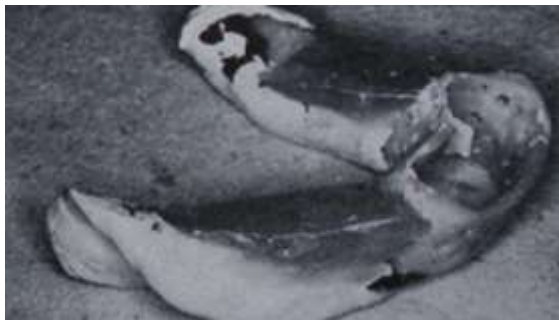

Fig. 1

Prefabricated Custom Impression Trays

Lund PS & Aquilino SA in 1991 stated that, removable partial prosthodontic treatment requires multiple patient appointments with intermediate laboratory steps. They described a technique that allowed the removable partial denture framework try-in and the impression for the altered cast to be efficiently completed in a single appointment. The method used prefabricated custom impression trays that are readily attached to the framework after the try-in (Fig. 2).⁽¹³⁾

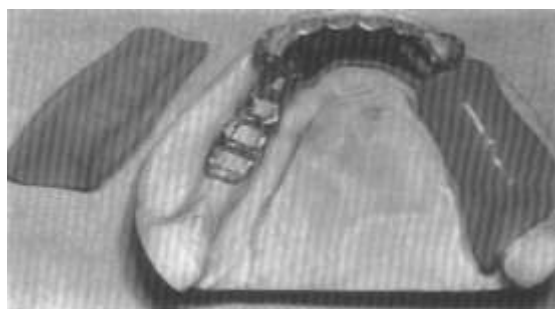


Fig. 2

Jaw Relationship and Impression in a Single Appointment

Santana-Penin U & Lozano JG in (1998) described a procedure for obtaining the inter jaw relationship and an accurate altered-cast impression in a single appointment (that of the framework try-in). Light-cured acrylic resin tray formed over edentulous ridge portion of framework. Holes are made in tray to allow resin columns to be built up through it. Position of holes can be marked with pencil so that it is clear where to locate bases of columns (arrows). Acrylic resin trays (with holes for resin columns) detached from framework. Framework in mouth showing 1 resin column built up as jaw relation index. Acrylic resin tray in position on framework after building up resin column that acts as jaw relation index (Fig. 3). In addition, stone index beneath major connector will facilitate accurate repositioning of framework on altered cast. Completed impression seated on cast from which edentulous ridges have been removed. Impression is boxed. Finished altered master cast, with impression and jaw relation

indexes in place (Fig. 4). Resin columns are used to relate mandibular cast to previously mounted maxillary cast, and are attached to lower arm of articulator with stone.⁽¹⁴⁾

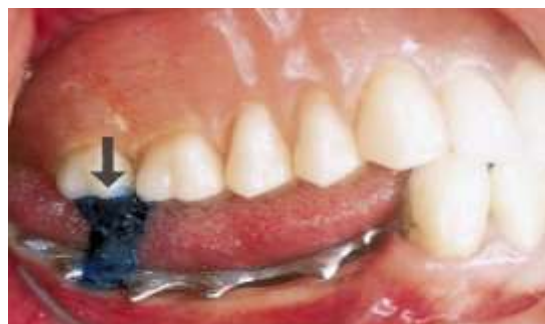

Fig. 3

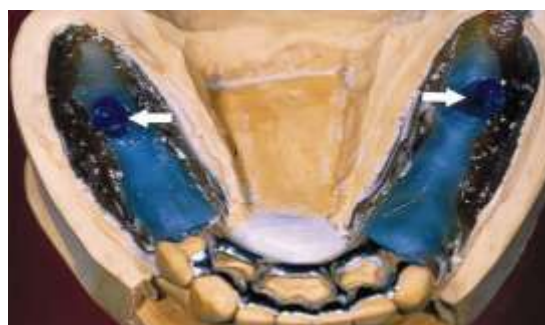

Fig. 4

Tissue Stops (in Vivo)

Wicks RA & Powell L (2000) stated that supplemental impression strategies may be used to capture optimal registration of residual ridge tissues in distal extension-base removable partial dentures. They described a procedure to adapt tissue stops in vivo and positively position the framework to the master cast when clinically using corrected impressions (Fig. 5). They concluded that this method was simple and cost-effective, and it promoted accurate prosthetic-tissue relationships during clinical and laboratory phase of removable partial denture fabrication. Curing material completed on intaglio surface of framework on removal from mouth. Visible space between tissue stop of framework and supporting tissues after framework was adjusted to fit teeth.^{+s¹}

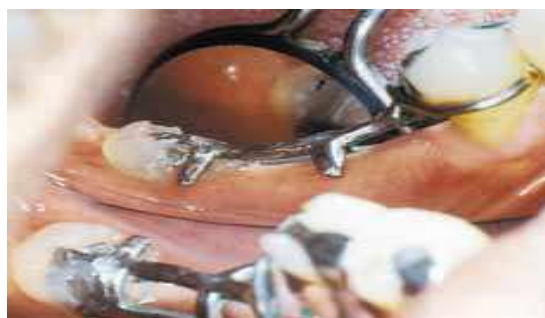

Fig. 5

Discussion

The method used to make impressions of the supporting and retaining anatomic structures of the mouth is of basic importance for obtaining optimum distribution of the masticatory load in the construction of removable partial dentures, especially of the lower extension saddle type. There are three definite requirements that must be fulfilled to assure proper load distribution in extension saddle partial dentures. These are:

1. The tissue surface of the saddle should be a negative reproduction of the anatomic, undistorted surface of the alveolar mucosa.
2. The masticatory load should be distributed between the ridge and the abutment teeth during function and cannot be left to be carried by the alveolar ridge alone.

The denture saddle should be related to the metal framework in such a way as to be similar to the relationship existing between the supporting teeth and the supporting mucosa when the latter is under a masticatory load.

A major factor to be considered in this regard is support for the partial denture. Because of the dual nature of the available support for the prosthesis, partial denture treatment presents an intriguing challenge to the dentist. If the support can be utilized in such a manner that neither the teeth nor the residual ridge is abused, the basis for a successful partial denture is established. However, if the supporting teeth or soft tissues are not used correctly and completely, subsequent mobility of abutment teeth and resorption of the residual ridge may be anticipated. A partial denture made from an impression which does not satisfy this requirement will be a failure regardless of how well designed and executed it might be.

Conclusion

A thorough understanding of the characteristics of each of the impression materials leads to the obvious conclusion that no single material can record both the anatomic form of the teeth and tissues in the dental arch and, at the same time, the functional form of the residual ridge. Therefore, some secondary impression method must be used.

This may be accomplished by several methods. Each seems to satisfy the two requirements for providing adequate support to the distal extension partial denture base, which are (1) that it records and relates the tissues under some loading and (2) that it distributes the load over as large an area as possible.

References

1. Alan B Carr, Glen P, David T Brown. Mc Cracken's Removable Partial Prosthodontics. 11th edition.
2. Kenneth Stewart, Kenneth Rudd. Clinical Removable Partial Prosthodontics. Second edition.

3. Renner R.P, "Periodontal considerations for the construction of removable partial dentures (I)" Quintessence Dent. Technol. (1985) 9,169-172.
4. Holmes J. B., "Influence of impression procedures and occlusal loading on partial denture movement" Journal of Prosthetic Dentistry (1965)15,474-481.
5. Rudd K.D., Morrow R.M., and Strunk R.R., "Accurate alginate impressions" Journal of Prosthetic Dentistry. (1969) 22, 294-300.
6. Chase W., "Adaptation of rubber-base impression materials to removable denture prosthetics" Journal of Prosthetic Dentistry (1960)10, 1043-1050.
7. Leupold RJ, Flinton RJ & Pfeifer DL, "Comparison of vertical movement occurring during loading of distal-extension removable partial denture bases made by three impression techniques" Journal of prosthetic Dentistry (1992) 68,290-293.
8. Leupold R.J, "A comparative study of impression procedures for distal extension removable partial dentures" Journal of Prosthetic Dentistry (1966) 16, 708-720.
9. Rudd RW & Rudd KD, "A review of 243 errors possible during the fabrication of a removable partial denture: part I, part II & part III" Journal of Prosthetic Dentistry (2001) 86,251-261,277-88.
10. Leupold RJ & Kratochvil FJ, "An altered-cast procedure to improve support for removable partial dentures" Journal of Prosthetic Dentistry (1965) 15, 672-678.
11. Frank RP, Brudvik JS & Noonan CJ, "Clinical outcome of the altered cast impression procedure compared with use of a one-piece cast" Journal of Prosthetic Dentistry (2004) 91,468-476.
12. J Rapuano JA, "Single tray dual impression technique for distal extension partial dentures" Journal of Prosthetic Dentistry (1970) 24, 41-46.
13. Lund PS, Aquilino SA, "Prefabricated custom impression trays for the altered cast technique" Journal of Prosthetic Dentistry (1991) 66,782-783.
14. Santana-Penin U & Lozano JG, "An accurate method for occlusal registration and altered-cast impression for removable partial dentures during the same visit as the framework try-in" Journal of Prosthetic Dentistry (1998) 80,615-618.
15. Wicks RA & Powell L, "Direct tissue stops for distal extension removable partial dentures" Journal of Prosthetic Dentistry (2000) 84,490-491.