

Mucocutaneous Angiomyolipoma of Premaxillary region Masquerading as Lipoma: a known but rare occurrence

Sunitha Shankaralingappa^{1,*}, Kataveeranahally Shekar Manjunath², Sneha Patil³

¹Consultant Pathologist, ³Junior Consultant, Dept. of Pathology, ²Consultant Radiologist, Dept. of Radiology, Columbia Asia Hospital, Hebbal, Bangalore

***Corresponding Author:**

Email: sunithakiran84@gmail.com

Abstract

Angiomyolipomas (AML) are distinctive benign mesenchymal tumors seen predominantly in the kidney. Majority (80%) of these tumors are sporadic, while remaining 20% of them are associated with tuberous sclerosis (TS). Extrarenal angiomyolipomas are extremely rare, liver being the commonest site followed by skin. Although rare, skin is the commonest reported site and literature search revealed cases of extrarenal angiomyolipomas arising at unusual locations like scrotal skin, vulva, colon and extrarenal peritoneum among others. We present a case of mucocutaneous angiomyolipoma located in left premaxillary region in a man aged 53years. Although head is the most commonly reported region for mucocutaneous AML, present case of premaxillary region angiomyolipoma presents as an intriguing mass in a region which is the best example for mucocutaneous site as the mass was located in-between skin and buccal mucosa. Lesion was excised and subsequent histopathological examination revealed the true nature of lesion. AML should be included in the differential diagnosis of premaxillary soft tissue masses.

Keywords: Angiomyolipoma, Tuberous sclerosis, Mucocutaneous angiomyolipoma, Premaxillary region.

Introduction

AML is a clinically benign, histologically complex mesenchymal tumor composed of triad of mature smooth muscle cells, fat cells and small to medium sized blood vessels in varied proportions.⁽¹⁾ Kidney is the most common site followed by liver.⁽²⁾ Around 80% of these tumors have been reported as sporadic, while rest 20% of them are associated with tuberous sclerosis.^(3,4) Extrarenal AML, though extremely rare, have been reported in skin (second most common site after liver), ovary, uterus, fallopian tubes, epididymis, spermatic cord, mediastinum, heart, oropharynx, nasal cavity, colon and other rare sites.^(3,5-8,9) Those located in skin and mucosa (oral, nasal, pharyngeal, vaginal etc.) are grouped together as mucocutaneous AML and have similar histomorphology irrespective of site of occurrence.⁽²⁾ Some authors have considered AML and angioleiomyomas with fat component as similar entities and there is still on-going debate on relationship between both. Mucocutaneous AML differ in many ways from renal AML, although there are many histomorphological similarities. Mucocutaneous AML are solitary, small, slow growing tumors. None of these tumors reported till date are associated with TS, unlike renal AMLs which are often associated with TS. In contrast to renal AML, they are negative for melanocytic immunohistochemical markers (HMB 45, MART 1).^(1,2,10) Review of literature clearly shows that these hamartomatous lesions are different from renal AML which are neoplastic in nature and are known for invasiveness and recurrence.^(1,10,11) We report a case in a 53 year old male with mucocutaneous AML in premaxillary soft tissue.

Case Presentation

A 53 year old man presented to ENT OPD of our hospital with a slow growing nodule present since 5 years over the left premaxillary region. The nodule was asymptomatic till recently when he noticed sudden increase in size. He was otherwise in good health and did not have any stigmata of tuberous sclerosis. He was not a diabetic or hypertensive. Physical examination revealed a blue subcutaneous nodule measuring 2.5x2cm, palpable from buccal mucosa as well. Clinical diagnosis of hemangioma was made.

PNS non contrast high resolution Computed Tomography demonstrated 35x15mm fat density lesion in left premaxillary region, suggestive of lipoma (Fig. 1).

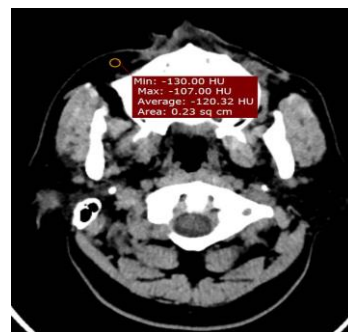

Fig. 1: Axial non contrast CT image demonstrating fat density lesion in right premaxillary region

The tumor was extirpated by simple resection. Post-operative period was uneventful without excessive bleeding. Patient was discharged on the third post-

operative day and there was no recurrence during 3 months follow-up period.

Pathological findings: Excised mass was sent for histopathological evaluation. Gross examination revealed a well circumscribed nodule measuring 2.5cm in greatest diameter with solid and hemorrhagic appearance on the cut surface. Haematoxylin and eosin stained sections showed a well-circumscribed, partially encapsulated tumor, clearly demarcated from the overlying skin and underlying buccal mucosa. The tumor was composed of mixture of mature blood vessels, muscle cells and fat cells. The vessels formed the major component and varied in shape and size from medium to large size. Some had thick hyalinised walls and others were ectatic and exhibited venous features (Fig. 2). Smooth muscle fibres surrounding the vessels extended longitudinally from the muscle wall and were arranged in layers of interconnected bundles. This feature was highlighted in Masson trichrome stain (Fig. 3). The mature fat cells were irregularly scattered throughout the tumor. In addition, aggregates of lymphocytes were noted. Neither epithelioid smooth muscle cells nor HMB 45 immunoreactivity was seen in the present case.

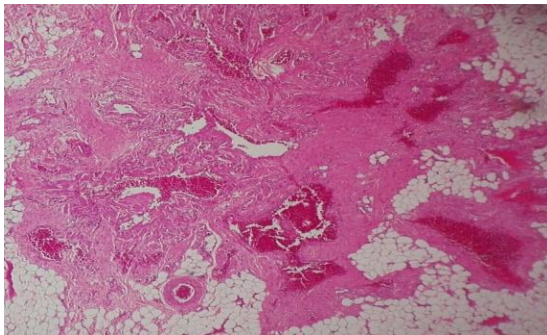


Fig. 2: Histomorphology of triphasic angiomyolipoma (10x, H&E stain)

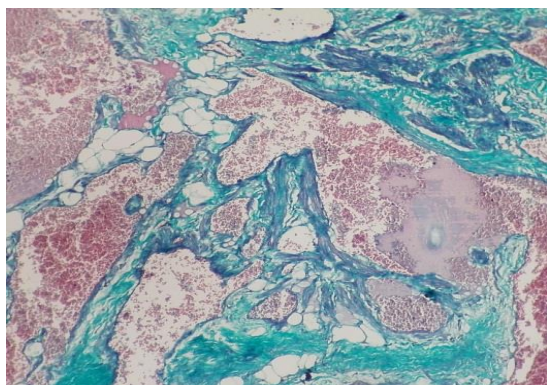


Fig. 3: Photomicrograph highlighting smooth muscle bundles arising from vessel wall (40x, Masson trichrome stain)

Discussion

Angiomyolipoma was first described by Morgan in kidney in 1951.⁽¹²⁾ It is a rare, benign complex

mesenchymal tumor of mixed mesenchymal origin arising commonly in kidney.⁽¹³⁾ It is intimately related to TS, with 80% of them associated with AML.⁽²⁾ Isolated AML are sporadic and account for 80% of the cases, while rest 20% are associated with TS.^(3,14) Liver and skin are the other commonest sites after kidney. Though extrarenal and in particular mucocutaneous AMLs are extremely rare, cases have been reported in the past, including the rarest case of scrotal skin AML.⁽³⁾

Renal AML was previously thought to be a hamartomatous lesion, now it is known to arise from perivascular epithelioid cells (PECs) and belong to family of tumors termed PECOMas.^(7,8) They are proved to be clonal neoplasms. Tuberous sclerosis complex (TSC) arises from inactivating mutations of either TSC1 (on chromosome 9q34.3) or TSC2 (on 16p13.3), which encode for tumor suppressors, hamartin and tuberin respectively. Allelic losses at 16p13, which carries TSC2 have been found in both sporadic AMLs and those associated with TS.^(3,15) The histogenesis of extrarenal and mucocutaneous AML is uncertain, probably hamartomatous in nature.

First report of cutaneous AML was presented by Fitzpatrick et al under the name cutaneous angioliipoleiomyoma. He reported 8 cases in the year 1990, all were acral in location with male to female ratio of 7:1. Patient's age ranged from 33 to 77 years.⁽¹⁶⁾ But a rare anterior abdominal wall AML was reported in a child aged 3 years by Anand. S Ammanagi et al.⁽¹⁰⁾

Literature search showed that all cases presented as solitary slow growing nodules, and were not associated with TS. They were asymptomatic or caused few symptoms. In one report of 2 cases of cutaneous AML, both the patients presented with change in size with ambient temperature changes and those with nasal cavity AML presented with symptoms of nasal obstruction/epistaxis.^(1,2) They predominated in middle aged men and head was the commonest site with preference for acral areas (ear, nose, elbow etc.).

Computed tomography and MRI have an important role in the preoperative diagnosis of AML. Fat component, present in majority of AMLs produces a distinctive pattern on CT scan. But fat poor variants might pose diagnostic challenges.^(17,18) However the present case had varying amount of fat, distributed over entire tumor and hence was diagnosed as lipoma on PNS CT.

Histologically, the tumor is composed of triad of smooth muscle, fat and blood vessels in variable proportion. Interconnected bundles of mature smooth muscle cells arising from blood vessel wall form the major component and do not show any pleomorphism or mitosis. In a case described by Rodriguez Fernandez et al,⁽¹⁹⁾ pleomorphism was seen which was interpreted as degenerative. In the present case, smooth muscle component is not very abundant, but they seem to arise from vessel wall as demonstrated by Masson trichrome

stain. Blood vessels vary in size from medium to large diameter. They usually show arterial characteristics, but may occasionally appear to exhibit venous features (as in the present case).⁽¹⁾

Mucocutaneous AML are in many ways distinct from their renal counterpart. They occur in older men, unlike renal AML which shows female predominance. Second, they are solitary, not associated with TS and seldom larger than 4cm, well circumscribed and can be easily resected. Whereas renal AML can attain larger sizes, usually invasive and can recur. Most importantly they lack melanocytic antigen marker (HMB45 & MART1) immunoreactivity and epithelioid smooth muscle cells. Lymphoid aggregates, uncommon in renal AML are frequently encountered in extrarenal AML (including the present case).^(1,2,10)

Although some authors consider angiomyolipomas as angioleiomyomas with fat component, both are clinically and histologically different entities.

Conclusion

Triphasic mucocutaneous angiomyolipomas are clearly different tumors with distinct clinical, histological and immunophenotyping features and are not related to tuberous sclerosis associated renal AML. Hence there is no necessity to rule out the presence of associated tuberous sclerosis in these cases. CT/MRI aids in the presurgical diagnosis of AML and should always be considered a differential diagnosis in all cases diagnosed as lipoma on CT and in premaxillary soft tissue lesions.

References

1. J. Sanchez-Estella, M.T. Bordel-Gomez and T. Zamora-Martinez, "Presentation of 2 New Cases of Cutaneous Angiomyolipomas and Literature Review" *Actas Dermosifiliogr* (2009) 100, 808-12.
2. Kazuo Watanabe, Toshimitsu Suzuki, "Mucocutaneous Angiomyolipoma: A Report of 2 Cases Arising in the Nasal Cavity" *Arch Pathol Lab Med* (1999) 123, 789-792.
3. Gauhar Sultan, Bilal Masood, Harris Qureshi, Muhammed Mubarak, "Aniomyolipoma of the scrotum: report of a rarely seen case and review of the literature" *Turk J Urol* (2017) 43(2).
4. Longue LG, Acker RE, Sienko AE, "Best cases from AFIP: Angiomyolipomas in tuberous sclerosis" *Radiographics* (2003) 23, 241-6.
5. Dawlatly EE, Anim JT, El-Hassan AY, "Angiomyolipoma of the nasal cavity" *J Laryngol Otol* (1988) 102,1156-8.
6. Gatalica Z, Lowry LD, Peterson RO, "Angiomyolipoma of the nasal cavity: Case report and review of the literature" *Head Neck* (1994) 16, 278-81.
7. Jayaprakash PG, Mathews S, Azariah MB, Babu G, "Pure epithelioid perivascular epithelioid cell tumor (epithelioid angiomyolipoma) of kidney: Case report and literature review" *J Cancer Res Ther* (2014) 10,404-6.
8. Martignoni G, Pea M, Reghellin D, Zamboni G, Bonetti F, "PEComas: The past, the present and the future" *Virchows Arch* (2008) 452,119-32.

9. Senthilkumar Perumal, Jeswanth Sathyasesan, Ravichandran Planiappan, "An unusual cause of lower gastrointestinal bleed: angiomyolipomas, in an unusual location of the colon" *International Surgery Journal* (2016) 3(4), 2277-79.
10. Anand S. Ammanagi, Vijay D. Dombale, Vishwanath V. Shindholimath, "Cutaneous angiomyolipoma" *Indian Dermatology Online Journal* (2012) 3(1), 40-41.
11. Jung-u Shin, Kyu-yeoop Lee, Mi Ryung Roh, "A case of a Cutaneous Angiomyolipoma" *Ann Dermatol* (2009) 21(2), 217-20.
12. Martignoni G, Pea M, Rigaud G, Manfrin E, Colato C, Zamboni G, et al, "Renal angiomyolipoma with epithelioid sarcomatous transformation and metastases: Demonstration of the same genetic defects in the primary and metastatic lesions" *Am J Surg Pathol* (2000) 24, 889-94.
13. Farrow GM, Harrison EG Jr, Utz DC, Jones DR, "Renal angiomyolipoma: a clinicopathologic study of 32 cases" *Cancer* (1968) 22, 564-70.
14. Monika Garg, Amrita Duhan, Smridhi Bindroo, Jasveen Kaur, NC Mahajan, "Isolated angiomyolipoma of vulva: A case report of an uncommon tumor at an uncommon site" *Journal of Cancer Research and therapeutics* (2015) 11(3), 645.
15. Rakowski SK, Winterkorn EB, Paul E, Steele DJ, Halpern EF, Thiek EA, "Renal manifestations of tuberous sclerosis complex: Incidence, prognosis and predictive factors" *Kidney Int* (2006) 70,1777-82.
16. Fitzpatrick JE, Mellette JR, Hwang RJ, Golitz LE, Zaim MT, Clemons D, "Cutaneous angioliopoleiomyoma" *J Am Acad Dermatol* (1990) 23, 1093-8.
17. Jeong CJ, Park BK, Park JJ, Kim CK, "Unenhanced CT and MRI parameters that can be used to reliably predict fat-invisible angiomyolipoma" *AJR Am J Roentgenol* (2016) 206, 304-7.
18. Schieda N, Hodgdon T, El-Khodary M, Flood TA, McInnes MD, "Unenhanced CT for the diagnosis of minimal-fat renal angiomyolipoma" *AJR Am J Roentgenol* (2014) 203,1236-41.
19. Rodriguez-Fernandez A, Caro-Mancilla A, "Cutaneous angiomyolipoma with pleomorphic changes" *J Am Acad Dermatol* (1993) 29, 115-6.