

CASE REPORT

Combined Inflammatory and Drug Induced Gingival Overgrowth in A Patient with Cardiovascular Disease. A Case Report

Dr. Nandini Manjunath¹,
Dr. Ria Susan George²,
Dr. Malav Sheth³

¹MDS, Professor & HOD,
^{2,3}Post Graduate Student,
Department of Periodontics & Implantology,
A. J. Institute of Dental Sciences,
NH – 66, Kuntikana, Mangalore, Karnataka - 575004

Corresponding Author

Dr. Ria Susan George
Email: george.susan.ria@gmail.com

Access this Article Online



Quick Response Code

www.idjsr.com

Use the QR Code scanner to access this article online in our database

Article Code: IDJSR 0130

Abstract

Oral mucosa is constantly subjected to external and internal stimuli and therefore manifests a spectrum of disease that range from developmental, reactive, and inflammatory to neoplastic. Etiology of gingival overgrowth is multifactorial and is frequently associated with inflammatory changes. Reactive lesions of the gingiva can occur in different forms which includes pyogenic granuloma, focal fibrous hyperplasia, peripheral giant cell granuloma and peripheral ossifying fibroma. The causative etiology of these lesions can be attributed to local irritants such as poor oral hygiene, plaque and calculus, overhanging margins, trauma, dental appliances and medication. This case report describes the management of gingival overgrowth in a hypertensive patient taking amlodipine. The treatment aspect included phase 1 therapy, substitution of the drug, surgical excision and maintenance and supportive therapy.

Keywords: Amlodipine, calcium channel blockers, gingival overgrowth

Introduction

Gingival overgrowth is one of the most important clinical features of gingival pathology. It has multifactorial etiologies and has been frequently associated with inflammatory changes in the gingiva¹. Drugs associated with gingival overgrowth can be broadly categorized into three major groups according to their therapeutic actions namely anticonvulsants, immunosuppressants and calcium channel blockers². Although the pharmacological effect of each of these drugs is different and directed toward primary target tissues, all of them seem to act similarly on a secondary target tissue, that is, the gingival connective tissue causing common clinical and histopathological findings¹. Prevalence of the drug induced gingival enlargement is 3-20% compared to most important inflammatory gingival enlargements³.

Amlodipine is a third generation dihydropyridine calcium channel blocker used in the management of both hypertension and angina and it is known to interfere with the production of collagenase through altered Ca influx into fibroblast which allows collagen accumulation without degradation. Ellis et al first reported gingival sequestration of amlodipine and amlodipine-induced gingival overgrowth in 3 adult dentate patients⁴.

Gingival Overgrowth has been reported in 15-83% of patients taking nifedipine^{5,6} approximately 21% of patients taking diltiazem⁷, about 4% of those medicated with verampil⁸ and 1.7% for amlodipine⁹. But in the present case, the gingival hyperplasia occurred at a dose of 10 mg/day within 6 months of use.

Case Presentation

A 65 year old male patient reported to Outpatient Department of Periodontology and Implantology at A. J. Institute of Dental Sciences, Mangalore, with chief complaint of pain and swelling in the upper front teeth region since 6 months and had difficulty while chewing food. Medical history revealed that patient was a known hypertensive and under medication, with amlodipine (10 mg/day orally), clopidogrel (75 mg/day) and atorvastatin (10 mg/day) since 6 months. Patient had a habit of ghutka and beetel nut chewing since 2 years and had clinical manifestation of oral submucous fibrosis.

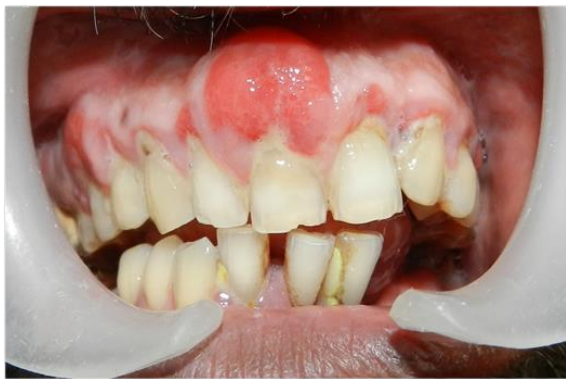

Figure 1: Showing generalized amlodipine-induced gingival enlargement

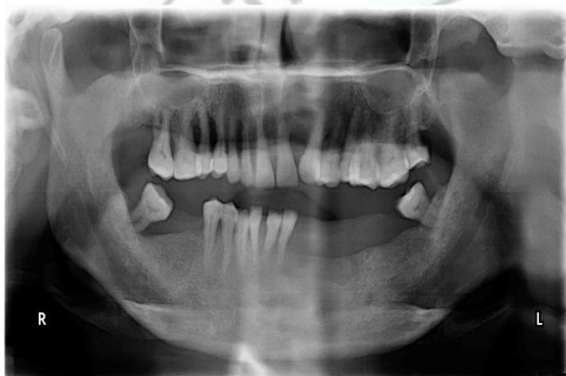

Figure 2: Orthopantomography revealed generalized bone loss.

Oral Examination

Periodontal health status was assessed through plaque index (PI), gingival index (GI) and probing pocket depth (PPD). It revealed the presence of supragingival & subgingival calculus on both anterior and posterior surfaces of the teeth. There was generalized bleeding on probing & average probing pocket depths of 4-8 mm. There was generalized gingival overgrowth on the labial and lingual/palatal surface of the maxillary & mandibular teeth, which was more pronounced in the labial aspect of the maxillary anterior and posterior teeth. Gingiva was highly vascular, reddish, erythematous with lobulated surface. Patient was sent for a complete blood hemogram which was normal. Patient was informed about the treatment protocol and a written consent was taken from the patient.

Histologic Examination

Biopsy was taken during the surgical phase and sent to the laboratory. The formalin fixed specimen was grossed, processed and embedded in paraffin wax and sectioning was done for the tissue blocks. The sections were stained with Hematoxylin and Eosin stains and viewed under light microscope. It revealed mixture of dense and loose fibrous components with the chronic

inflammatory cell infiltrate in the connective tissue and elongation of rete pegs in the epithelium. On the basis of patient's history, clinical features and biopsy reports, a diagnosis of amlodipine induced gingival overgrowth in a patient with hypertension was made.

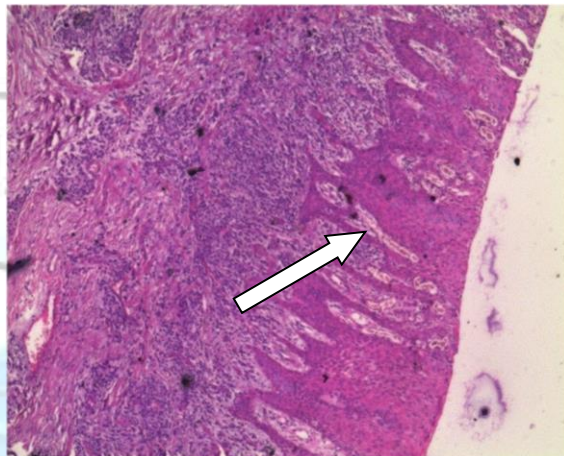


Figure 3: histologic view showing elongated rete pegs and dense connective tissue

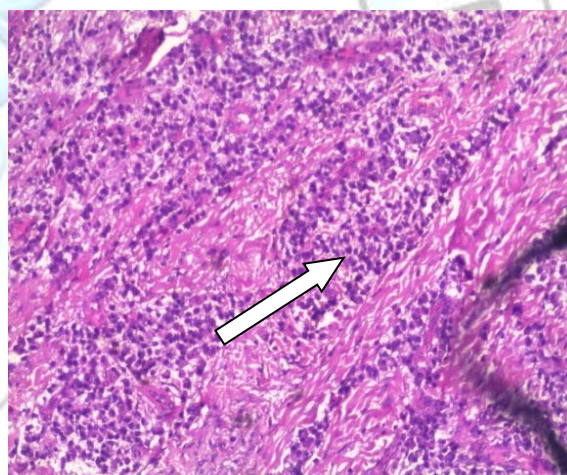


Figure 4: chronic inflammatory cell infiltrate in the connective tissue

Case Management

Drug Substitution

The patient was referred to a physician to replace the drug causing the adverse side effect.

Nonsurgical Treatment

Complete supragingival and subgingival scaling and oral hygiene instructions were given to the patient at the first visit and also habit counselling was carried out. Patient was referred for restorative therapy in relation to 11, which was hidden due to the enlargement.

Surgical Therapy

Surgical excision of gingival hyperplastic tissue was done employing the techniques of gingivectomy/gingivoplasty to restore the normal shape and contour of the gingiva. During the excision tissue appeared overtly inflamed which could be contributed to the

local factors. Postoperatively, there was successful elimination of enlarged gingival tissue and restoration of a physiological gingival contour. The desired result was not achieved as the patient failed to substitute the antihypertensive drug. Restorative therapy was also not undertaken by the patient.

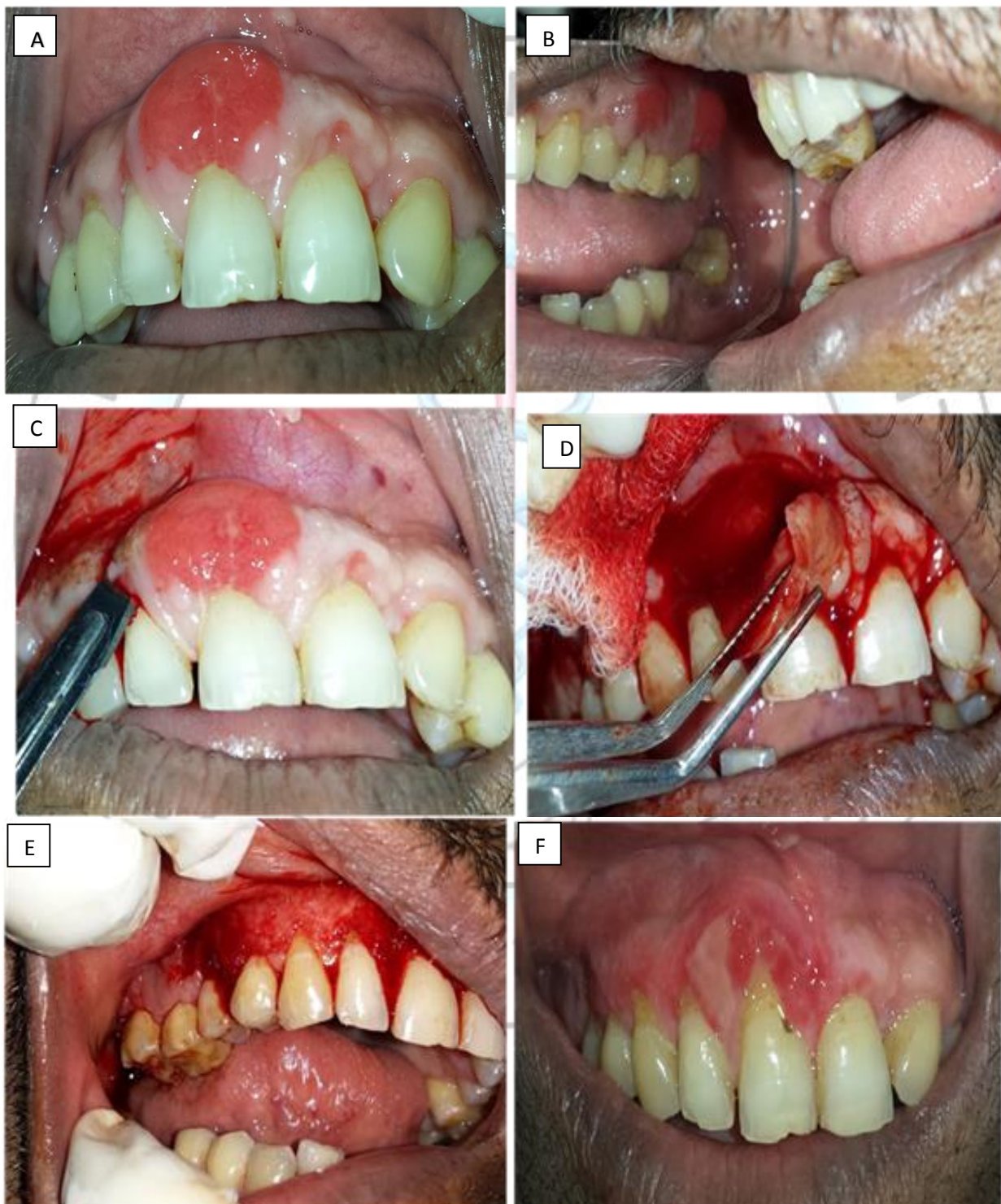

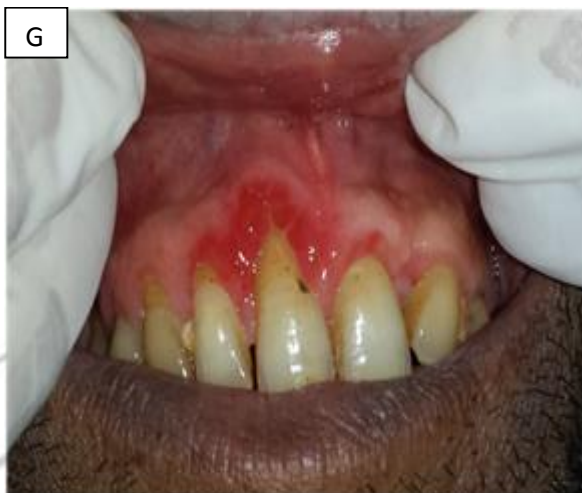


Fig. A and B: Labial aspects of maxillary anterior and posterior teeth after thorough scaling and root planning.
 Fig. C, D, E: Gingivectomy procedure for excision of gingival overgrowth using the No. 15 blade.
 Fig. F: One week post-operative. Fig. G: Two weeks post-operative.

Discussion

The pathogenesis of gingival overgrowth is uncertain and the treatment is still largely limited to the maintenance of an improved level of oral hygiene and surgical removal of the overgrown tissue⁴. Seymour et al¹¹ gave a review on the pathogenesis of drug-induced gingival overgrowth in which they considered it as a multifactorial model, involving an interaction of several factors, which expands on the interaction between drug and metabolite with the gingival fibroblasts. Predisposing factors for these changes are age, genetic predisposition, pharmacokinetic variables, drug-induced alterations in gingival connective tissue homeostasis, histopathology, ultrastructural factors and inflammatory changes, and drug-induced action on growth factors².

It has been found that phenytoin and calcium channel blockers inhibit the intracellular Ca²⁺ uptake thereby stimulating gingival fibroblasts. Not all the patients receiving the same drug develop gingival enlargement. Possible reason can be that individuals with gingival enlargement have fibroblasts with an abnormal susceptibility to the drug. It has also been proposed that susceptibility to pharmacologically induced gingival enlargement may be governed by existence of differential proportions of fibroblast subset in each individual which exhibit a fibrogenic response to these medications. It has also been shown that the functional heterogeneity exists in gingival fibroblasts in response to various stimuli¹². A synergistic enhancement of collagenous protein synthesis by human gingival fibroblasts is found when these cells are exposed simultaneously to calcium channel blockers and elevated levels of interleukin-1 β (a proinflammatory cytokine) in inflamed gingival tissues. Interleukin-6 also plays a role in fibrogenic responses of gingiva to these medications. Interleukin-

6 targets fibroblasts which trigger the proliferation of fibroblasts and exert the positive regulation on collagen and glycosaminoglycans synthesis. So this cytokine has been proposed to play a pathogenic role in fibrotic gingival enlargement¹¹.

In the present case 10mg/day dose of amlodipine along with poor oral hygiene status may have caused gingival hyperplasia in a 65 year old hypertensive patient. After two weeks postoperative the desired result was not met. The patient was non compliant with the treatment protocol as he had poor oral hygiene maintenance and also failed to substitute the drug and get his tooth restored. However, there was reduction in the size of gingiva, with inflammation restricted to marginal gingiva with mild lobulation suggesting drug interaction with the tissue.

Conclusion

Patient must be informed of the tendency and the importance of maintenance of the effective oral hygiene as key factors in preventing and managing gingival overgrowth associated with these drugs¹⁰. Supportive follow up is necessary in an effort to monitor his gingival/ periodontal status, to assess and reinforce oral hygiene and to periodically provide professional care thus prevent the recurrence of gingival overgrowth¹³.

References

1. M.G. Triveni, C Rudrakshi, D.S. Mehta. Amlodipine-induced gingival overgrowth, J Indian Soc Periodontal, 2009 Sep-Dec; 2013(3): 160-163
2. Sanjeev Joshi and Sucheta Bansal. A Rare Case Report of Amlodipine-Induced Gingival Enlargement and Review of Its Pathogenesis. Case Reports in Dentistry, Volume 2013

3. Mohan Kumar Pasupuleti, S.V.V.S. Musalaiah, M. Nagasree, Arvind Kumar P. Combination of inflammatory and amlodipine induced gingival overgrowth in a patient with cardiovascular disease. *Avicenna J Med.* 2013 Jul-Sep; 3(3): 68–72.
4. Ellis JS, Seymour RA, Thmason JM, Monkman SC, Idle JR. Gingival sequestration of amlodipine and amlodipine induced gingival overgrowth; *Lancet* 1993; 341:1102-3
5. Barak S, Engelberg IS, Hiss Z. Gingival hyperplasia caused by nifedipine: Histopathologic findings. *J Periodontol.* 1987; 58:639–42.
6. Fattore L, Stablein M, Bredfeldt G, Semla T, Moran M, Doherty-Greenberg JM. Gingival hyperplasia: A side effect of nifedipine and diltiazem. *Spec Care Dentist.* 1991; 11:107–9.
7. Steel RM, Schuna AA, Schreilber RT. Calcium antagonist-induced gingival hyperplasia. *Ann Intern Med.* 1994; 120:663–4.
8. Miller CS, Damm DD. Incidence of verapamil-induced gingival hyperplasia in a dental population. *J Periodontol.* 1992; 63:453–6.
9. Ellis JS, Seymour RA, Steele JG, Robertson P, Butler TJ, Thomason JM. Prevalence of gingival overgrowth induced by calcium channel blockers: A community-based study. *J Periodontol.* 1999;70:63–7.
10. Yogesh Upadhyay. Amlodipine-Induced Gingival Overgrowth: A Case Report. *Journal of Dental and Medical Sciences (JDMS)* Volume 3, Issue 4 (Jan-Feb. 2013).
11. R. A. Seymour, J. M. Thomason, and J. S. Ellis, "The pathogenesis of drug-induced gingival overgrowth," *Journal of Clinical Periodontology*, vol. 23, no. 3, pp. 165–175, 1996.
12. R. A. Seymour, "Calcium channel blockers and gingival overgrowth," *British Dental Journal*, vol. 170, no. 10, pp. 376–379, 1991.
13. Hallmon WM and Rossmann JA (1999). The role of drugs in the pathogenesis of gingival overgrowth. A collective review of current concept. *Perio 2000*, 21: 176-196.