

A Histological and Clinical Evaluation of Shallow and Deep Probing Depths

Siavash Hassanpour¹,
Shlomi Tamam²,
Timur Shigapov³,

¹H.BSc., M.Sc. DDS, Matrix Dynamics Group,
Faculty of Dentistry, University of Toronto, Canada

²H.BSc., M.Sc. DDS, East Village Dental Center,
Oshawa, Canada.


³H.BSc, DDS De Man and Hoediono Dentistry,
Kitchener, Canada

Corresponding Author

Siavash Hassanpour

Email: siavash.hassanpour@mail.utoronto.ca

Access this Article Online

	www.idjsr.com
	Use the QR Code scanner to access this article online in our database
	Article Code: IDJSR SE 0163

Quick Response Code

New and improved diagnostic aides are constantly being developed and deployed to improve our ability to correctly identify, diagnose and treat a variety of medical conditions. Despite several attempts at developing a new gold standard tool for the diagnosis of periodontal disease [1], dental professionals still largely, although not exclusively, rely on the periodontal probe and periodontal probing depth (PD) for the identification and classification of periodontal diseases. PD is commonly used to evaluate the presence or absence of periodontal disease, and PD values are relied on for the determination of periodontal disease severity[2,3]. To these authors' knowledge, no clinical study has conclusively defined the healthy PD. Generally speaking, in the absence of gingival recession or enlargement, shallow PDs of 1-3mm are considered to be indicative of a healthy or normal periodontal sulcus. Sites with PD values of 4-6mm are considered moderately deep and indicative of early stages of periodontal disease. Ultimately, sites with PD values greater than 7mm are considered as deep sites, typically caused by advanced periodontal disease. As such, clinicians view sites with progressively larger PDs with increasing concern. The aim of this short

commentary is to use evidence from histological and clinical studies to discuss the merits of considering a shallow probing depth as healthy and to highlight changes induced by periodontal disease that lead to deepening periodontal pockets.

PD is defined as the distance from the gingival margin to the deepest part of the probable crevice. Historically, the terms PD and pocket depth were used interchangeably. In 1971, Listgarten noted that PD measurements only offer an estimation of the true pocket depth, as the probe tip routinely goes beyond the sulcus and into the attachment apparatus of the tooth [4]. He further suggested that the only way to measure the depth of the anatomical sulcus, or pocket, is through histological means. One of the first studies to examine the physiological attachment around healthy human teeth was carried out in 1961 by Gargiulo et al. In this study, Gargiulo defined the dentogingival complex as the physiological and functional supporting tissue of teeth[5]. Measurements were made along 325 surfaces of presumably healthy teeth in human cadaver jaws. They concluded that the dentogingival junction is composed of the junctional epithelium (formerly the epithelial attachment) and the connective tissue fibrous attachment. In the study, Gargiulo measured the depth of the true gingival sulcus, the length of the junctional epithelium and the length of connective tissue attachment throughout various phases of passive eruption. The study found the average sulcus depth to be 0.69mm (range 0.61mm - 1.71mm). The average length of the junctional epithelium was 0.97mm (range 0.71mm - 1.35mm), while the average length of the connective tissue attachment was 1.07mm (range 1.03mm - 1.07mm) [5](Figure 1). As such, assuming a periodontal probe could precisely measure the depth of a healthy sulcus, we would expect to get measurements ranging from 0.61-1.71mm. However, the anatomic sulcus or pocket depth rarely corresponds to the clinical PD measurement. The periodontal probe routinely goes beyond the sulcus and penetrates the coronal part of the junctional epithelium [6]. Even in periodontal health and in absence of inflammation, the periodontal probe penetrates the junctional epithelium by 0.5mm, stopping 0.4mm coronal to the termination of the junctional epithelium [6]. This increases the expected PD in healthy tissues to 1.11-2.21mm (1.11mm = 0.61mm +0.5mm; 2.21mm = 1.71mm + 0.5mm). Also, seeing that probing depth

measurements are accurate to within 1mm 90% of the time [7], we can expect healthy probing depths to range between 0.11mm-3.21mm (0.11mm = 1.11mm - 1mm ; 3.21 mm = 2.21mm + 1mm) or simply up to 3mm(Figure 2A).

To understand why PD values increase with periodontal disease progression, one has to examine the pathophysiology of gingivitis and periodontitis. Gingivitis is defined by the presence of gingival inflammation without the loss of periodontal attachment [8]. Histologically, gingivitis is characterized by an increase in blood flow, an influx of inflammatory cells and breakdown of perivascular connective tissue (Figure 2B)[9]. All together, these changes lead to clinical features consisting of edematous, erythematous and friable gingival tissues that typically extend coronal to the cement enamel junction (CEJ) and readily bleed upon probing. Even without periodontal attachment loss, clinical PD values are increased in gingivitis when compared to clinically healthy sites. The increased PD during gingivitis is explained partly by the gingival enlargement and partly by increased penetration of the periodontal probe in inflamed tissues. Studies have shown that the tip of a periodontal probe penetrates the full length of the junctional epithelium, stopping 0.1mm to the apical termination of the junctional epithelium in an inflamed site[6], compared to 0.4mm in healthy periodontium as discussed above. Together, these two factors explain why increased PD values are often associated with gingivitis in the absence of concurrent loss of periodontal attachment or loss of alveolar bone.

Unlike gingivitis, periodontitis is characterized by the pathological loss of collagen fibers, apical migration of the junctional epithelium, loss of alveolar bone and periodontal attachment (Figure 2C). Histologic studies of the progression of periodontitis have shown that early periodontal lesions are initially localized to the gingival sulcus and later progress to the periodontium proper, the periodontal ligament, cementum and alveolar bone. Histological studies in more advanced periodontal disease have shown that during probing, the probe tip penetrates the full length of the junctional epithelium and extends deep into the connective tissue attachment[6,10], resulting in progressively increased probing depth proportional to the degree of attachment loss. For this reason, deep PDs are seen in tissues undergoing periodontal breakdown due to the concurrent apical migration of the junctional epithelium, the inflamed nature of the connective tissues and the loss of alveolar bone.

Clinical studies routinely classify pockets into three groups: 1-3mm, 4-6mm and 7mm and greater [11-13].The reason for this common classification system is twofold. Firstly, this classification system stratifies diseased sites and helps determine the aggressiveness of treatment including the need for surgical

periodontal therapy [14]. Secondly, the shallow, moderate and deep stratification system allows clinicians to determine the expected outcome of treatment. Clinicians are often less concerned with shallow pockets, as shallow pockets are more amendable to routine oral hygiene at home and are easier to maintain under professional care. Shallow pockets are more likely to be adequately cleansed by manual tooth brushing, which penetrate 0.9mm below the gingival margin [15]. Likewise, self-administered oral hygiene routines can remove interproximal plaque up to 2.5mm subgingivally [16]. Also, when receiving professional prophylaxis and scaling and root planning (SRP), Brayer et al. found that even inexperienced practitioners can adequately cleanse shallow pockets[17]. These shallow pockets are compatible with good health and function for many years [18]. While SRP is less efficient at removing the etiological agents that cause disease progression in deeper sites, it can effectively remove plaque and calculus up to 3.73mm subgingivally. Deeper pockets (> 5mm), however, are rarely free of plaque and calculus following SRP [19]. Longitudinal studies comparing surgical and non-surgical therapy have validated the need for surgical therapy when faced with deep(>7mm) PDs [13,20]. For pockets greater than or equal to 7mm, surgical periodontal intervention resulted in significantly greater reduction in probing depth than SRP alone. This can be attributed to increased access, direct visualization and correction of unfavorable osseous architecture during periodontal surgery. In 1982, Lindhe described the concept as the critical probing depth (CPD) [21]. CPD is defined as the threshold PD where gain of clinical attachment can be expected following treatment. Lindhe found that the CPD for SRP was 2.9mm, while the CPD of surgical therapy (Modified Widmann Flap) was 4.2mm. Together, these results indicate that shallow pockets < 3mm can be adequately maintained without further loss of attachment by scaling alone, while promoting the use of surgical therapy in sites with deeper initial PDs.

Periodontal probing is not a flawless diagnostic instrument and should not be used in isolation. A high PD value alone does not imply active disease nor disease progression[22]. Variations in PD can be introduced by probing force, probe angulation, probe thickness, probe type as well as tooth site and local anatomy [3]. Further, intra- and inter-clinician variability and reproducibility in PD have been reported [7,23]. In addition, the depth of probe penetration is directly proportional to the degree of inflammation [24-26]. In fact, rather than simply measuring PD, a better indicator of periodontal disease severity is clinical attachment level (CAL). CAL, which is calculated by summing PD and recession, more accurately estimates loss of periodontal attachment as a result of periodontal

disease [27]. Nonetheless, periodontal probing provides clinicians with a useful estimate of the location of the most coronal insertion of the intact connective tissue fibers and thereby verifying the presence or absence of periodontal disease.

Figure 1.

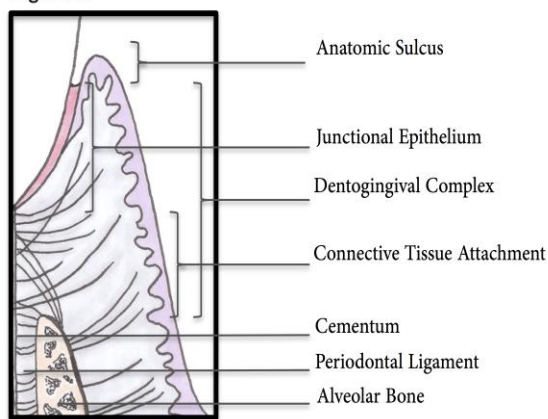


Figure 1. The Dentogingival Complex

The attachment apparatus of a tooth is comprised of the dentogingival complex and the periodontal ligament. The dentogingival complex is composed of the junctional epithelium and the connective tissue fibrous attachment. The average sulcus depth is 0.69mm (range 0.61mm - 1.71mm). The average length of the junctional epithelium is 0.97mm (range 0.71mm - 1.35mm) and the average length of the connective tissue attachment is 1.07mm (range 1.03mm - 1.07mm). Inspiration for image comes from the Color Atlas of Dental Medicine Periodontology, 3rd Edition, and was kindly illustrated by Ms. Gretchen Kramer.

Figure 2.

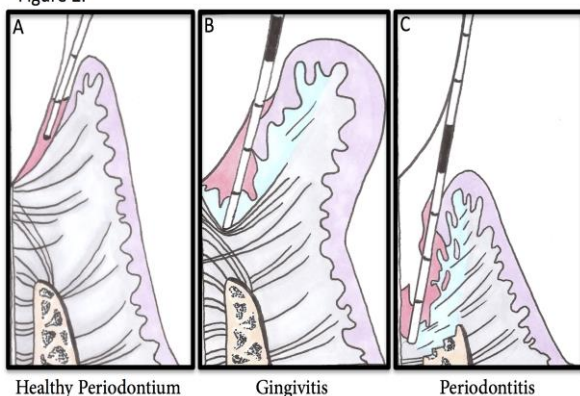


Figure 2. The Progression of Periodontal Disease

A) In periodontal health, the periodontal probe penetrates the entire length of the anatomical sulcus and half way through the junctional epithelium, resulting in probing depths of 1-3mm.

B) Histologically, gingivitis is characterized by an increase in blood flow, an influx of inflammatory cells and breakdown of perivascular connective tissue resulting in edematous, erythematous and friable gingival tissues.

Gingival enlargement in combination with increased periodontal probe penetration result in increased PD in tissues suffering from gingivitis. Typically, in tissues affected by gingivitis, the tip of a periodontal probe penetrates the full length of the junctional epithelium and enters the connective tissue attachment, resulting in probing depth of ≥ 4 mm.

C) Periodontitis is characterized by the pathological loss of collagen fibers, apical migration of the junctional epithelium, loss of alveolar bone and periodontal attachment. In advanced periodontal disease, the probe tip penetrates the full length of the junctional epithelium and extends deep into the connective tissue attachment; the more severe the periodontal attachment loss, the greater the corresponding probing depths. Inspiration for image comes from the Color Atlas of Dental Medicine Periodontology, 3rd Edition, and was kindly illustrated by Ms. Gretchen Kramer.

References

1. Wolf DL, Lamster IB. Contemporary concepts in the diagnosis of periodontal disease. *Dent Clin North Am* 2011;55:47-61.
2. Listgarten MA. A perspective on periodontal diagnosis. *J Clin Periodontol* 1986;13:175-81.
3. Listgarten MA. Periodontal probing: What does it mean? *J Clin Periodontol* 1980;7:165-76.
4. Listgarten MA. Normal development, structure, physiology and repair of gingival epithelium. *Oral Sci Rev* 1972;1:3-67.
5. Gargiulo AW, Wentz FM. Dimensions and relations of the dentogingival junction in humans. *Journal of Periodontology* 1961;32:261-7.
6. Armitage GC, Svanberg GK, Loe H. Microscopic evaluation of clinical measurements of connective tissue attachment levels. *J Clin Periodontol* 1977;4:173-90.
7. Advances in measurements of periodontal bone and attachment loss. 2000;17:56-72.
8. Theilade E, Wright WH, Jensen SB, Loe H. Experimental gingivitis in man. *J Periodontol Res* 1966;1:1-13.
9. Page RC, Schroeder HE. Pathogenesis of inflammatory periodontal disease. A summary of current work. *Lab Invest* 1976;34:235-49.
10. JF S, FG B. Probing of pockets related to the attachment level. *J Periodontol* 1976;47:281-6.
11. Hill RW, Ramfjord SP, Morrison EC, Appleberry EA, Caffesse RG, Kerry GJ, et al. Four types of periodontal treatment compared over two years. *J Periodontol* 1981;52:655-62.
12. Ramfjord SP, Morrison EC, Burgett FG, Nissle RR, Shick RA, Zann GJ, et al. Oral hygiene and maintenance of periodontal support. *J Periodontol* 1982;53:26-30.
13. Kaldahl WB, Kalkwarf KL, Patil KD, Molvar MP, Dyer JK. Long-term evaluation of periodontal therapy: I. Response to 4 therapeutic modalities. *J Periodontol* 1996;67:93-102.
14. Greenwell H, Stovsky DA, Bissada NF. Periodontics in general practice: perspectives on nonsurgical therapy. *J Am Dent Assoc* 1987;115:591-5.
15. Waerhaug J. Effect of Toothbrushing on Subgingival Plaque Formation. *J Periodontol* 1981;52:30-4.

16. Waerhaug J. The interdental brush and its place in operative and crown and bridge dentistry. *Journal of Oral Rehabilitation* 1976;3:107-13.
17. Brayer WK, Mellonig JT, Dunlap RM, Marinak KW, Carson RE. Scaling and root planing effectiveness: the effect of root surface access and operator experience. *J Periodontol* 1989;60:67-72.
18. Merchant AT, Oranbandid S, Jethwani M. Position paper: epidemiology of periodontal diseases. *J Periodontol* 2005;76:1406-19.
19. Stambaugh RV, Dragoo M, Smith DM, Carasali L. The limits of subgingival scaling. *The International Journal of Periodontics & Restorative Dentistry* 1981;1:30-41.
20. Becker W, Berg L, Becker BE. The long term evaluation of periodontal treatment and maintenance in 95 patients. *The International Journal of Periodontics & Restorative Dentistry* 1984;4:54-71.
21. Lindhe J, Socransky SS, Nyman S, Haffajee A, Westfelt E. "Critical probing depths" in periodontal therapy. *J Clin Periodontol* 1982;9:323-36.
22. Claffey N, Nylund K, Kiger R, Garrett S, Egelberg J. Diagnostic predictability of scores of plaque, bleeding, suppuration and probing depth for probing attachment loss. 3 1/2 years of observation following initial periodontal therapy. *J Clin Periodontol* 1990;17:108-14.
23. Isidor F, Karring T, Attström R. Reproducibility of pocket depth and attachment level measurements when using a flexible splint. *J Clin Periodontol* 1984;11:662-8.
24. Schroeder HE, Listgarten MA. Fine structure of the developing epithelial attachment of human teeth. *Monogr Dev Biol* 1971;2:1-134.
25. Spray JR, Garnick JJ, Doles LR, Klawitter JJ. Microscopic demonstration of the position of periodontal probes. *J Periodontol* 1978;49:148-52.
26. Caton J, Greenstein G. Depth of Periodontal Probe Penetration Related to Clinical and Histologic Signs of Gingival Inflammation*. *Journal of Periodontology* 1981.
27. Armitage GC. Position Paper: Diagnosis of Periodontal Diseases. *J Periodontol* 2003;74:1237-47.

