

## Bypassing a broken instrument in a severely curved root canal: A case report

Sourav Banerjee<sup>1\*</sup>, Rahul Sharma<sup>2</sup>, Pallavi Roy<sup>3</sup>

<sup>1</sup>CMD & Consultant Micro Endodontist, <sup>3</sup>Consultant Aesthetic Dentistry, Omkarananda Dental Care & Research, Jamshedpur, Jharkhand, <sup>2</sup>Senior Lecturer, Dept. of Prosthodontics & Implantology, Sharda University

**\*Corresponding Author:**

Email: doctor.souravbanerjee@gmail.com

### Abstract

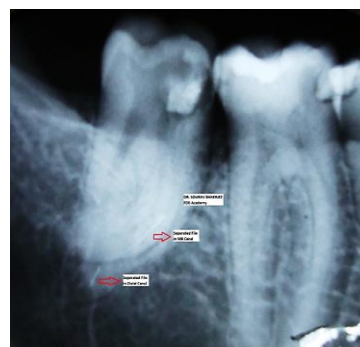
The curved root canals often pose utmost challenges in their endodontic management. Common mishaps in such cases are primarily related to iatrogenic errors such as ledge, fractured instruments, canal transportation, canal blockage, zip, elbow and perforation. Knowledge of dental anatomy and its variations is essential for the success of endodontic treatment more so in such difficult cases. A clinician is required to have a meticulous study of the pre-operative IOPAR and draw an insight of the morphology of coronal and radicular portions of the tooth related to its shape, form and structure before commencing treatment. This article gives a review of the literature and reports an interesting case of fractured instrument in a severely curved root canal where perhaps the complication could have been avoided if the need of a pre-operative IOPAR was duly addressed.

**Keywords:** Pre-curved files, Balanced force technique, Anti-curvature filing, Angle of Curvature by Schilder, Rotary safety, Bypassing, Retrieving

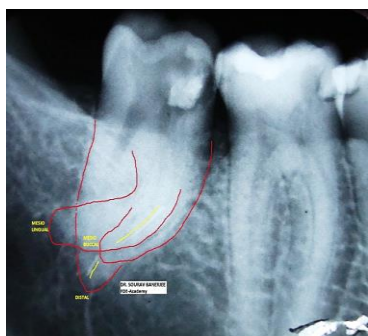
### Case Report

A 27-year-old male patient was referred to our practice. The patient had Symptomatic Apical Periodontitis on tooth #37. The referring dentist had attempted a root-canal treatment but had been unable to negotiate the curvature, about which he never knew as he skipped the pre-operative IOPAR, and broke a file instead. Subsequently under stress of apprehension and embarrassment he broke another file in a rather straight and wide canal. Before starting the treatment, a new diagnostic radiograph was taken [Fig. 1 (a)]. That revealed a fractured instrument in the curvature of one of the mesial canals and one in the distal root. An attempt was made to make the outline of the roots prominent by sketching them in red [Fig. 1(b)]. Since the roots presented with severe curvature it was decided to estimate the Angle of Curvature by Schilder's method.<sup>(1)</sup> The MB canal was estimated to have an angle of curvature of 50 degrees and the ML canal 75 degrees [Fig. 3(a) & (b)] respectively. The tooth was isolated with a rubber dam and the coronal temporary filling was removed. Straight-line access was established using GG drills and Orifice Shapers, as this is imperative to be able to reach and see the fractured instrument. In this case, in the MB canal the fractured instrument could not be visualized, because the coronal end of the instrument lay past the curvature and in the Distal canal it was decided not to attempt retrieval as the coronal end of the broken file was almost 21mm deep inside canal and an impending risk of either pushing the segment beyond the foramen and destroying the physiologic apex was apprehended [Fig. 1 (a)]. The decision was made to bypass both of the separated instrument segments rather than trying to retrieve. The key factors for this decision were the impossibility of visualizing the instruments and the location of the instruments. Bypassing was started by introducing a size 06.02 SS pre-curved K-file. After I got

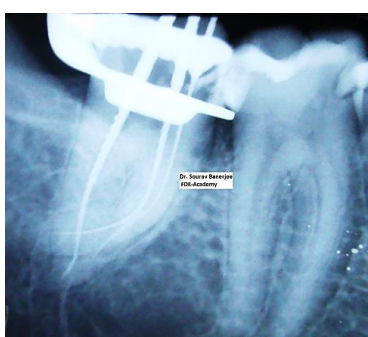
a tactile idea of 2 or 3 mm of the tip of the 06.02 K-file engaging between the broken file and the root dentine I withdrew it and repeated the process with a 08.02 SS pre-curve K-file, this could negotiate deeper and with 7 to 8 attempts past the broken segment. The 08.02 SS K-file was taken to about 2mm short of the radiographic apex. The procedure was repeated with 10.02 SS K-file and a customized 12.02 K-file (made by cutting off the tip of a 10.02 K-file by 1mm). The intermediate size made the sequential negotiation and glide path widening by reducing the percentage jump in size to 20% instead of 50% (seen when the jump in size is from 10.02 to 15.02). Finally a 15.02 SS K-file was pre-bent and inserted in the canal and with a number of careful Balanced Force motion could negotiate up to 2mm short of the radiographic apex. The entire glide path was prepared in a hybrid fashion mixing hand and rotary systems as and when needed, the sole idea was to incur minimum jump between sizes.<sup>(2)</sup> At this point without withdrawing the file estimation of WL electronically was done with Propex II and confirmed radiographically (Fig. 2). The complete shaping sequence of the first appointment is shown in Table 1.



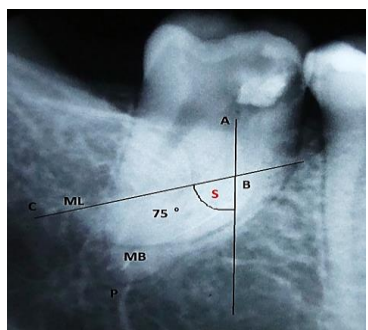
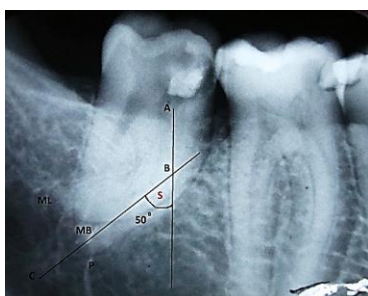
a



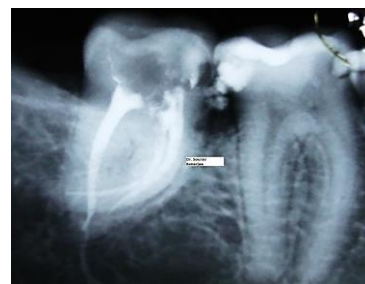
**Fig. 1a, b:** Preoperative radiograph showing the separated fragments(a) & dilacerated canal(b) in relation to #37



**Fig. 2:** Working length radiograph along with bypassed segments



**Fig. 3a, b:** Estimation of Angle of Curvature by Schilder's method



**Fig. 4:** Post obturation radiograph

**Table 1: First Appointment Canal Instrumentation**

First Appointment
SS K-FILE 06.02
SS K-FILE 08.02
SS K-FILE 10.02
SS K-FILE 12.02
PATHFILE 13.02
SS K-FILE 15.02
PATHFILE 16.02
PATHFILE 19.02
SS K-FILE 20.02
GG DRILL #2 , #1
Profile Orifice Shapers #5, #4, #3, #2, #1 in the Coronal 3 <sup>rd</sup>

**Table 2: Second Appointment Canal Instrumentation**

Second Appointment
Profile #35.06, #30.06, #25.06, #20.06, #15.06 in the middle 3 <sup>rd</sup>
Profile #15.04, #20.04, #25.04, #30.04, #35.04 for Apical 3 <sup>rd</sup> Preparation

**Table 3: Canal Dimensions**

Canal Dimensions		
Canal	Length in MM	Final Apical Size
MB	21.5	30.04
ML	22.5	35.04
D	23.0	35.04

During the shaping of the canal, copious irrigation with 5% sodium hypochlorite was performed with side vented irrigation needle from Ident In. Patency was kept with a size 08.02 K-file between every instrument. After the canal had been shaped using a size 20.02 K-file, calcium hydroxide was placed in the canal and the cavity was sealed with Cavit G under glass ionomer cement restoration. The patient returned for the 2<sup>nd</sup> appointment after 2 weeks. The glass ionomer was removed with round diamond and the Cavit G with ultrasonic. The calcium-hydroxide paste was removed using 17% EDTA and passive ultrasonic irrigation with an Irrisafe tip (Satelec). Further cleaning and shaping of the canal was performed with ProFile Rotary System (Densply Mallifer) along with copious irrigation using 5% sodium

hypochlorite with 30 G side vented irrigation needle (Ident In). The complete shaping sequence of the second appointment is shown in Table 2. The apical third of the canals were shaped using 4% tapered files and satisfactory apical sizes could be reached (Table 3). The canals were again packed with calcium hydroxide and a temporary restoration of Cavit G under glass ionomer cement was placed.

The patient was recalled for a 3<sup>rd</sup> and final appointment following 10 days from the 2<sup>nd</sup> one. Following the removal of GIC with a round diamond and the Cavit G was removed with ultrasonic. The canal was flushed with 5% Sodium Hypochlorite and PUI with Irrisafe tip for 30 sec in the distal canal and MDA with master cone in mesial canals, following which Smear layer removal was performed with a rinse of Smear Clear (Kavo Kerr) accompanied with cone pumping agitation in the mesial canals and ultrasonic agitation with Irrisafe tips in the distal canal. A wash of the canal was carried out with sterile saline, aspiration with micro canula and dried with paper points. The canal was then finally soaked in 2% CHX for 10min and was again dried following the previous protocol. 04 tapered ISO gutta-percha cone was fitted into the canals to check the cone fit. The mesial canals were obturated with warm lateral condensation using ISO size 20.04 cones as accessory cones. The distal canal was obturated with CWC and two cone back fill technique. Buchanan Pluggers (Sybron Endo) along with Touch N Heat Obturation Unit (Sybron Endo) were the instruments used. After Obturation the cavity was cleaned with Hydrol (Septodont) and a bulk fill core was placed over a layer of flow able composite at the orifice level to assure the coronal seal. Final post-operative radiographs were taken (Figs. 4). The prognosis of this case was excellent and the patient was referred to the referring dentist for a definitive coronal restoration.

## Discussion

Finding a completely straight root canal is rather an exception than a rarity. In endodontics we have to be always prepared to deal with different types and degree of curvatures<sup>(3)</sup> in the root canal system. These varied curvatures makes the adequate cleaning and shaping a more challenging task to accomplish. The Biologic requirement of Endodontic therapy will be attained only when a thorough dedebriment of the entire root canal system could be achieved.

Root canals may present with just an apical “J” curve, smooth curvature “C” form orifice to apex, severe/moderate curve, double/bayonet curve and abrupt/dilacerated curve. Curved root canals pose great difficulty in cleaning and shaping and subsequent obturation of the root canal system. The instrumentation of such curved anatomies requires flexible instruments and employment of safe techniques of instrumentation that achieves the biologic and mechanical aspects of endodontic therapy. Iatrogenic errors such as ledge

formation, blockage of canal, perforation and transportation are undesirable occurrences that have been observed after the preparation of curved root canals especially with the stiffer instruments and jumping sizes. Hence to determine the degree of curvature of root canal before starting the endodontic treatment is prudent.

Angle of Curvature as proposed by Prof. Schilder was applied here to estimate the curvature. The method to calculate the curvature based on the angle that is obtained by the intersection of two straight lines one that begins at the orifice and the other from the radiographic apex. The FIRST line is drawn from a point at the orifice marked A, [Fig. 3(a)(b)] through the coronal portion of the canal till the beginning of the curvature marked B, [Fig. 3(a)(b)]. The SECOND line is drawn from a point at the radiographic apex marked C, [Fig. 3(a)(b)] and intersects the point B. The internal angle “S” [Fig. 3(a)(b)] formed at point B is considered the Angle of Curvature of the Canal. Accordingly, the degree of root canal curvature is categorized as:

Straight: 5° or less

Moderate: 10-20° and

Severe: 25-75°.

In the above case presentation the curvature of the MB and ML canals falls in the category of “Severe” and was accordingly dealt with. Determining the curvature of the root canals will permit to strategize the treatment method and hence would aid in preventing the undesirable transportation of the canal. The customized and hybrid instrumentation technique would also prevent the undue stress on the instruments while they work in the canal and ultimately would prevent their failure. Thus, diagnosis of root curvatures before endodontic treatment has a profound importance in preventing complications during treatment and ensuring a good prognosis.

Case Difficulty Assessment, Planning and Strategizing is of critical importance while dealing with severe curvatures in endodontic treatment.<sup>(4)</sup> The curvatures that seems on the peri-apical radiograph poses a two dimensional picture that depicts the curves that happens only in the mesio-distal plane. Howsoever, evidence has shown that curves are multi-planar in reality. These anatomical facts suggest that a clinician reads the diagnostic radiograph meticulously and draw a detailed treatment approach astutely. The SS files have the tendency to straighten up in the canal, and hence it is difficult to control the action and subsequent removal of dentine along the entire length of the instrument with push pull motion. The risk of iatrogenic mishaps could be reduced by two ways:

One, by reducing the inherent force in a straight file that intends to straighten it up when it is introduced in a curved canal, and; Two by shortening the active length of the file that’s cutting at a given point of time.

### Reducing the inherent force in a straight file can be achieved by:

- A. Pre-curving the file: A pre-curved file negotiates the curve better than a straight file. Pre-curving could be sharp or gradual that most nearly conforms to the curving pattern of the canal.
- B. Use of flexible files as NiTi hand files for better execution of Balanced Force Technique.

More use of smaller ISO tip size files as they can follow canal curvature, owing to their inherent flexibility. The smaller size files should be made “super loose” in the canal before using larger files to negotiate the canal. It is wise to widen the glide path to a 20.02 ISO file before proceeding with rotary files, this may add to “rotary safety”.

Customizing and hybridizing: Shift from a 10.02 file to a 15.02 file is a straight way jump of 50%, hence the difficulty in negotiation<sup>(5)</sup> and sudden feel of increased stiffness. This could be either solved by cutting the 10.02 file by 1mm at the tip or by using P1 Pathfile that has a 13.02 tip size. Even though the P1 file is a rotary variant it could be manually manipulated when needed. This allows smoother transition of the instrument sizes to cause smoother cutting in curved canals, like cutting 1 mm of No. 15 file makes it No. 17 file or using the P2 pathfile as there is an increase of 0.02 mm of diameter per mm of length. A suggestive sequence for smooth transition could be 06.02-08.02-10.02-P1(13.02)-15.02-P2(17.02)-P3(19.02)-20.02 (Table 1).

### Shortening the active length of the file could be achieved by:

- A. Gaining the Straight Line Access: As soon as creating the glide path up to 10.02 file size its prudent to gain the straight line access until the beginning of the canal curvature. This would prevent the bending of the file against the canal wall and inflict undesirable cutting and also prevent failure of the file under torsion by taper lock
- B. Anti-curvature Filing: Modifying<sup>(6)</sup> the cutting edges of the instrument by dulling the flute on outer surface of apical third and inner portion of middle third, with a diamond file, this prevents the cutting towards the furcation and also straightens the canal and prevent the risk of strip perforation.

In narrow canals there was difficulty with irrigation and chances of debris to be pushed further apically which was undesirable and quite frequently appreciated as one of the major cause of inter-appointment flare ups. Subsequently to overcome these difficulties and to reduce iatrogenic mishaps<sup>(7)</sup> instrumentation techniques were developed that created flared preparation, as suggested in envelop of motion by Schilder. A major breakthrough in root canal instrumentation with hand files happened with the introduction of the balanced force movement of the files. The balanced force technique<sup>(8)</sup> has lesser tendency to cause iatrogenic damage such as ledging and transportation, decreases the

extrusion of debris apically and has better canal centering ability.

### Conclusion

Following the basic protocol saves the clinician from unnecessary hassle and stress, here a pre-operative IOPAR could have saved a lot of time both on the part of the referring dentist and of the patient. Also sometimes removal of a fractured instrument is impossible or undesirable. In these cases, bypassing the instrument is a valid alternative, which can lead to a favorable outcome as presented in this case. Lastly, strategizing and implementing a stress free instrumentation technique is of outmost importance.

### Reference

1. Estrela C, Bueno MR, Sousa-Neto MD, Pecora JD. Method for Determination of Root Curvature Radius Using Cone-Beam Computed Tomography Images. *Braz Dent J* 2008;19(2):114-18.
2. Jain N, Tushar S. Curved canals: ancestral files revisited. *Indian J Dent Res.* 2008;19:267-71.
3. Ansari I, Maria R. Managing curved canals. *Contemp Clin Dent.* 2012;3(2):237-41.
4. Gupta S. Endodontic Miscellany: Conventional Endodontics for Complex root-canal morphology. *Endodontology.* 2002;14(1):28-9.
5. Curtis ML. 100's of Pearls on Endodontics. Chapter 5: Tips and Tricks for Common Endo. *Hundreds of Pearls, LLC; Michael L. Curtis, Publisher.* 2005;93-5.
6. Mounce R. Negotiating challenging mid root curvatures: rounding the bend. *Dentistry Today.* 2007;26(2):108.
7. Schneider SW. A comparison of canal preparations in straight and curved root canals. *Oral Surg Oral Med Oral Pathol.* 1971;32:271-75.
8. Ingle JI. Root canal preparation. In: *PDQ Endodontics.* BC Decker, Hamilton, Ontario: 2005;129.