

A case report of TMJ closed lock reduced with occlusal splint therapy with MRI evidence

Shruti Sambyal^{1,*}, Ajit D. Dinkar², Bhanu Pratap Singh³, Atul Chauhan⁴

¹Lecturer, ²Professor & HOD, ⁴Assistant Professor, Dept. of Oral Medicine & Radiology, ³Assistant Professor, Dept. of Conservative Dentistry & Endodontics, H.P. Govt. Dental College & Hospital, Shimla

***Corresponding Author:**

Email: drshrutisambyal@gmail.com

Abstract

Introduction: Symptomatic cases of TMJ internal derangement can be associated with significant morbidity causing severe pain and limitation in functioning. Painful clicking or locking should be treated initially and at the earliest with conservative therapy including manual manipulation, anti-inflammatory drugs and oral appliances.

Clinical Presentation: A 24 year old female patient with pain in temporomandibular joint (TMJ) region and discomfort while mouth opening, was diagnosed with internal derangement of TMJ disc. A pre-treatment MRI revealed non-reducing disc displacement of the right TMJ and reducing disc displacement of the left TMJ. After four months of stabilization splint therapy her symptoms subsided and a post-treatment MRI taken a year later revealed reducing disc displacement bilaterally.

Conclusion: This case report potentiates the practice of employing occlusal splints for initial non-surgical management of TMJ internal derangement with MRI evidence.

Keywords: Temporomandibular joint, Non-reducing internal derangement, Stabilization splint, MRI

Introduction

Symptomatic cases of TMJ internal derangement can be associated with significant morbidity causing severe pain and limitation in functioning. Most symptoms associated with disc displacement resolve over time without treatment, but painful clicking or locking should be treated initially and at the earliest with conservative therapy including manual manipulation, anti-inflammatory drugs and oral appliances.⁽¹⁾ This case report presents successful management of non-reducing TMJ disc displacement with stabilization splint and a post treatment MRI showing disc reduction.

Case Report

A 24 year old female patient reported to the department with a chief complaint of pain (VAS 8) in front of the ears with severe discomfort while mouth opening since 1 week. Since past 7 months she had been experiencing clicking noise and pain in her right temporomandibular joint (TMJ). The noise ceased to occur 2 weeks previously and since then she noted significant reduction in mouth opening. She also mentioned locking of jaws 3 times previously which resolved without an active intervention. Patient reported no history of emotional distress or parafunctional behaviours.

Physical examination revealed no obvious extraoral swelling, facial asymmetry or occlusal discrepancies. Bilateral TMJ, masseter and temporalis muscles were tender on palpation. The maximum pain free mouth opening was 25mm. Passive mouth opening revealed a "hard end" feel and lateral excursions of mandible were painful too. Based on history and clinical evaluation a

provisional diagnosis of internal derangement of TMJ disc with Myalgia was given and patient was advised conservative management and medications including anti-inflammatory and muscle relaxants to relieve the acute symptoms of pain. Manual jaw manipulation increased the maximum mouth opening to 40mm. The patient reported back in a week with reduced pain (VAS 5) but with only mild improvement in jaw functions.

An MRI of bilateral TMJ revealed a non-reducing anterior disc displacement in the right TMJ and a reducing anterior disc displacement in the left joint (Fig. 1-3). After a thorough dental prophylaxis a maxillary stabilization splint was constructed. The centric relation was established by bilateral mandibular manipulation. Maxillary stabilization splint was constructed with an occlusal relief with uniform contact of functional cusp tips and incisal edges of mandibular arch. Canine-protected guidance was given for disclusion in eccentric movements. The patient was advised to wear the appliance only at night time for a maximum of four to six months or until symptoms of pain, jaw clicking and/or locking subsides. Initially patient reported back with mild accentuation of symptoms which got relieved in few days after occlusal readjustment of the appliance. There after the patient regularly reported to the department with significant improvement at each visit. After four months of appliance therapy the patient was advised to discontinue its wear. Patient was followed up for a year during which she remained asymptomatic. A post-treatment MRI after a year revealed reducing disc displacement bilaterally (Fig. 4-6).

Pre-Treatment TMJ MRI

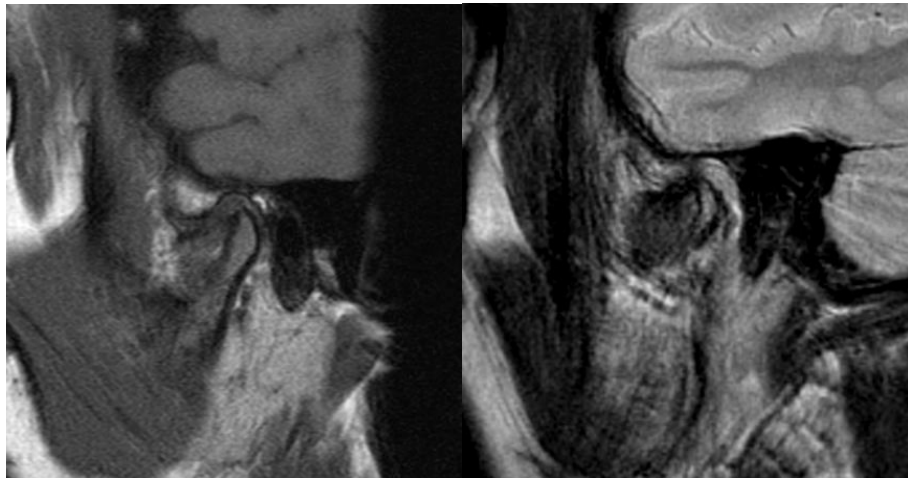


Fig. 1: Pre-Treatment Sagittal T1 (a) and T2 (b) Weighted MRI of Right Temporomandibular Joint (TMJ) in closed mouth position show a partial anterior disc displacement

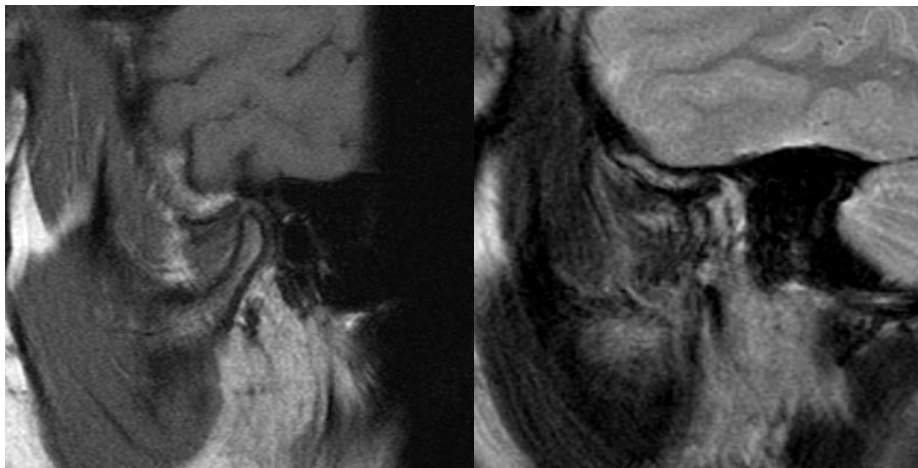


Fig. 2: Pre-Treatment Sagittal T1 (a) and T2 (b) Weighted MRI of left TMJ in closed mouth position show a partial anterior disc displacement

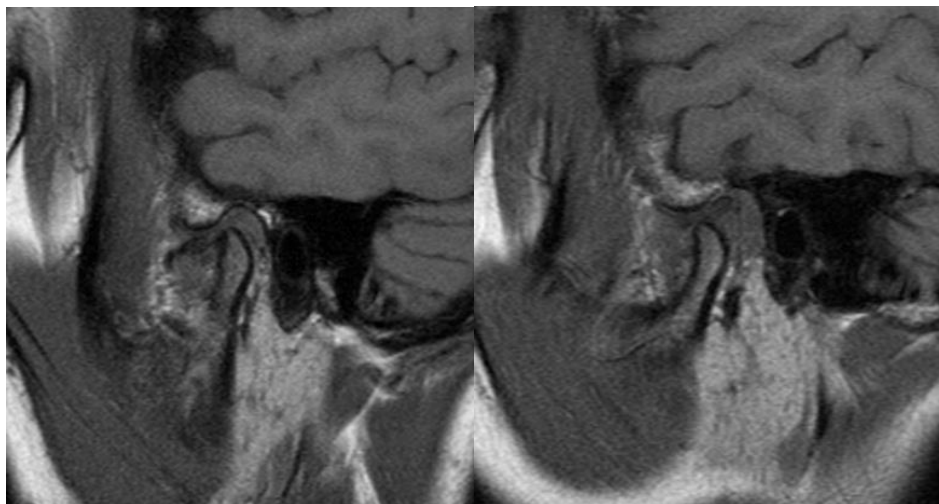


Fig. 3: Pre-Treatment Sagittal T1 Weighted MRI in open mouth position show a non reducing disc displacement of right TMJ (a) and reducing disc displacement of left TMJ (b)

Post-Treatment MRI – Sagittal Sections

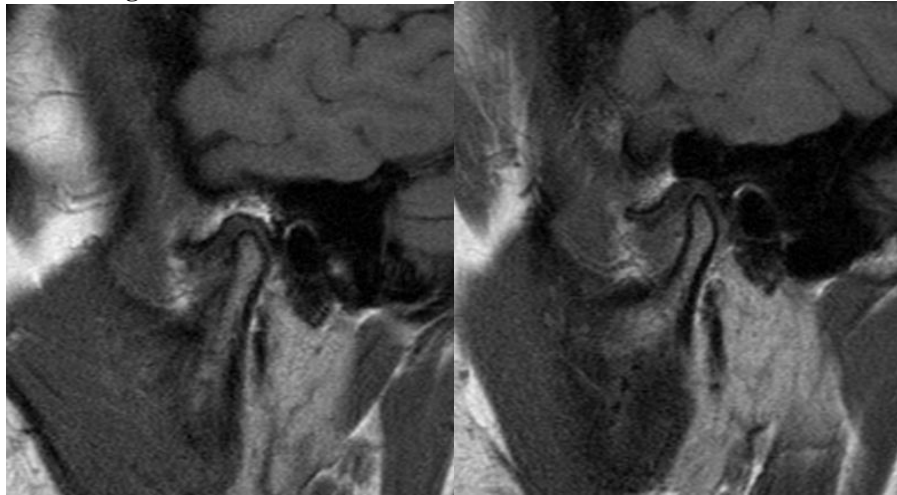


Fig. 4: Post-Treatment Sagittal T1 Weighted MRI in closed mouth position shows right (a) and left (b) TMJ anterior disc displacement

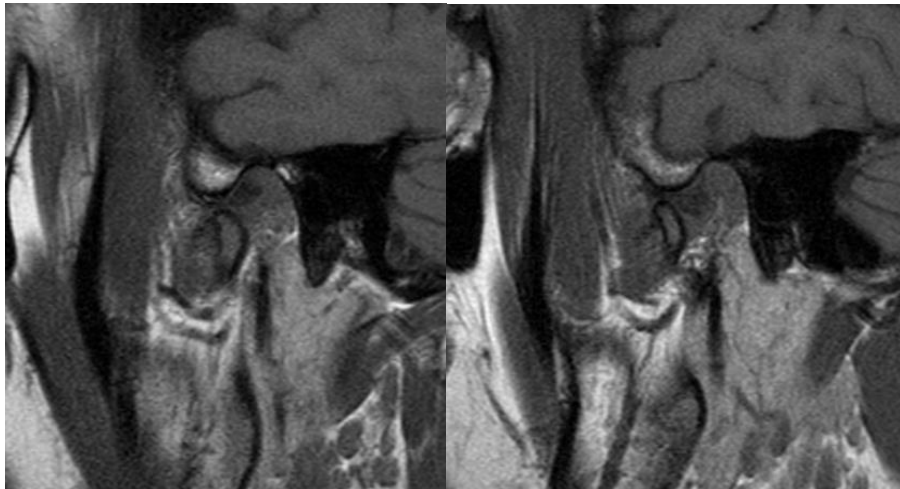


Fig. 5: Post-Treatment Sagittal T1 Weighted MRI in open mouth position of right (a) and left (b) TMJ show normal 'Bow-Tie' appearance suggesting disc reduction

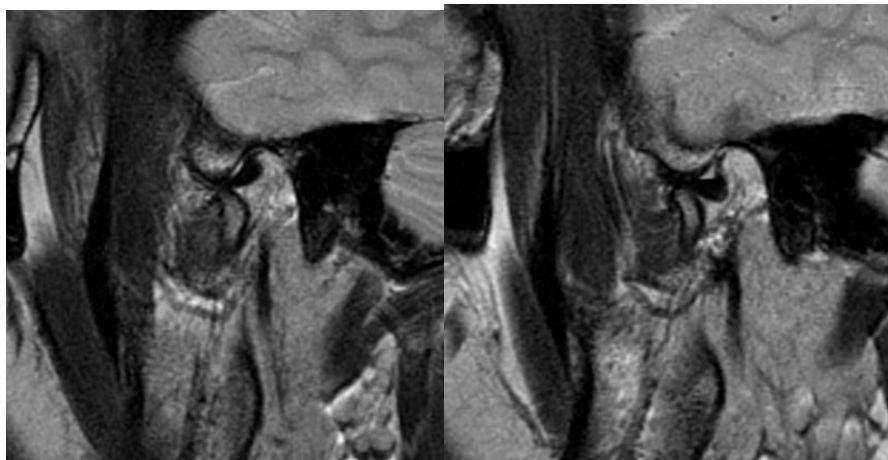


Fig. 6: Post-Treatment Sagittal T2 Weighted MRI in open mouth position of right (a) and left (b) TMJ show normal 'bow-tie' appearance suggesting disc recapture

Discussion

The most common cause of internal derangement of TMJ is an anterior disc displacement. Anterior disc displacement without reduction is also referred to as a closed lock and in acute cases it is accompanied with a history of long-standing TMJ click that abruptly disappears followed by a sudden restriction in mandibular opening, pain over the joint, limited lateral excursions to contra-lateral side and deflection of mandible to the affected side.⁽¹⁾

Magnetic resonance imaging is considered as the imaging technique of choice in the diagnosis of TMJ dysfunction. Localization of disk is very important in the diagnosis of TMJ internal derangement and can easily be achieved with MR imaging. The prevalence of TMJ pain in MRI proven TMJ internal derangement has been reported as high as 82%.^(2,3) A review of 144 internal derangement cases by Whyte et al revealed that MR imaging allows analysis of disc position in both sagittal and coronal planes and dynamic assessment of condylar translation and disc movement during opening and closing the mouth.⁽⁴⁾

Farrar has estimated that up to 25% of the entire population has an internal derangement, which is initially treated with non-surgical methods consisting of manipulation, physiotherapy and splint therapy.⁽⁵⁾ Occlusal splints are the most commonly employed non-surgical treatment for TMJ internal derangement, through which approximately 90% of all TMD cases can be successfully treated.^(6,7) Although an anterior repositioning splint is more widely employed in the management of anterior disc displacement of TMJ, a stabilization splint is a more conservative therapy that does not result in corresponding change in the occlusion.^(8,9) In a 30 year follow up of patients with internal derangement, De Leeuw et al concluded that non-surgical approach achieved long term effects and the initiation of splint use within a short period after symptom onset was found to increase treatment efficiency.⁽¹⁰⁾

According to American Academy of Orofacial Pain guidelines a flat plane stabilization splint provides joint stabilization, protect the teeth, redistribute the occlusal forces, relax the elevator muscles and decrease bruxism. Also wearing the appliance increases the patient's awareness of jaw habits and helps alter the rest position of the mandible to a more relaxed, open position.⁽¹¹⁾

The clinical efficacy of stabilization splint used with pivot splint was established on 23 patients with anterior disc displacement without reduction by Muhtarogullari et al. Elimination of pain and increased range of mandibular motion was observed in all the patients at the end of 24 weeks, though the position of the disc was not established by MRI after completion of treatment.⁽¹²⁾

Badel et al conducted an MRI quantitative evaluation on the position of the disc before, during and

at 5 months follow up of Michigan splint wear in 25 patients and concluded that no significant improvement in disc position was observed in disc displacement without reduction and only limited positive effect in disc displacements with reduction. In both these forms of disc displacement clinical improvement was comparable.⁽¹³⁾ A pilot study by Chen et al on seven symptomatic TMJ dysfunction patients treated with stabilization splint revealed clinical improvement in all subjects but disc recapture in none.⁽¹⁴⁾

A randomized clinical trial on comparative evaluation of centric and distraction splint for anterior disc displacement without reduction on Seventy four patients for 6 months showed significant and comparable improvement in both the groups.⁽¹⁵⁾

In the present case report the disc continued to remain in an anterior position but disc reduction was achieved after 4 months of stabilization splint therapy which continued to reduce even after a year of cessation of treatment.

Conclusion

The use of occlusal splint may not provide satisfactory outcomes in all cases of TMJ internal derangement.^(16,17) However; this case report provides MRI evidence of favourable treatment outcome of TMJ internal derangement by utilizing a stabilization splint. The clinical improvement of patient was accompanied by reduction of non reducible TMJ disc. The literature is flooded with various splint designs with comparable efficacies. Determination of appropriate type of splint therapy depends on the specific diagnosis of TMDs. Oral splints can effectively treat both myogenous and intracapsular conditions in properly selected patients.^(18,19) In clinical practice the authors have experienced that the flat plane stabilization splint is easily constructed, well tolerated by the patients, successfully relieves acute symptoms of TMJ pain and dysfunction, permissive in nature with no irreversible occlusal changes with short-term wear and may assist in reduction of a non-reducing disc.

References

1. Burket LW, Greenberg MS, Glick M, Ship JA. Burket's oral medicine, 12th Edition. PMPH-USA; 2008.
2. Tomas X, Pomes J, Berenguer J, Quinto L, Nicolau C, Mercader JM, Castro V. MR Imaging of Temporomandibular Joint Dysfunction: A Pictorial Review 1. Radiographics. 2006;26(3):765-81.
3. Tasaki MM, Westesson PL, Isberg AM, Ren YF, Tallents RH. Classification and prevalence of temporomandibular joint disk displacement in patients and symptom-free volunteers. American Journal of Orthodontics and Dentofacial Orthopedics. 1996;109(3):249-62.
4. Whyte AM, McNamara D, Rosenberg I, Whyte AW. Magnetic resonance imaging in the evaluation of temporomandibular joint disc displacement—a review of 144 cases. International journal of oral and maxillofacial surgery. 2006;35(8):696-703.

5. Farrar WB. Myofascial Pain-Dysfunction Syndrome. The Journal of the American Dental Association. 1981;102(1):12.
6. Chung SC, Kim HS. The effect of the stabilization splint on the TMJ closed lock. Cranio: the journal of craniomandibular practice. 1993;11(2):95-101.
7. Randolph CS, Greene CS, Moretti R, Forbes D, Perry HT. Conservative management of temporomandibular disorders: a posttreatment comparison between patients from a university clinic and from private practice. American Journal of Orthodontics and Dentofacial Orthopedics. 1990;98(1):77-82.
8. Farrar WB. Differentiation of temporomandibular joint dysfunction to simplify treatment. The Journal of prosthetic dentistry. 1972;28(6):629-36.
9. Manns A, Chan C, Miralles R. Influence of group function and canine guidance on electromyographic activity of elevator muscles. The Journal of prosthetic dentistry. 1987;57(4):494-501.
10. de Leeuw R, Boering G, Stegenga B, Lambert GM. Radiographic signs of temporomandibular joint osteoarthritis and internal derangement 30 years after nonsurgical treatment. Oral Surgery, Oral Medicine, Oral Pathology, Oral Radiology, and Endodontology. 1995;79(3):382-92.
11. American Academy of Orofacial Pain. Guidelines for assessment, diagnosis, and management. 3rd ed. Chicago: Quintessence; 1996. p. 150.
12. Muhtarogullari M, Avci M, Yuzugullu B. Efficiency of pivot splints as jaw exercise apparatus in combination with stabilization splints in anterior disc displacement without reduction: a retrospective study. Head & face medicine. 2014;10(1):42.
13. Badel T, Marotti M, Kern J, Laškarin M. A quantitative analysis of splint therapy of displaced temporomandibular joint disc. Annals of Anatomy-Anatomischer Anzeiger. 2009;191(3):280-7.
14. Chen CW, Boulton JL, Gage JP. Effects of splint therapy in TMJ dysfunction: a study using magnetic resonance imaging. Australian dental journal. 1995;40(2):71-8.
15. Schmitter M, Zahran M, Duc JM, Henschel V, Rammelsberg P. Conservative therapy in patients with anterior disc displacement without reduction using 2 common splints: a randomized clinical trial. Journal of oral and maxillofacial surgery. 2005;63(9):1295-303.
16. Lundh H, Westesson PL, Eriksson L, Brooks SL. Temporomandibular joint disk displacement without reduction: treatment with flat occlusal splint versus no treatment. Oral surgery, oral medicine, oral pathology. 1992;73(6):655-8.
17. Magdaleno F, Ginestal E. Side effects of stabilization occlusal splints: a report of three cases and literature review. CRANIO®. 2010;28(2):128-35.
18. Dylina TJ. A common-sense approach to splint therapy. The Journal of prosthetic dentistry. 2001;86(5):539-45.
19. Klasser GD, Greene CS. Oral appliances in the management of temporomandibular disorders. Oral Surgery, Oral Medicine, Oral Pathology, Oral Radiology, and Endodontology. 2009;107(2):212-23.