

## Prosthetic management of hemimandibulectomy patient

Lara Jain<sup>1</sup>, Himanshu Aeran<sup>2\*</sup>, Neeraj Sharma<sup>3</sup>

<sup>1</sup>PG Student, <sup>2</sup>Director Principal, Professor & HOD, <sup>3</sup>Reader, Dept. of Prosthodontics, Seema Dental College & Hospital, Rishikesh, Uttarakhand

**\*Corresponding Author:**  
Email: drhimanu@yahoo.com

### Abstract

Segmental resection of the mandible commonly results in the Mandibular deviation is multifactorial defect and its severity is based on the extent of osseous and soft tissue involvement, degree of tongue impaired, the loss of sensory and motor innervations, the type of wound closure, the presence of remaining natural teeth and finally the first initiation of prosthetic treatment. Prosthodontic treatment along with physical therapy may be useful in reducing mandibular deviation and improving masticatory efficiency. This clinical report describes the use of a cue-sill prosthesis to rehabilitate a hemimandibulectomy case for improved masticatory efficiency and esthetics.

### Introduction

Odontogenic tumors of epithelial origin commonly seen in posterior mandible are often treated with surgical excision. Neoplastic lesions of the oral cavity requires resection involving mandible, floor of the mouth, tongue and also palate as per oral surgical assessment.

If mandibular continuity is not restored during surgical closure of wound, the remaining mandibular segment will retrude and deviate toward the surgical side at the vertical dimension of rest. This mandibular deviation is mainly due to uncompensated influence of contralateral musculature particularly the internal pterygoid muscle and pull from the contraction of cicatricial tissue on resected side.

A mandibular guidance prosthesis can be defined as a maxillofacial prosthesis used to maintain a functional position for the jaws (maxillae and mandible), improve speech and deglutition following trauma or/and surgery to the mandible or/and adjacent structures. The main objective of using a guidance prosthesis is to re-educate the mandibular muscles to re-establish an acceptable occlusal relationship (physiotherapeutic function) for residual hemimandible.

Several modalities to return the mandible to optimum maxilla-mandibular relationship have been described. These include intermaxillary fixation, vacuum formed PVC splints, mandibular guidance prostheses and a widened maxillary occlusal table using a double row of teeth.

The prosthodontic rehabilitation of patients with mandibular defects is challenging. The unilateral loss of mandibular continuity due to surgery or trauma results in mandibular deviation toward the defect side with lack of occlusion. Unlike the dentulous patients, edentulous patients are difficult to retrain mandibular movement and many times may never achieve proper maxillomandibular relationships for optimum mastication and appearance.

There are several unfavourable, physical limitations when rehabilitating completely edentulous patients with resected mandibles. This includes resected skin grafts, scar tissue and deviation of the resected mandibles,

limited coordinative ability, and resorbed ridges. One of the basic objectives in rehabilitation is to retrain the muscles for mandibular denture control and repeated occlusal approximation. A case of a partially edentulous hemimandibulectomy patient for replacement of missing teeth after 2years of cancer therapy reported. Initial evaluation of considering prosthetic management indicated poor prognosis. However, the patient's positive mental attitude toward treatment along with the application of basic fundamental principles by the prosthodontist during treatment procedure led to fabricate a simple, effective functioning prosthesis that showed positive satisfactory prosthetic results.

### Classification

**Cantor & Curtis** provided a hemimandibulectomy classification for edentulous patient that can also be applied in partially edentulous arches.

**Class I:** Mandibular resection involving alveolar defect with preservation of mandibular continuity.

**Class II:** Resection defects involve loss of mandibular continuity distal to the canine area.

**Class III:** Resection defect involves loss up to the mandibular midline region.

**Class IV:** Resection defect involves the lateral aspect of the mandible, but are augmented to maintain pseudoarticulation of bone and soft tissues in the region of the ascending ramus.

**Class V:** Resection defect involves the symphysis and parasymphysis region only, augmented to preserve bilateral temporomandibular articulations.

**Class VI:** Similar to class V, except that the mandibular continuity is not restored. This article describes the use of a cue-sill prosthesis in a patient who had undergone partial mandibulectomy.

### Case Report

A 53 year old male patient reported to the Department of Prosthodontics in Seema Dental College and Hospital, Rishikesh, with a chief complaint of asymmetry of the mandible, drooling of saliva and difficulty in chewing and speaking since 10 months. The

medical history revealed that he was diagnosed for squamous cell carcinoma on the right side of the mandible, for which he had undergone extensive resection of the mandible on right side 2 years back. Intraoral examination revealed thick buccal mucosa with scar formation and obliteration of alveolar ridge, buccal and lingual sulci in the region of defect. Mouth opening was found to be reduced to 25mm and mandibular deviation of 18-20 mm towards right side was found on opening of jaw. The patient was able to achieve an appropriate mediolateral position of the mandible but was unable to repeat this position consistently for adequate mastication. An extra oral examination showed asymmetrical face, a convex profile and deviation of the mandible on opening and closing. According to the existing conditions a cue-sill prosthesis was planned.

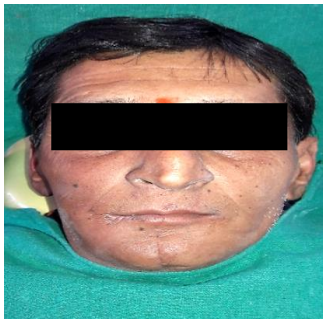

Fig. 1

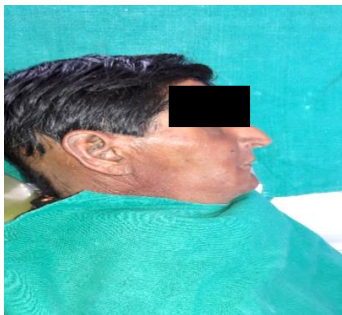

Fig. 2

Fig. 1, 2: Preoperative Extraoral View

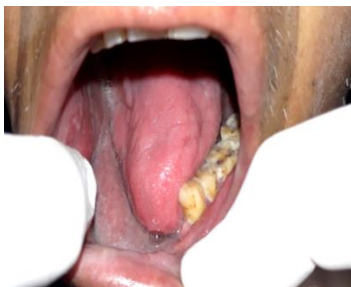

Fig. 3

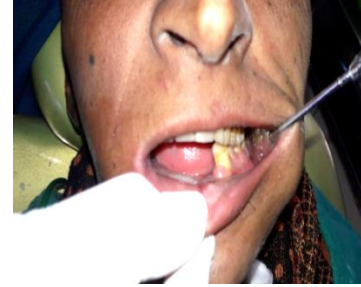

Fig. 4

Fig. 3, 4: Preoperative Intraoral View

### Procedure

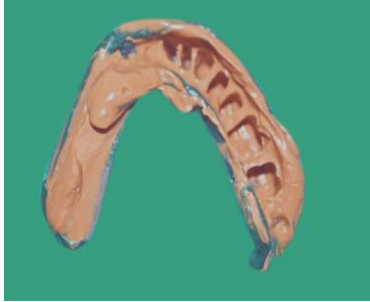
Preliminary impressions were made with irreversible hydrocolloid using stock metal trays. (Fig. 5). Casts were prepared and custom trays were fabricated (Fig. 6). The tray was border-molded with modeling plastic (DPI Tracing stick. Dental products of India, Mumbai, India). Final impression was made with light-body vinyl polysiloxane (Aquasil, Dentsply, Milford, DE) (Fig. 7). This impression material was chosen to produce minimal tissue displacement. Impression was poured with type III dental stone to obtain a master cast. Record base was fabricated and wax occlusal rim was made. Maxillomandibular relation was recorded with wax interocclusal record.



Fig. 5: Preliminary Impression

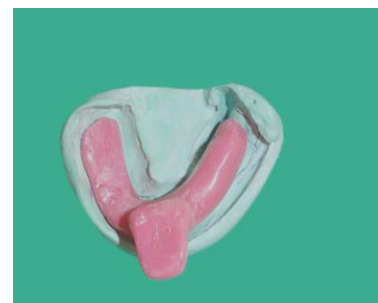

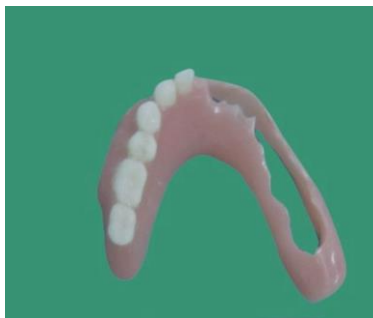Fig. 6: Custom Tray



**Fig. 7: Secondary Impression**

A 21 gauge stainless steel orthodontic wire was manipulated to obtain the framework of the guide flange prosthesis in mandibular arch. The framework consisted of a rectangular wire projection for the guide flange having width equal to the combined width of the opposing two maxillary premolars. The retentive arms of the framework passed to the lingual side mesial to mandibular first premolar and distal to mandibular first molar. A maxillary retentive plate was fabricated with Adam's clasps on left and right maxillary first molars to stabilize the maxillary teeth against the pressure exerted by the mandibular guide flange. A wax set-up was tried in the mouth and was checked for esthetics, phonetics, occlusal vertical dimension and occlusion. The denture was fabricated, finish and polished. (Fig. 8)



**Fig. 8: Cu-sil Denture**

Freedom of movement and lack of intercuspation was checked before denture insertion. The dentures were evaluated intraorally and the mandible was manipulated to the static centric position area. Any interference in normal movements was corrected. The dentures were removed, polished and then inserted. The patient was given post insertion instructions and was motivated to make efforts to learn to adapt to the new dentures. Simple exercises such as repeated opening and closing of mandible were suggested to the patient. This helped the patient to learn to manipulate the lower denture into the proper position. Initially, retention of the dentures, especially the lower one was inadequate but this improved with constant use. Within a week, the patient expressed satisfaction in mastication and phonetics.

## Discussion

The reasons for segmented resected mandible are multifactorial with several collateral problems which alter prosthetic prognosis. However, the four significant factors that affect the amount of prosthetic rehabilitation include the site and extent of surgery, the effect of radiation, presence or absence of teeth and psychological impact.

Basic objective of rehabilitation is retraining the remaining mandibular muscles to stabilize the mandibular denture by providing an acceptable maxilla-mandibular relationship. When surgical reconstruction following mandibulectomy is not feasible, various prosthesis are used to reduce or eliminate mandibular deviation. The tissue in the surgical region is scarred, uneven, unsupported by bone and movable in various degrees. These features make the area unsuitable to be covered by an appliance or to receive loading.

The frontal plane rotation occurs due to loss of proprioceptive sense of occlusion, which leads to uncoordinated and less precise movement of the mandible. Also, due to attachment loss of muscles of mastication on surgical side, there is significant rotation of the mandible upon forceful closure. When the force of closure increases, the residual mandible actually rotates through the frontal plane. The primary cause for abnormal position of the mandible may be due to the action of suprahyoid muscle and uncompensated influence of contralateral internal pterygoid muscle.

The present case, physiotherapy was suggested to assist the patient in improving the symmetrical arc of closure and finding centric occlusion position without guiding her mandible manually. The exercises consisted of simple opening and closing of the mandible with and without the prosthesis. After 1-week postinsertion, the patient was able to close the mandible in functional maxillomandibular occlusion position without manual assistance. The mandibulectomy patient is difficult to manage because the prosthodontist is limited in his ability to provide a reasonable and practical occlusal scheme. However, these patients need the definitive clinical and psychological support of the prosthodontist.

This article highlights functional rehabilitation of hemimandibulectomy patient who has undergone resection without reconstruction. Literature review advocates fabrication of guide flange or palatal ramp prosthesis for such patients to prevent deviation of the mandible and to improve masticatory function and aesthetics and a cue-sil prosthesis was the best choice to rehabilitate the patient.

## Summary

A hemimandibulectomy can have many debilitating consequences, the physical and psychological trauma associated with the surgical resection of mandible following neoplastic diseases is often compounded by the loss of proper function of the masticator apparatus. Early prosthodontic intervention is a necessary approach

towards restoring the maxillomandibular relationship. A mandibular guide flange prosthesis is an important adjunct for achieving this goal. A well fabricated prosthesis and an appropriate mandibular exercise regimen can go a long way in restoring the patient's physiological and psychological wellbeing. Such as disturbed occlusion, a disoriented masticatory cycle, facial disfigurement, distorted speech, and salivation problems. If prosthetic treatment begins sometime following surgery and the cicatricial tissue has already consolidated, a guidance prosthesis to guide the mandible into a functional occlusion is an option. Thus a cue-sill prosthesis was the best choice to rehabilitate the patient.

### **References**

1. Cantor, R., Curtis, T. A., Shipp, T., Beumer, J., and Vogel, B. S.: Maxillary Speech Prostheses for Mandibular Surgical Defects, *J. Prosthet. Dent.* 22: 253-260, 1969.
2. Cantor, R., and Curtis, T. A.: Prosthetic Management of Edentulous Mandibulectomy Patients. Part I. Anatomic, Physiologic, and Psychologic Considerations, *J. Prosthet. Dent.* 25: 446-457, 1971.
3. Edgerton, M., and Pyott, J.: Surgery and Prosthesis in Jaw Reconstruction, *J. Prosthet. Dent.* 4:257-262, 1954.
4. Ackerman, A. J.: The Prosthetic Management of Oral and Facial Defects Following Cancer Surgery, *J. Prosthet. Dent.* 5:413-432, 1955.
5. Robinson, J. E., and Rubright, W. C.: Use of a Guide Plane for Maintaining the Residual
6. Fragment in Partial or Hemi-mandibulectomy, *J. Prosthet. Dent.* 14:992-999, 1964.
7. Adisman, I. K., and Birnbach, S.: Surgical Prosthesis for Reconstructive Mandibular Surgery, *J. Prosthet. Dent.* 16:988-991, 1966.