

Review of cases of nevus of Ota: Rare presentation with suggested amendment of Tanino's classification

Shobhana Dube^{1,*}, Charu Singh², Susrut Dube³

¹Associate Professor, Dept. of Ophthalmology, Career Institute of Medical Sciences & Hospital, Lucknow, Uttar Pradesh, ²Professor, Dept. of ENT, Integral Institute of Medical Sciences & Research, Lucknow, Uttar Pradesh, ³Student, H.S. Cherry Hill High School, New Jersey, U.S.A.

***Corresponding Author:**

Email: shobhanadube@gmail.com

Abstract

Introduction: Nevus of Ota or Oculodermal Melanocytosis is hyperpigmentation of facial skin in the distribution of the first & second divisions of trigeminal nerve. They are frequently associated with ipsilateral melanocytosis of the conjunctiva, sclera, cornea & uveal tract. Approximately 10% of cases are bilateral. We report a case of 80 year old female patient presenting with bilateral pigmented areas over all the three divisions of trigeminal nerve on both sides and also extending to hard palate, soft palate, buccal mucosa and nasopharyngeal mucosa. This patient also has bilateral open angle glaucoma.

Conclusions: Bilateral involvement is rare with nevus of Ota; involvement of such extensive nature along with bilateral open angle glaucoma has never been reported in the literature to the best of our knowledge.

Keywords: Buccal Mucosa, Bilateral Nevus of Ota, Hard Palate, Nasopharyngeal Mucosa, Oculodermal melanocytosis, Primary Open Angle Glaucoma, Soft Palate, Three divisions of Trigeminal Nerve

Introduction

Nevus of Ota (Oculodermal Melanocytosis) is a dermal melanocytic hamartoma that presents as bluish hyperpigmentation along the first or second divisions of Trigeminal Nerve. It is usually unilateral (90%) but can be bilateral in 5-10% cases. It has a significant preponderance among females with male to female ratio being 1:4.8. Cause of Nevus of Ota is unknown but female sex hormones have been suggested as a potent stimuli. Other stimuli such as infection, trauma or ultraviolet light exposures have also been reported to trigger the onset of nevus. The above factors have been proposed to stimulate the production of Melanin from amelanotic melanocytes leading to development of clinically apparent nevus.

Review of Literature

Oculodermal Melanocytosis was described by Hulkey in 1861. Pusey reported pigmented lesion of facial skin along with ipsilateral scleral pigmentation in a Chinese student in 1916.⁽¹⁾ Ota described this condition in 1939 as Nevus Fuscoceruleus Ophthalmomaxillaris^(2,3) and in the same year, Tanino published a case series with a classification system and named it Nevus Fuscoceruleus Ophthalmomaxillaris of Ota.⁽⁴⁾ In honour of the pioneering work done by Dr Masao Ota, the disease is now called Nevus of Ota.

In 1985, Page DG et al⁽⁵⁾ reported associated palatal involvement with Nevus of Ota.

In 1990, Teekhaesaneet et al⁽⁶⁾ reported 194 patients with Oculodermal Melanocytosis, in which, there was dermal pigmentation along the Ophthalmic and Maxillary divisions of trigeminal nerve, episcleral

pigmentation, nasal and buccal mucosal hyperpigmentation.

Hirayama et al⁽⁸⁾ reported dermal pigmentation in Nevus of Ota in 1991 and classified it on the basis of Histopathological features.

Gangopadhyaya KA⁽⁹⁾ reported two cases of bilateral Nevus of Ota in 2000 with only dermal involvement.

Rathi SK⁽¹⁰⁾ reported a case of bilateral Nevus of Ota in 2002 with Oral mucosa and Palatal involvement.

Kannan SK⁽¹¹⁾ reported two cases of Oculodermal Melanocytosis in 2003, one of which exhibited palatal pigmentation.

JR Turnbull et al⁽¹²⁾ reported a rare case of a bilateral Nevus of Ota in 2004 associated with enoral melanocytosis in a white European person.

Sekar S et al⁽¹³⁾ reported a series of 15 cases of Nevus of Ota in 2008. Most of the patients in this series had lesions at birth and mostly, patients belonged to Tanino class II type. Alae Nasii and Hard Palate was involved in three of their cases.

Gaurav Sharma⁽¹⁴⁾ reported a 22 year old male patient in 2011 with U/L hyperpigmented macules on left midface with involvement of left side of Hard Palate.

Shishir Ram Shetty et al⁽¹⁵⁾ reported a case of Nevus of Ota in 2011 with U/L Buccal Mucosal involvement.

Guledgub MV et al⁽¹⁶⁾ reported right sided U/L Congenital Nevus of Ota in 2011 in a 36 year old female patient with involvement of right side of the posterior part of Hard Palate with no other abnormality.

AK Mukhopadhyaya⁽¹⁷⁾ reported U/L Nevus of Ota with Bilateral Nevus of Ito and Palatal lesion in 2013

with proposed clinical modification of Tanino's Classification.

Mohan RP et al,⁽¹⁸⁾ in 2013, reported a case of 25 year old female patient with U/L right sided facial hyperpigmentation with bluish coloured plaque on the entire buccal mucosa.

In 2014, RM Bhat et al⁽¹⁹⁾ reported acquired B/L Nevus of Ota like macules with Hard Palate involvement in a 42 year old male patient.

Sehgal VN et al⁽²⁰⁾ in 2015, reported a case of 34 year old male patient with hyperpigmentation of upper right periorbital region and Hard Palate.

In 2015, Peeyush Shivhare et al⁽²¹⁾ reported a case of Nevus of Ota with involvement of right side of upper and middle third of face with involvement of marginal and attached gingiva, right border of tongue and right side of hard palate with no other abnormality.

Rashmi Maheshwari et al⁽²²⁾ in 2016, reported a case of U/L Nevus of Ota in a 23 year old female patient with hyperpigmentation on the left side of face but with no Oral mucosal involvement.

In the present report, an 80 year old female patient presented to us with complaints of decreased vision in both eyes. Thorough examination of the patient revealed presence of hyperpigmented areas bilaterally over forehead, temples, malar area, cheeks, nasal bridge, alae nasii, jaw, zygomatic region, pinna and periorbital area. Conjunctiva and Sclera were also hyperpigmented on both sides. According to the patient, this hyper pigmentation was present since birth and she never sought any treatment for this, in the past. Endoscopic ENT Examination revealed bluish blackish pigmentation on hard palate, soft palate, buccal mucosa and Nasopharyngeal mucosa of both sides. There was similar pigmentation on the Pinna of both sides but no pigmentation was noted on Tympanic membranes.

Visual acuity of right eye was approximately finger counting at 2 meters and that of left eye was finger counting at 3 meters. Intraocular pressure of right eye was 26mm Hg and that of Left eye was 24mm Hg. Central Corneal thickness of Right Eye was 558 μ and that of Left Eye was 540 μ .

Conjunctiva and Sclera showed hyper pigmentation of both sides but, cornea & iris showed no hyper pigmentation. Gonioscopy of both eyes revealed open angles with hyper pigmentation of the angles.

Dilated pupillary examination revealed Nuclear and Cortical Cataracts in both eyes.

Fundus examination was hazy due to Cataract but Optic disc was hazily visible with Cup Disc ratio of 0.8 in Right eye and Cup Disc ratio of 0.7 in Left eye.

Patient was advised Topical anti-glaucoma medication and lubricating eye drops and was advised to undergo Combined Surgery of right eye first followed by left eye.

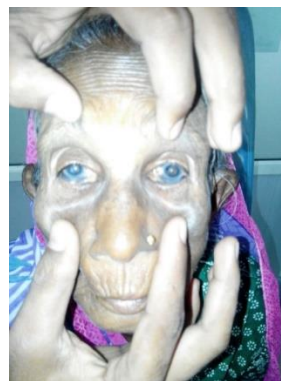

Fig. 1

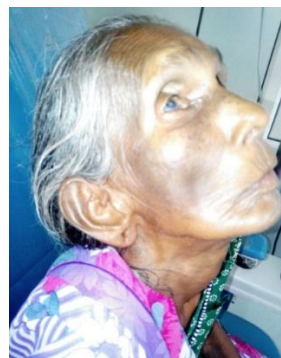

Fig. 2

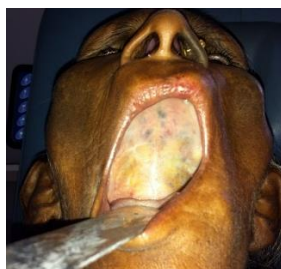


Fig. 3

Fig. 1-3: Photographs of patient showing bilateral extensive involvement of face, Palate(Hard & Soft Palate), Buccal Mucosa

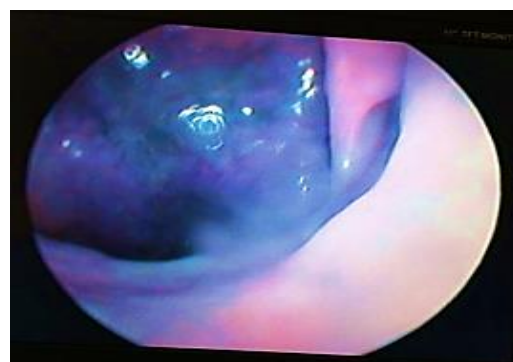


Fig. 4

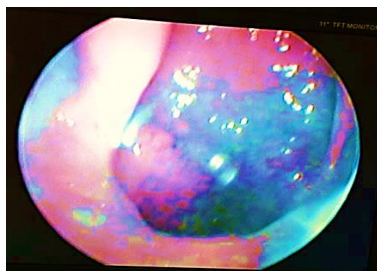


Fig. 5

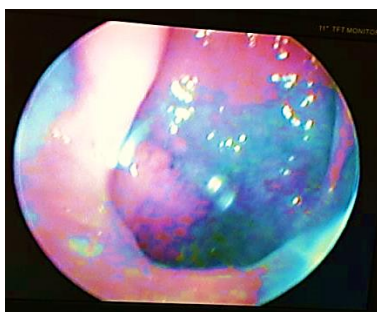


Fig. 6

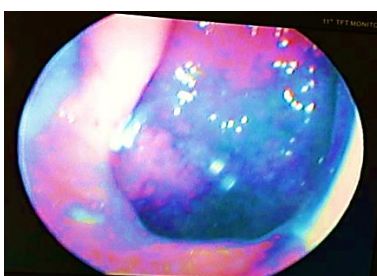


Fig. 7

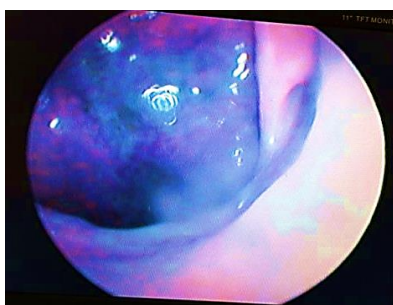

Fig. 8

Fig. 4-8: Photographs of Endoscopic view of Pharynx, Nasopharynx

Discussion

This nevus is caused by melanocytes that have not migrated completely from neural crest to the epidermis during the embryonic phase. Consequently, the melanocytes enter the ophthalmic & maxillary branches of the trigeminal nerve creating spots on consecutive regions.

The Nevus of Ota is mostly unilateral (90%) or may be bilateral (5 to 10%) and in addition to skin, it may involve ocular & oral mucosa. The Sclera is involved in two thirds of the cases causing an increased

risk of Glaucoma.⁽²²⁾ Women are nearly five times more likely to be affected than Men. The prevalence seems to be highest in Japanese population (0.2 to 0.6%),⁽²³⁾ it affects 0.014-0.034% of the Asian population, and other ethnic groups with increased prevalence in Africans, African Americans and East Indians. It is very rare in Caucasians.

The first peak of onset of Nevus of Ota occurs in infancy with approximately 50% of cases present at birth. The second peak of onset for Nevus of Ota is seen during adolescence. Exact Cause of Nevus of Ota is unknown.⁽²⁴⁾

Several classification systems and modifications have been described^(6,13,14,22,23) since Tanino classified it first in 1939. Most of the dermatologist across the world still consider Tanino's classification best which is based on extent of cutaneous involvement. The classification system described by Huang et al⁽²⁴⁾ as "PUMCH classification of Nevus of Ota" (named after Peking Union Medical College & Hospital) appears promising and attempts to fill the gaps, more study is needed to establish it. Tanino's classification has been the most useful clinical classification based on the extent of Cutaneous involvement.

Tanino's Classification

IA: Upper/Lower Eyelid, Periorbital & Temporal region

IB: Infrapalpebral, Nasolabial fold & Zygomatic region

IC: Forehead

ID: Nasal

II: Over Upper & Lower Eyelids, Periocular, Zygomatic, Cheek & Temple

III: Scalp, Forehead, Eyebrow & Nose

IV: Bilateral

We propose an amendment to the above classification to include the Extracutaneous involvement in Nevus of Ota which is as follows:

Modified Classification

Type I to IV—As suggested in Tanino's classification

Type V—U/L Nevus of Ota with U/L Mucosal involvement

VA Ocular

VB Oral Mucosa involving either of Buccal Mucosa, Palatal (Hard and Soft) Mucosa, Nasopharyngeal Mucosa or any other area

VC Nasal Mucosa

VD Tympanic, Aural Mucosa

VE Leptomeninges

Type VI B/L Nevus of Ota with U/L mucosal involvement

VIA Ocular

VIB Oral Mucosa involving either of Buccal Mucosa, Palatal Mucosa (Hard and Soft), Nasopharyngeal Mucosa or any other area

VIC Nasal Mucosa

VID Tympanic, Aural Mucosa

VIE Leptomeninges

Type **VII** B/L Nevus of Ota with B/L Mucosal involvement

VIIA Ocular

VIIIB Oral Mucosa involving either of Buccal Mucosa, Palatal Mucosa(Hard and Soft), Nasopharyngeal Mucosa or any other area

VIIIC Nasal Mucosa**VIIID** Tympanic, Aural Mucosa**VIIIE** Leptomeninges

Type **VIII** any of the above with other associations including complications like Cataract, Glaucoma, Choroidal

Melanoma, Orbital Melanocytoma, Optic disc, Hemangioblastoma, Meningeal Melanocytoma etc.

Diagnosis is mainly clinical & biopsy is rarely needed.

A careful Ophthalmologic examination and regular follow up should be done for patients of Nevus of Ota cases because of a reported 10.3% association with increased intraocular pressure.⁽⁷⁾ Open angle glaucoma followed by Choroidal Melanoma remains the most common associated ocular finding of Nevus of Ota. The Glaucoma appears to be due to increased pigmentation of trabecular meshwork impeding aqueous flow. Other reported ocular findings with Nevus of Ota include thick corneas,⁽²⁷⁾ heterochromia iridis,⁽²⁸⁾ iris mammillations,⁽²⁹⁾ iris melanoma,⁽³⁰⁾ choroidal melanoma,^(31,32,33,34,35,36,37) Orbital melanoma,⁽³⁸⁻⁴⁰⁾ Orbital melanocytoma,⁽⁴¹⁾ pigmentary mottling of fundus,^(28,35,42) nevus at optic disc⁽²⁸⁾ and Optic disc hemangioblastoma.^(43,44)

Although very rare, meningeal melanocytoma appears to be most common extra ocular association with Nevus of Ota.

Cosmetic camouflaging can mask the facial pigmentation and pulsed Q switched laser surgery is currently treatment of choice for Nevus of Ota.

Nevus of Ota can cause facial disfigurement resulting in Emotional and Psychological distress. Association of uveal melanoma & glaucoma makes it potentially sight threatening disease. Careful ocular examination at initial presentation and lifelong follow up is required to prevent visual loss.

Our Case belonged to Type VIII of Modified classification along with Cutaneous involvement as described in Tanino's type IA, B, C, D, II & III and along all three divisions of trigeminal Nerve, that too, bilateral with palatal mucosa, buccal mucosa & nasopharyngeal mucosa involvement along with bilateral Open angle Glaucoma and Cataract, making our case a rarity and the first one to be reported.

References

1. I: Mitteilung: beobachtunguber lokalisation, verfarbung, Anordnung and histologische veränderung. Naevus Fusco-caeruleus Ophthalmomaxillaris Ota. Jpn J Dermatol. 1939;46:435-451.
2. Ota M, Tanino H. Naevus Fusco-caeruleus ophthalmomaxillaris and melanosis bulbi. Tokyo Fji Shinshi 1939;63:1243 – 5.
3. Ota M, Tanino H. A variety of Nevus frequently encountered in Japan, nevus fusco-caeruleus ophthalmomaxillaris and its relationship to pigmentary changes in the eye. Tokyo med J.1939;63:1243-4.
4. Ota M, Tanino H.Nevus fuscoceruleus ophthalmomaxillaris Ota. Jpn J Dermatol 1939;46:435-451.
5. Page DG, Svirsky JA, Kaugars GE. Nevus of Ota with associated Palatal involvement. Oral Surgery, Oral Medicine, Oral Pathology 1985; 59(3):282=4.
6. Teekhasaenee C, Ritch R, Rutinin U, Leelawongs N. Ocular Findings in Oculodermal Melanocytosis. Arch Ophthalmol 1990, Aug:108(8) 1114-20.
7. Teekhasaenee C, Ritch R, Rutinin U, Leelawongs N. Glaucoma in Oculodermal Melanocytosis. Ophthalmology, 1990 May;97(5):562-70.
8. Hirayama T, Suzuki T.A new classification of Ota's nevus based on histopathological features. Dermatologica. 1991;183(3):169-72.
9. Gangopadhyaya KA. Bilateral Nevus of Ota. Indian Journal of Dermatology Venereology and Leprology, 2000;66:104–105(3).
10. Rathi SK. Bilateral Nevus of Ota with Oral Mucosal involvement. Indian Journal of Dermatology Venereology and Leprology,2002;68(2):104.
11. Kannan SK. Oculodermal Melanocytosis – Nevus of Ota (with Palatal Pigmentation). Indian Journal of Dent Res. 2003 Oct – Dec:14(4):230 – 3.
12. JR Turnbull, Ch Assaf, Chc Zouboulis and B Tebbe. Bilateral Nevus of Ota: A rare manifestation in a Caucasian. Journal of the European Academy of Dermatology and Venereology Vol. 18, Issue 3, Page 353 – 355 May 2004.
13. Sekar S, Kuruvila M, Pal HS. Nevus of Ota: a series of 15 cases. Indian Journal of Dermatology Venereology and Leprology, 2008 March – April;74(2):125–7.
14. Gaurav Sharma & Archana Nagpal. Nevus of Ota with rare palatal involvement: A case report with emphasis on differential diagnosis. Case Reports in Dentistry Vol 2011 (2011)Article ID 670679, 4 pages.
15. Shishir Ram Shetty, Babu G Subhas, Kumuda Arvind and Renita Castellino. Nevus of Ota with Buccal Mucosal Pigmentation –a rare case. Dent Res J (Isfahan) 2011 Winter: 8(1):52–55.
16. Guledgub MV, Patil K, Srivathsa SH, Malleshi SN. Report of rare Palatal expression with Nevus of Ota with amendment of Tanino's Classification. Indian Journal of Dentist Res 2011;22:850–2.
17. Amiya Kumar Mukhopadhyaya. U/L Nevus of Ota with B/L Nevus of Ito and Palatal lesion: A Case report with a proposed clinical modification of Tanino's classification. Indian J of dermatology Vol 58, issue 4, 2013, pg 286-289.
18. Mohan RP, Verma S, Singh AK, Singh U. Nevus of Ota: the unusual Birthmark: a case review. BMJ Case Report 2013 Mar 1: 2013 E-pub 2013 Mar 1.
19. Ramesh M. Bhat, Hyacinth Peter Pinto, S. Dandekeri, S. Madapaly Ambil. Acquired Bilateral Nevus of Ota like macules with mucosal Involvement: A new variant of Hori's Nevus. Indian Journal of Dermatology 2014 May-Jun 59(3):293–296.
20. Sehgal VN, Syed NH, Aggarwal A, Sharma S, Sehgal S. Nevus of Ota/ Oculodermal Melanocytosis: a rare report of an oral mucosal lesion involving the hard palate. Cutis 2015 Oct;96(4) E 10-2.

21. Peeyush Shivhare, Lata S, Monu Yadav, Naqoosh Haidry, Shruthi T Patil. A Nevus of Ota with intraorbital involvement: A rare case report. *International Journal of Oral Health and Medical Research*, July- August 2015/ Vol2/Issue2/ISSN 2395-7387.
22. Rashmi Maheshwari, Vela Desai, MV Sunil Kumar, Isha Gaurav. Unilateral Nevus of Ota: A Case report of Oculodermal Melanocytosis. *Journal of Dental and applied sciences* 2016/Vol 5/ Issue1/Page 39-42.
23. J. A. Khawly, N. Imami, and M. B. Shields. Glaucoma associated with the Nevus of Ota. *Archives of Ophthalmology*, vol. 113, no. 9, pp.1208-1209,1995.
24. Hidano A, Kajima H, Ikeda S, Mizutani H, Miyasato H, Niimura M, Natural history of Nevus of Ota. *Arch Dermatol*. 1967 Feb;95(2):187-95.
25. Hidano A, Kajima H, Ikeda S, Mizutani H, Miyasato H, Niimura M. A new classification of nevus of Ota. *Huang WH, Wang HW, Sun QN, Jin HZ, Liu YH, Ma D et al. Chin Med J (Engl)*. 2013 Oct;126(20):3910-4.
26. Chan HH, Lam LK, Wong DS, Leung RS, Ying SY, Lai CF, et al. Nevus of Ota: a new classification based on the response to laser treatment. *Lasers Surg Med*. 2001;28(3):267-72.
27. Kitagawa K1, Hayasaka S, Nagaki Y. Falsely elevated intraocular pressure due to an abnormally thick cornea in a patient with Nevus of Ota. *Jpn J Ophthalmol*. 2003 Mar-Apr;47(2):142-4.
28. S. Cronemberger, N. Calixto, and H. L. Freitas, "Nevus of Ota: clinical-ophthalmological findings". *Revista Brasileira de Oftalmologia*, vol.70, no 5,pp. 278–283, 2011.
29. Sánchez Marugán B, Acebes García M, García Hinojosa J, León Cabello MJ, Casal Valino M. Iris Mammillation: Three case reports. *Arch Soc Esp Oftalmol* 2014 Jul;89(7):279-81. Doi: 10.1016/j.ofal.2013.04.04 Epub 2013 Aug 1.
30. Qian Y, Zakov ZN, Schoenfield L, Singh AD. Iris melanoma arising in iris nevus in oculodermal melanocytosis. *Surv Ophthalmol*. 2008 J Aug;53(4):411-5. doi: 10.1016/j.survophthal.2008.04.04.
31. Terheyden P, Rickert S, Kämpgen E, Münnich S, Hofmann UB, Bröcker EB, et al. Iris melanoma arising in iris nevus in oculo(dermal) melanocytosis. *Hautarzt*. 2001. Sep;52(9):803-6.
32. Chen YC, Chang CH, Hsu SL, Hsu MW, Lee CL. Malignant melanoma of the choroid in the eye with oculodermal melanocytosis of a Chinese woman. *Kaohsiung. J Med Sci*. 2010 Dec;26(12):673-8. doi:10.1016/S1607-551X(10)70103-0.
33. Yang Q, Wei WB, Yang WL, Li B, Wang GL. Choroidal malignant melanoma in patients with oculodermal melanocytosis: Report of three cases. *Chin Med J (Engl)*. 5;123(1):111-3.
34. Al-Sadhan Y, Shawaf S, Tabbara K. Oculodermal melanosis with Choroidal Melanoma in a black patient: a case report. *Eye (Lond)*.2006 Dec;20(12):1437-8. Epub 2006 Mar 3.v.
35. Sharan S, Grigg JR, Billson FA. Bilateral naevus of Ota with choroidal melanoma and diffuse retinal pigmentation in a dark skin person. *Br J Ophthalmol*. 2005. Nov;89(11):1529.
36. Biswas J, Krishnakumar S. Choroidal melanoma in a black patient with Oculodermal Melanocytosis. *Retina*. 2003 Feb;23(1):126; author reply 126. No abstract available.
37. Shields JA, Shields CL, Naseripour M, Eagle RC, Miller. Choroidal melanoma in a black patient with oculodermal melanocytosis. *Retina*. 2002 Feb;22(1):126-8. No abstract available.
38. Radhadevi CV1, Charles KS, Lathika VK. Orbital Malignant Melanoma associated with Nevus of Ota. *Indian J Ophthalmol*. 2013 Jun;61(6):306-9. doi: 10.4103/0301-4738.109526.
39. Nitta K, Kashima T, Mayuzumi H, Akiyama H, Miyanaga T, Hirato J et al.
40. Animal-type malignant melanoma associated with Nevus of Ota in the orbit of a Japanese Woman: a case report. *Melanoma Res*. 2014 Jun;24(3):286-9.
41. John H, Britto JA. Nonchoroidal intraorbital malignant melanoma arising from Naevus of Ota. *J Plast Reconstr Aesthet Surg*. 2010 Apr;63(4):e387-9 doi:10.1016/j.bjps.2009.09.014. Epub 2009 Oct 21.
42. Tregnago AC, Furlan MV, Bezerra SM, Porto GC, Mendes GG, Henklain JV et al. Orbital melanocytoma completely resected with conservative surgery in association with ipsilateral nevus of Ota: report of a case and review of the literature. *Head Neck* 2015 Apr;37(4):E49-55. doi: 10.1002/hed.23828. Epub 2014 Oct 2.
43. Swann PG. The fundus in oculodermal melanocytosis. Is this a new observation? *Clin Exp Optom*. 2003 May;86(3):183-6.
44. Fine HF, Shields JA, Fisher YL, Yannuzzi LA. Optic disc hemangioblastoma (capillary hemangioma) with ipsilateral Oculodermal Melanocytosis. *Jpn J Ophthalmol*. 2008 May-Jun;52(3):233-4. doi: 10.1007/s10384-007-0520-8 Epub 2008 Jul 27.
45. Zografos L, Gonvers M. Ocular melanocytosis and cavernous haemangioma of the Optic disc. *Br J Ophthalmol*. 1994 Jan;78(1):73-4.