

A rare case of subcutaneous Phaeohyphomycosis caused by *Rhytidhysteron rufulum*

Tejashree A¹, Suchetha C², Visakha K³, Krishna Karthik M^{4,*}

¹Professor, ³PG Student, Dept. of Microbiology, ²Professor, Dept. of Pathology, ⁴Tutor, JSS Medical College, Mysore

***Corresponding Author:**

Email: krishnakarthik46@gmail.com

Abstract

Phaeohyphomycoses are fungal infections, caused by dematiaceous fungi, manifested as Cutaneous and Subcutaneous infections, Keratitis, Osteomyelitis, Meningitis, Sinusitis, and disseminated infections.

This is a case report of a 59 year old diabetic male who presented with noduloulcerative lesion on right leg for two and half months. Biopsy of the lesion revealed septate, dematiaceous fungal hyphae on 10% KOH mount. Fungal culture of the biopsy material on Sabouraud's Dextrose Agar showed velvety, dark brown to black growth with black reverse and identified as dematiaceous fungi- *Rhytidhysteron rufulum*.

Keywords: Phaeohyphomycoses, *Rhytidhysteron*, Dematiaceous fungi, Subcutaneousmycoses

Introduction

Subcutaneous mycoses include a heterogeneous group of fungal infections that usually develop following traumatic implantation of fungal elements from contaminated soil, thorns or wood splinters. More common in warm climates and immunocompromised individuals are at increased risk. Infection evolves slowly as the etiological agent survives and adapts to the adverse host tissue environment. The main subcutaneous fungal infections include sporotrichosis, chromoblastomycosis, mycetoma, lobomycosis, rhinosporidiosis, subcutaneous zygomycosis, and subcutaneous phaeohyphomycosis.⁽¹⁾ The common fungal etiologic agents like *Sporothrix schenckii*, *Cladophialophora carrionii*, *Fonsecaea pedrosoi*, *Phialophora verrucosa*, *Rhinocladiella aquaspersa*, *Exophiala jeanselmei*, *Exophiala spinifera*, *Wangiella dermatitidis*, *Acremonium* spp., *Bipolaris* spp., *Alternaria* spp., *Conidiobolus coronatus* and *Basidiobolus ranarum* have been associated with subcutaneous mycotic infections.^(2,3,4,5)

We report a case of subcutaneous mycoses in a Diabetic patient caused by a rare dematiaceous fungus *Rhytidhysteron rufulum*. To best of our knowledge this is the fifth case of subcutaneous mycoses caused by *Rhytidhysteron rufulum*.^(6,7,8,9)

Case Report

A 59 years old male presented with a history of painless, large, soft, slowly progressive, swelling, noduloulcerative lesion on his right leg for about two and half months duration approximately measuring about 7cms in length and 5cms in width at the lateral aspect of right ankle. The patient could not recollect the history of trauma at the site of lesion. The patient is also a known case of Diabetes since 10 years.

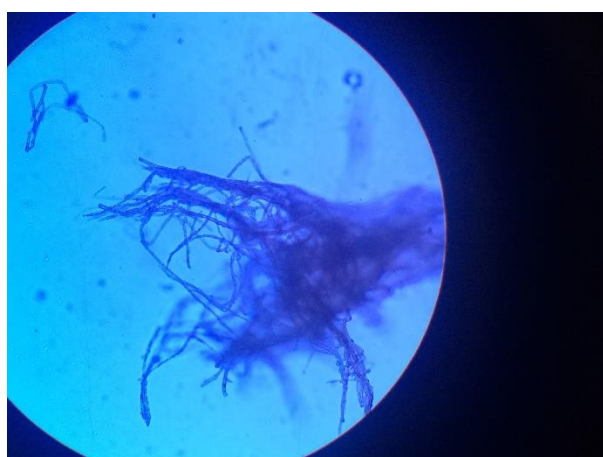
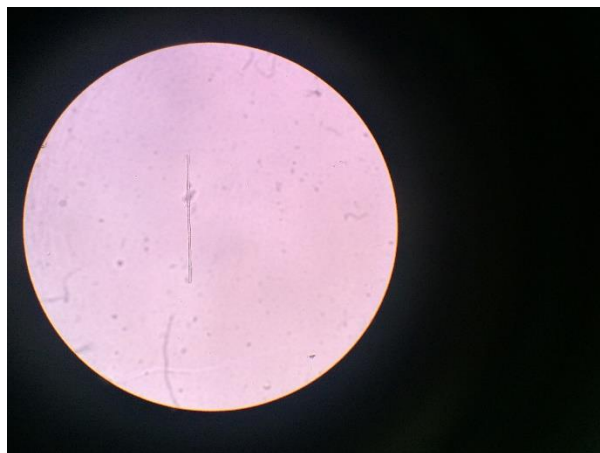Specimen for histopathological examination revealed fibroconnective tissue with areas of necrosis, many foreign body type giant cells and mononuclear

inflammatory cell infiltrates were seen. PAS stain showed fungal septate hyphae and spores.

The sample was sent for Culture and Identification of the causative agent. Direct microscopy revealed septate, branching pheoid hyphae.

Biopsy specimen was inoculated on to Sabarauds Dextrose Agar. After 3 weeks brown to black, velvety colonies with black reverse was observed. Thick, septate, irregularly branched dematiaceous, tortuous hyphae were identified on culture tease mount. Despite repeated attempts, the isolate failed to sporulate. As we could not identify the isolate on macroscopic and microscopic examination, the isolate was sent to NCCPF (National Culture Collection for Pathogenic Fungi), Post graduate institute of medical research and education (PGIMER) Chandigarh for further identification and was identified as *Rhytidhysteron rufulum* (NCCPF614).





Discussion

The genus *Rhytidhysterion* belongs to the Patellariaceae (Ascomycota), a poorly known family whose members have discoidal ascomata and bitunicate asci. Asci contain darkly pigmented ascospores which are elliptical or fusiform in shape with horizontal or longitudinal septa. Recent molecular phylogenetic analyses of multiple nuclear loci support it as being a member of Hysteriales and closely related to the saprobic *Hysterium pulicare*.⁽¹⁰⁾

The genus *Rhytidhysterion* includes two species: *R. rufulum* and *R. hysterinum*. The fungus has a worldwide distribution and occurs particularly in the tropics and subtropics.⁽¹¹⁾

Rhytidhysterion spp. are not known human pathogens and rarely implicated in human infections. It is commonly observed in patients with some degree of immunosuppression resulting from diseases like Tuberculosis, Diabetes, Acquired Immunodeficiency Syndrome (AIDS), hematological malignancies, or iatrogenic causes e.g. organ transplantation, corticosteroids, or immunosuppressive therapies

Habitat of *Rhytidhysterion* spp is known to be in the woods of living or dead dicotyledonous plants. The lesion usually results from the traumatic inoculation of the fungus or following wound contamination. The patient is a farmer by occupation but he could not recollect any history of injury at the site of his lesion. The daily activities in rural areas like walking barefooted, harvesting in the fields are some occupational risks to such kind of trauma, which usually go unnoticed.

The clinical manifestation begins with a usually single, slowly enlarging subcutaneous nodule on the extremities in 60% to 85% of cases.^(12,13) In our case, the patient presented with painless, large, soft, slowly progressive, noduloulcerative lesion.

Surgical excision, drainage, debridement, and cryotherapy, maximum doses of antifungal drugs (amphotericin B, 5-flucytosine, ketoconazole, fluconazole, itraconazole), superficial x-ray therapy, and thiabendazole have been used in various permutations and combinations to treat

phaeohyphomycosis, with variable degrees of success.^(14,15,16) Oral itraconazole at 200–400 mg/day or at a dose as high as 800 mg/day, for a period of 4–6 weeks, appears to be effective in phaeohyphomycosis.⁽¹⁶⁾

In the present patient, adequate control of the patient's diabetes was achieved, and the swelling was excised under itraconazole and terbinafine coverage. Response to the treatment was not known, as we lost the follow up of the patient.

This case highlights that the fungal etiology should be suspected in cases of subcutaneous swelling even in the immunocompetent patients of rural background and underlines the relevance of molecular techniques as valuable tools for identification of non-sporulating fungi.

Acknowledgment

The erudite help and support by NCCPF, Department of Medical Microbiology, Postgraduate Institute of Medical Education and Research, Chandigarh, India, in the molecular identification of the isolate is gratefully acknowledged.

References

1. Queiroz-Telles F., McGinnis M.R., Salkin I., Graybill J.R. Subcutaneous mycoses. *Infect Dis Clin N Am.* 2003;17(1):59–85. [PubMed]
2. McGinnis M.R. Chromoblastomycosis and phaeohyphomycosis: new concepts, diagnosis, and mycology. *J Am Acad Dermatol.* 1983;8:1–6. [PubMed]
3. Rippon J.W. WB Saunders; Philadelphia: 1988. Medical mycology. The pathogenic fungi and the pathogenic actinomycetes; pp. 276–296.
4. Kwon-Chung K.J., Bennett J.E. Lea and Febiger; Philadelphia: 1992. Medical mycology; pp. 337–355.
5. Hospenthal D.R. Agents of chromoblastomycosis. In: Mandell G.L., Bennet J.E., Dolin R., editors. Principles and practice of infectious disease. 7th ed. Churchill Livingstone; Philadelphia: 2010. pp. 2643–2654.
6. Mahajan, Vikram K., et al. "A rare case of subcutaneous phaeohyphomycosis caused by a *Rhytidhysterion* species: A clinico-therapeutic experience." *International journal of dermatology* 53.12 (2014):1485-1489.
7. Chowdhary, Anuradha, et al. "A rare case of chromoblastomycosis in a renal transplant recipient caused by a nonsporulating species of *Rhytidhysterion*." *Medical mycology* 46.2 (2008): 163-166.
8. Mishra, K., et al. "Subcutaneous mycoses caused by *Rhytidhysterion* species in an immunocompetent patient." *Medical mycology case reports* 5 (2014): 32-34.
9. Yadav Sarita, et al. "A Rare Case Report of Subcutaneous Mycoses by *Rhytidhysterion Rufulum*" *International Journal of Medical Research & Health Sciences*, 2017, 6(4): 12-15.
10. E.W.A. Boehm et al, A molecular phylogenetic reappraisal of the *Hysteriaceae*, *Mytiliniaceae* and *Gloniaceae* (*Pleosporomycetidae*, *Dothideomycetes*) with keys to world species Volume 64, Pages 1-220 (2009) A phylogenetic re-evaluation of *Dothideomycetes*.
11. Samuels GJ, Muller E. Life-history studies of Brazilian ascomycetes. *Rhytidhysterion rufulum* and the genus *Eutrybliidiella*. *Sydowia* 1979; 32: 277–292.
12. Mahajan, Vikram K., et al. "A rare case of subcutaneous phaeohyphomycosis caused by a *Rhytidhysterion* species: A clinico-therapeutic experience." *International journal of dermatology* 53.12 (2014): 1485-1489.
13. Sharma, Nand Lal, et al. "Subcutaneous phaeohyphomycosis in India: A case report and review." *International journal of dermatology* 41.1 (2002): 16-20.
14. Sharma NL, Mahajan V, Sharma RC, et al. Subcutaneous phaeohyphomycosis in India – a case report and review. *Int J Dermatol* 2002; 41: 16–20
15. Suh MK. Phaeohyphomycosis in Korea. *Jpn J Med Mycol* 2005; 46: 67-70
16. Ogawa MM, Galante NZ, Godoy P, et al. Treatment of subcutaneous phaeohyphomycosis and prospective follow-up of 17 kidney transplant recipients. *J Am Acad Dermatol* 2009; 61: 977–985.

How to cite this article: Tejashree A, Suchetha C, Visakha K, Karthik KM. A rare case of subcutaneous *Phaeohiphomyces* caused by *Rhytidhysterion rufulum*. *Indian J Microbiol Res* 2017;4(4):468-470.