

Small cell osteosarcoma of the maxilla

A. Sathish Selvakumar^{1,*}, V. Rajalakshmi²

¹Assistant Professor, ²Professor, Dept. of Pathology, ESIC Medical College & PGIMS, Chennai, Tamil Nadu

***Corresponding Author:**

Email: sathishpath17@gmail.com

Abstract

Osteosarcoma (OS), a primary malignant bone tumor usually arises from the metaphyses of long bones and less commonly in the flat bones. Small cell osteosarcoma (SCO) is a rare variant, comprising 1.5% of all OSs. A 37 years old gentleman presented with left maxillary swelling of 6 months duration and was treated by a local physician but the swelling did not subside. A biopsy revealed small and uniform tumor cells with diffuse growth pattern. Osteoid production, necrosis, and brisk mitoses were seen. A diagnosis of small cell osteosarcoma (SCO) was considered. Immunohistochemistry (IHC) was positive for osteopontin and vimentin with high Ki67 index confirming the diagnosis. He was treated with partial maxillectomy, chemotherapy and radiotherapy. He presented again with local recurrence into the orbit and distant metastases to brain and lung. A palliative complete maxillectomy with total orbital exenteration and defect reconstruction was performed. The patient died six months after the surgery. Differential diagnosis includes small round blue cell tumors like Ewing sarcoma/primitive neuroectodermal tumor (PNET), non-Hodgkin lymphomas, small cell carcinoma, neuroblastoma, and mesenchymal chondrosarcoma. Histopathological evaluation along with negative IHC staining of CK, p63, S100, HMB45, CD99, LCA, SMA and PAS stain helps in ruling out the various differential diagnoses. Surgery and chemotherapy improves disease free survival rates by 10% to 20%. SCO in the flat bones of the head and neck region involving the orbit is very rare with poor prognosis. We highlight SCOs rarity, aggressive behaviour and the role of histopathological evaluation in clinching the diagnosis.

Keywords: Osteosarcoma, Bone, Immunohistochemistry, Ewing sarcoma

Introduction

Osteosarcoma (OS), a more common primary malignant bone tumor, occurs 1.4 times more frequently in males than in females.^(1,2) It has several variants with distinct clinico-pathologic characteristics of which Small cell osteosarcoma (SCO) is a rare aggressive variant, accounting for about 1% to 1.5% of all OSs with an incidence rate of 1.3%.⁽³⁾

Case Report

A 37 years old gentleman presented with left maxillary swelling of 6 months duration and was treated by a local physician but the swelling did not subside. He was positive for HBsAg but negative for HIV. A biopsy study revealed small and uniform tumor cells with diffuse growth pattern (Fig. 3). Osteoid production, necrosis, and brisk mitoses (6-8/10 HPF) were seen (Fig. 4, 5). A diagnosis of small cell osteosarcoma (SCO) was considered. Immunohistochemistry (IHC) was positive for osteopontin and vimentin with high Ki67 index confirming the diagnosis. He was treated with partial maxillectomy, chemotherapy and radiotherapy. He presented again with local recurrence into the orbit 1½ years later. MRI brain and CT thorax suggested distant metastases to brain and lung. A palliative complete maxillectomy with total orbital exenteration and defect reconstruction was performed (Fig. 1). The specimen received measured 10x9x5cm with a fungating ulcer measuring 4x3cm was seen in the orbital region along with multiple soft tissue pieces together measuring 5x3 cm (Fig. 2). The histopathological and IHC studies

were similar as the earlier biopsy study. However the patient died six months after the surgery.

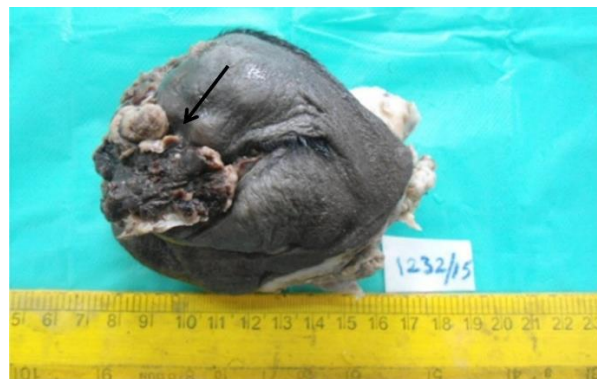

Fig. 1: Total orbital exenteration with an ulceroinfiltrative growth in the inner canthus region

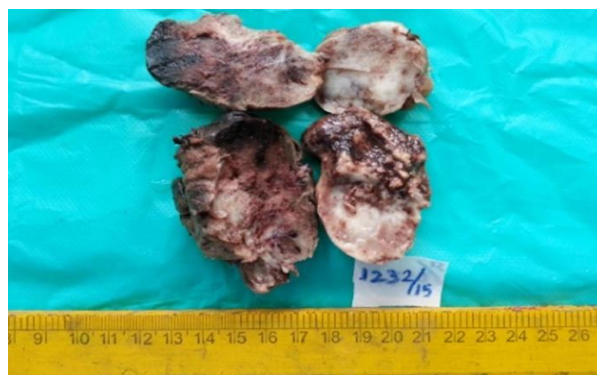


Fig. 2: Cut section of the tumor has a fleshy appearance

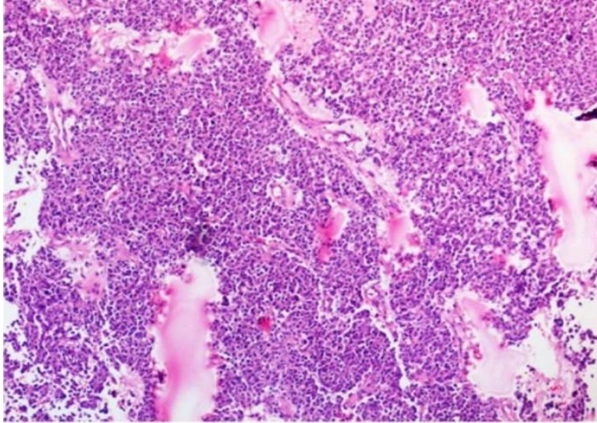


Fig. 3: Section show sheets of small blue round cells (H&E, X100)

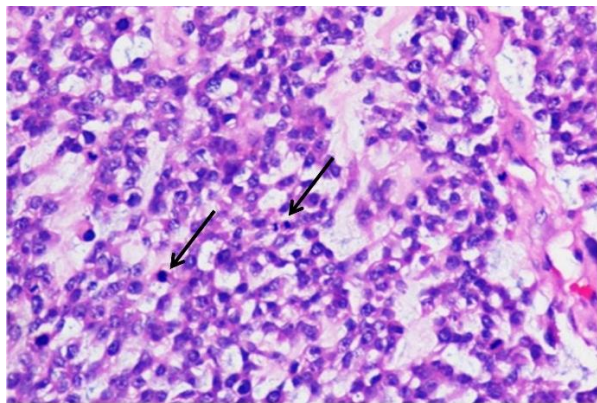


Fig. 4: Section show small blue round cells with frequent mitoses (H & E, X400)

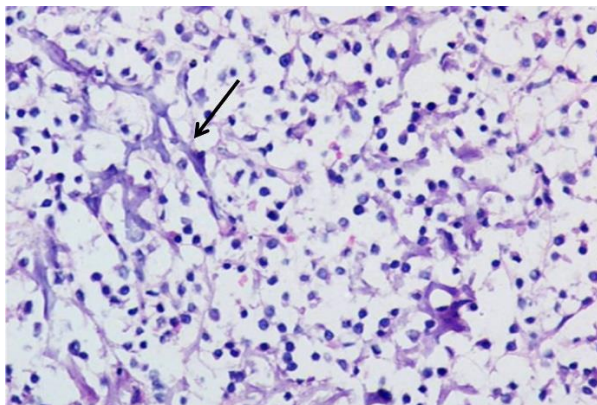


Fig. 5: Section show tumor osteoid (H&E, X400)

Discussion

Osteosarcoma (OS) has an incidence of 2–3/million in the general population with an increased incidence in the adolescence age group (15–19 years) at 8–11/million.⁽⁴⁾ Small cell osteosarcoma (SCO) is a rare variant of OS first described in 1979.⁽⁵⁾ It has an anatomical distribution and radiographical appearance similar to that of a conventional OS with a poor prognosis.⁽⁶⁾ Pain and swelling of the affected region is the most common clinical presentation which were the

presenting complaints in our case.⁽⁷⁾ SCO predominantly affects the metaphyses of the long bones especially the femur.⁽³⁾ The head and neck region is rarely involved with only 5% of the osteosarcoma affecting the jaws and maxilla affected very rarely.⁽⁶⁾ Majority of the osteosarcoma of the head and neck region are aggressive with local invasion leading to difficulty in controlling the disease and ultimately a high mortality rate.⁽⁸⁾ Our case had a recurrence 1½ years after partial maxillectomy and concurrent chemotherapy and radiotherapy. The recurrence involved the orbit with distant brain, and lung metastases. He was therefore subjected to palliative orbital resection and flap reconstruction of the defect.

SCO has a fleshy gross appearance like any other highly cellular neoplasm and our case had a similar appearance.⁽⁹⁾ Histologically the cells in SCO are usually arranged as strands, cords, sheets, nests or glands.⁽⁷⁾ The nuclei are generally 6.7–15 µm in diameter with inconspicuous to prominent nucleoli, finely dispersed or clumped nuclear chromatin, brisk mitoses with osteoid or immature bone formation.⁽⁶⁾ Our case had tumor cells arranged as diffuse sheets and cords and the cells were small round to oval, uniform with the nuclei having dispersed to clumped chromatin and inconspicuous nucleoli. Osteoid production, necrosis, and brisk mitoses (6–8/10 HPF) were seen. Osteoid production by the tumoral cells remains the corner stone of osteosarcoma identification.⁽¹⁾

The differential diagnosis of SCO includes other small round blue cell tumors, such as Ewing sarcoma/primitive neuroectodermal tumor (PNET), non-Hodgkin lymphomas, small cell carcinoma, neuroblastoma, and mesenchymal chondrosarcoma.⁽⁹⁾

Ewing sarcoma (ES)/PNET is a close differential diagnosis of SCO.⁽³⁾ The Ewing's sarcoma also has tumor cells having scant cytoplasm, round nuclei, fine chromatin and inconspicuous nucleoli as in SCO.⁽⁶⁾ Greater variations in the nuclear shape from oval to spindle shape can help in differentiating SCO from ES which usually have singly dispersed cells with round to uniform nuclei.⁽⁶⁾ Absence of osteoid, presence of Homer Wright rosettes and pseudorosettes favours Ewing sarcoma/PNET and neuroblastoma over small cell osteosarcoma.⁽⁹⁾ A positive staining for CD99 may be seen in Ewing sarcoma/PNET and small cell osteosarcoma but a negative staining will definitely point in favour of SCO. Our case had negative staining for CD99.⁽⁹⁾ Pellin et al. Showed the presence of translocation (11:22) (q24; q12), in Ewing's sarcomas and PNETs, and absent in other round cell tumors, including small cell osteosarcoma.⁽¹⁰⁾ Presence of glycogen in the tumor cells is not specific for Ewing's sarcoma, as even rhabdomyosarcomas, neuroblastomas and few cases of small cell osteosarcoma may also show PAS positivity.⁽⁶⁾

The SCO histology can also resemble that of a non-Hodgkin lymphoma.⁽⁹⁾ The cells in lymphoma usually

have larger nuclei than in small cell osteosarcoma, with vesicular chromatin, irregular nuclear membranes, prominent nucleoli, and a lack of cellular cohesion, absent osteoid production along with positive staining for common leukocyte antigen and flow cytometry helps to rule out a lymphoproliferative process.⁽⁹⁾ Small cell carcinoma very rarely manifests as a bony mass, will stain for cytokeratins and neuroendocrine markers like synaptophysin and chromogranin.⁽⁹⁾ Metastatic neuroblastoma in bone can mimic small cell osteosarcoma but the absence of osteoid, history of an adrenal primary, and positivity for synaptophysin and chromogranin with CD99 negativity points in favour of SCO.⁽⁹⁾ Mesenchymal chondrosarcoma has areas of small round blue cell morphologic features, but the presence of “staghorn,” hemangiopericytoma-like vessels and areas of differentiated cartilage is usually not seen in, small cell osteosarcoma.^(9,11) Mesenchymal chondrosarcoma can be a differential diagnosis when SCO can have cartilagenous areas and in such conditions a high grade malignant cartilage helps to rule out a mesenchymal chondrosarcoma where the cartilage formed is usually of low grade malignancy.⁽⁷⁾

Ayala et al. noted three histological patterns in SCO namely the Ewing’s sarcoma-like, lymphoma-like and small spindle cell like. In tumors showing multiple patterns, the type is determined by the predominant pattern.⁽¹²⁾ Our case closely resembled the Ewing’s Sarcoma type. Small cell osteosarcoma has a poor prognosis in comparison with conventional osteosarcoma and Ewing’s sarcoma.⁽¹³⁾ Nakajima et al. reported an overall 5year survival rate of 28.6% compared to conventional osteosarcoma (77%) and Ewing’s sarcoma (50%) and chemotherapy along with surgery to improve the prognosis.⁽³⁾ A complete clinical, histopathological examination aided by immunohistochemical evaluation helps in clinching the diagnosis of small cell osteosarcoma and a correct diagnosis helps immensely in the planning of therapy for the lesion.⁽⁹⁾

Conclusion

Small cell variant of osteosarcoma in the flat bones involving the orbit is very rare. They are aggressive with poor prognosis. Due to its rarity the treatment has not been optimized but often the patients are treated like conventional osteosarcoma, with neoadjuvant chemotherapy followed by surgical resection with clear margins.

References

1. Pouyan Amini Shakib, Ramin Foroughi, Maryam Seyedmajidi. Osteosarcoma of the Maxilla: A Rare Case with Unusual Clinical Presentation. *J Dent Res Dent Clin Dent Prospect* 2013;7(3):177-181
2. Stiller CA, Craft AW, Corazziari I. Survival of children with bone sarcoma in Europe since 1978: results from the EURO CARE study. *Eur J Cancer* 2001; 37:760-766.
3. Hisaya Nakajima, Franklin H. Sim, Jeffrey R. Bond., K. Krishnan Unni. Small Cell Osteosarcoma of Bone. *Review of 72 Cases. CANCER* June 1, 1997 / Volume 79 / Number 11.
4. J. Ritter, S. S. Bielack. Osteosarcoma. *Annals of Oncology* 21 (Supplement 7): vii320–vii325, 2010.
5. Sim FH, Unni KK, Beabout JW, Dahlin DC. Osteosarcoma with small cells simulating Ewing’s tumor. *J Bone Joint Surg Am* 1979;61:207–15.
6. Amit Sethi, Shweta Rehani, Kundendu Arya. Small Cell Osteosarcoma of Mandible: A rare case report and review of literature. *J Clin Exp Dent.* 2010;2(2):e96-9.
7. Uma K, Cherian G, Nayak V, Patil S. Small cell osteosarcoma of the mandible: Case report and review of its diagnostic aspects. *J Oral Maxillofac Pathol* 2011;15:330-4.
8. Guadagnolo BA, Zagars GK, Raymond AK, Benjamin RS, Sturgis EM. Osteosarcoma of the jaw/craniofacial region: outcomes after multimodality treatment. *Cancer* 2009; 115:3262-70.
9. Justin A. Bishop, MD, Chung H. Shum, MD, PhD, Sheila Sheth, MD, Paul E. Wakely Jr, MD, and Syed Z. Ali, MD. Small Cell Osteosarcoma Cytopathologic Characteristics and Differential Diagnosis. *Am J Clin Pathol* 2010;133:756-761.
10. Pellin A, Boix J, Blesa JR, Noguera R, Carda C, Llombart-Bosch A. EWS/FLI-1 rearrangement in small round cell sarcomas of bone and soft tissue detected by reverse transcriptase polymerase chain reaction amplification. *Eur J Cancer* 1994;30A:827-31.
11. Unni KK, Inwards CY, Bridge JA, et al. Small cell osteosarcoma. In: *Tumors of the Bones and Joints*. 4th ed. Washington, DC: American Registry of Pathology Press; 2005:299.
12. Ayala AG, Ro JY, Raymond AK, Jaffe N, Chawla S, Carrasco H, et al. Small cell osteosarcoma. A clinicopathologic study of 27 cases. *Cancer.* 1989;64:2162-73.
13. Glasser DB, Lane JM, Huvos AG, Marcove RC, Rosen G. Survival, prognosis, and therapeutic response in osteogenic sarcoma. The Memorial Hospital experience. *Cancer.* 1992;69:698-708.