

Burden of developmental dysplasia of hip among neonates in a tertiary care setting of Odisha

Siddhartha Sahu^{1,*}, Manas Kumar Nayak², Ipsa Mohapatra³, Seba Ranjan Biswal⁴, Arya Jha⁵

^{1,2,3}Assistant Professor, ⁴Associate Professor, ⁵Medical Student, ^{1,5}Dept. of Orthopaedics, ^{2,4}Dept. of Paediatrics, ³Dept. of Community Medicine, Kalinga Institute of Medical Sciences, Bhubaneswar

***Corresponding Author:**

Email: sidusahu@gmail.com

Abstract

Developmental dysplasia of the hip (DDH) is one of the commonest orthopaedic problem in new-borns.

Aim & Objective: To determine the incidence of DDH on clinical screening of neonates.

Materials & Methods: All new-borns, born in our institution during August 2016 to July 2017, fulfilling inclusion criteria and giving written informed consent were sampled consecutively and screened clinically for DDH by performing clinical tests namely Ortolani's and Barlow's tests for neonatal hip instability. Screening for other clinically apparent orthopaedic disorders was also done.

Results: Of a total of 1414 new-borns screened 740 were male and 674 were female. 617 were born by a vaginal delivery and 797 were born by Caesarean Section. 1204 were born at full term and 210 were preterm before 36 weeks of gestation. None of the neonates examined had any clinical signs suggestive of DDH like Barlow's and Ortolani's test or restricted abduction of the hip.

Conclusion: Our study reported zero incidence of DDH. Larger sample size studies are needed to better understand the incidence of DDH in India.

Keywords: Developmental Dysplasia of Hip, DDH, Neonatal Hip Instability.

Introduction

Developmental dysplasia of the hip (DDH) is the most common orthopaedic problem in new-borns reported in Western literature.⁽¹⁾ The incidence of DDH worldwide has been reported to vary widely from as less than 1/1000 to as many as 34/1000 live births.⁽²⁾ There is very little data available on the incidence of DDH in our country.⁽³⁾

Developmental dysplasia of the hip (DDH) includes a spectrum of structural abnormalities that compromise the stability of a growing hip.⁽⁴⁾ Early recognition of DDH and prompt treatment is crucial in providing optimum functional outcome.⁽⁵⁾ Persistence of hip dysplasia into adulthood may result in abnormal gait and increases the risk of degenerative hip and knee joint disease. Delayed diagnosis leading to delaying treatment must be avoided, as outcomes deteriorate with increasing delay of presentation.⁽⁶⁾ Clinical screening using Ortolani's and Barlow's tests are useful in early detection of DDH.⁽⁷⁾

The incidence in India varies from as low as 0.42 in rural Ballabgarh, Haryana,⁽⁸⁾ to between 1.0⁽⁹⁾ and 2.65⁽¹⁰⁾ in New Delhi, to as high as 9.2⁽¹¹⁾ in northern India (Chandigarh). Risk factors identified for DDH include female, first born, breech position, positive family history, left hip, and unilateral involvement. The left hip is more commonly involved in those with unilateral dysplasia.⁽¹²⁾

Developmental dysplasia of the hip (DDH) is an epidemiological challenge. The literature pertaining to the epidemiology of DDH is vast and confusing due to differing definitions of hip dysplasia, variable methods of diagnosis, and the different ethnicities of the study

population.⁽¹⁰⁾ There is no national screening protocol currently nor any national registry and sparse data exists on incidence of DDH estimated either clinically or ultrasonologically in India.⁽³⁾

Aims & Objectives

Our objective was to determine the incidence of DDH by clinical screening for neonatal hip instability and to screen for any other congenital orthopaedic deformities by clinical screening. This will help in devising screening protocols and increase awareness about DDH in India.

Materials & Methods

A. Study population: All Neonates born in Kalinga Institute of Medical Sciences Bhubaneswar from August 2016 to July 2017 who fulfilled inclusion criteria were included in the study.

Inclusion criteria:

- All babies below 28 days born in KIMS.
- Only those babies whose parents consented for examination and inclusion in the study were included.

Exclusion criteria:

- Seriously sick babies in whom examination was not possible.
- Babies whose parents did not give consent, and
- Babies above age of 28 days.

B. Screening methodology: The two step technique of screening recommended in England⁽¹³⁾ was followed wherein all new-borns after informed consent of parents were clinically screened within 48 hours of birth for hip instability to diagnose DDH

and for other congenital deformities and only new-borns with positive examination for DDH were planned to be screened ultra sonographically at 3 weeks.

Instability of the hip was assessed by the Ortolani and Barlow tests, which are the keystone of clinical screening for developmental dysplasia of the hip (DDH). Additional findings checked on physical examination in infants included asymmetry of gluteal and thigh skin folds, discrepant leg lengths and diminished range of motion (particularly abduction) in an affected hip. Either a positive Ortolani's, Barlow's tests or restricted abduction were accepted as positive findings on examination of DDH.^(14,15) A general head to toe examination of all new-borns was done to screen for any other congenital deformities that were clinically obvious. The Barlow and Ortolani tests were performed by the senior authors of the study experienced in neonatal examination for standardisation.

The Ortolani test, was performed by applying forward pressure to both the femoral heads, trying to reduce a posteriorly dislocated femoral head back into the acetabulum. The examining hand grasped the affected hip with the thumb on the medial aspect of the thigh and the middle and index finger along the greater trochanter. The hip and knee was then flexed to 90° and abducted with the middle and index finger pushing the trochanter forward. A palpable clunk suggested that the hip was dislocated or subluxed, but reducible.

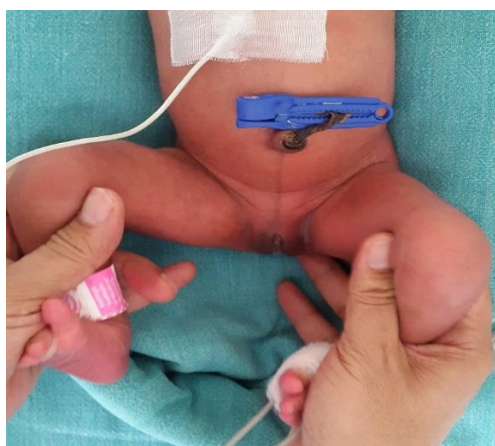

Fig. 1: Ortolani's test involves applying forward pressure to each femoral head, attempting to reduce

a posteriorly dislocated femoral head back into the acetabulum.

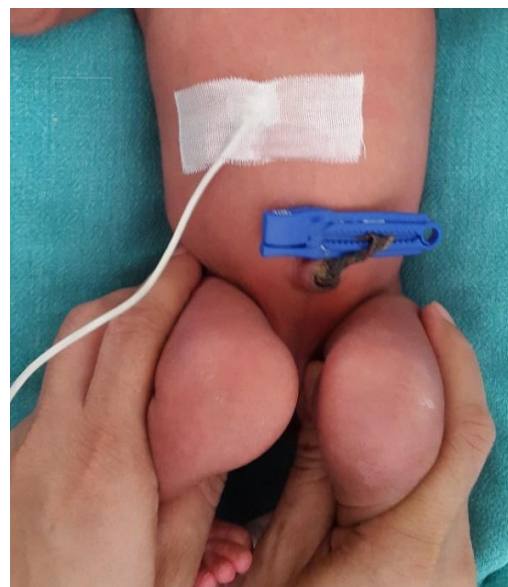


Fig. 2: Barlow's test involves applying backward pressure to the head of each femur attempting to displace a subluxable hip

The Barlow test,⁽¹⁷⁾ was done by applying backward pressure to the head of both femurs, trying to displace a subluxable hip. The child was placed supine. The hip was flexed 90° and adducted from an abducted position. Simultaneously a posteriorly directed pressure in the line of femur was applied to displace the femoral head from the acetabulum. The palpable clunk of a dislocatable head moving out was appreciated in a positive Barlow test.

Results

Of a total of 1414 new-borns screened 740 were male and 674 were female. 617 were born by a vaginal delivery and 797 were born by Caesarean Section. 1204 were born at full term and 210 were preterm before 36 weeks of gestation. None of the neonates examined had any clinical signs suggestive of DDH like Barlow's and Ortolani's test or restricted abduction of the hip.

Table 1: New borns month wise screening data

Month	Vaginal Deliveries			Caesarean Section			Grand Total
	Male	Female	Total	Male	Female	Total	
August 2016	23	22	45	34	38	72	117
September 2016	25	25	50	37	31	68	118
October 2016	17	29	46	43	39	82	128
November 2016	29	17	46	32	34	66	112
December 2016	33	39	72	38	28	66	138
January 2017	24	20	44	34	32	66	110
February 2017	16	18	34	44	25	69	103

March 2017	33	23	56	29	31	60	116
April 2017	42	23	65	26	30	56	121
May 2017	22	29	51	36	19	55	106
June 2017	29	26	55	37	32	69	124
July 2017	25	28	53	32	36	68	121
Total	318	299	617	422	375	797	1414

However 4 cases of Congenital Talipes Equinovarus (CTEV) were detected of which 3 were male and 1 female. 2 were Bilateral, 1 was right sided and the other left sided. All CTEV cases were full term deliveries by vaginal delivery.

One case of left sided Congenital Vertical talus was detected and confirmed radiologically in a full term male baby born by Caesarean section.

One case of a left sided Radial club hand in a 30 week preterm female born by Caesarean section was observed with x ray confirming the diagnosis.

Discussion

Western literature describes DDH as the commonest congenital orthopaedic disorder. A study of 67,093⁽¹⁸⁾ neonates in Aberdeen estimated the incidence of clinical neonatal hip instability to be as high as 50 per 1000 live births. The average weighted incidence of clinical neonatal hip instability for all Caucasians was calculated to be 10.8 per 1000 live births.⁽¹⁰⁾ The incidence of DDH in African neonates is very low with a study by Bialik et al⁽¹⁹⁾ reporting a incidence of DDH in neonates to be considered as zero.

Indian studies that reported the incidence for DDH by clinical screening for neonatal instability have shown varying results. While Gupta et al⁽⁸⁾ reported an incidence of 18.7 cases of DDH per 1000 live births by clinically screening 6029 neonates for hip instability in Delhi, a clinical screening of neonates in Mumbai⁽²⁰⁾ reported incidence of DDH to be 0.17 per 1000. In a 2011 study of 1000 infants in Vellore in South India only 1 infant was found clinically to have DDH.⁽³⁾ Most of the Indian studies included the population of Northern India,⁽⁴⁾ where the incidence of DDH seems to be higher. To the best of our knowledge this is the only study reporting incidence of DDH from East India. Our study where no new-born with DDH was found on clinical screening is consistent with the low incidence of DDH reported by most Indian authors.

Conclusion

DDH is a common orthopaedic disorder in neonates in the Western Hemisphere. Screening at birth leads to early detection and prompt treatment to prevent later sequelae. Our study corroborates most Indian studies that seem to suggest a low incidence in India. However our study was limited by its sample size. More studies with larger sample sizes are needed to better clarify the incidence of DDH in India. This will help formulate a national policy on screening and management of DDH in India.

Acknowledgements

We would like to acknowledge our gratitude to Professor Dr. Tribhuvan Mohan Mahapatra Pro VC, KIIT University for his encouragement and guidance. We thank Mr Govind Pratap Singh, Mr Ankit Jain, Mr. Debi Prasad Nanda and Mr. R Prateek Priyadarshan, Medical students of Kalinga Institute of Medical Sciences for their assistance in the research.

References

1. Daniel Williams, Evangelia Protopapa, Kuldeep Stohr, James B. Hunter and Andreas Roposch, "The most relevant diagnostic criteria for developmental dysplasia of the hip: A study of British specialists" *BMC Musculoskeletal Disorders* (2016)17(1),38.
2. John Anthony Herring (Editor), "Developmental dysplasia of the Hip" Tachdjian's Pediatric Orthopaedics 4th ed. Philadelphia, PA: Saunder's Elsevier (2008) 637-770.
3. Chirag Bhalvani, Vrisha Madhuri, "Ultrasound Profile of Hips of South Indian Infants" *Indian Paediatrics*(2011)48,475-477
4. P.J Klisic, "Congenital dislocation of the hip—a misleading term: a brief report" *Journal of Bone and Joint Surgery British* (1989)71,136.
5. Anil Agarwala, Neeraj Gupta, "Risk factors and diagnosis of developmental dysplasia of hip in children" *Journal of Clinical Orthopaedics and Trauma* (2012 Jun)3(1),10–14.
6. Pavel Kotlarsky, Reuben Haber, Victor Bialik, and Mark Eidelman, "Developmental dysplasia of the hip: What has changed in the last 20 years?" *World Journal of Orthopedics* (2015 Dec) 6(11),886-901.
7. American Academy of Pediatrics, Committee on Quality Improvement, Subcommittee on Developmental Dysplasia of the Hip, "Clinical practice guideline: early detection of developmental dysplasia of the hip." *Pediatrics* (2000)105,896-905.
8. R Kulshrestha, L.M Nath, P Upadhyaya, "Congenital malformations in live born infants in a rural community" *Indian Pediatrics* (1983)20(1),45-49.
9. Meharban Singh, N. K. Sharma, "Spectrum of congenital malformations in the new born" *The Indian Journal of Pediatrics* (1980)47(3),239-244.
10. A.K Gupta, S Kumari, P.L Arora, R Kumar, A.K Mehtani, L.K Sood, "Hip instability in new borns in an urban community" *The National Medical Journal of India* (1992)5(6),269-272.
11. Vikrant Kaushal, Shifa Kaushal, O.N Bhakoo, "Congenital dysplasia of the hip in northern India" *International Surgery* (1976)61(1),29.
12. Randall T. Loder, Elaine N. Skopelja, "The Epidemiology and Demographics of Hip Dysplasia", *ISRN Orthopedics* (2011)238607,46 pages.
13. Dai Anthony Jones, Niels Powell, "Ultrasound and neonatal hip screening. A prospective study of 'high risk' babies" *Journal of Bone and Joint Surgery British* (1990)72,457-9.

14. Francesco M. Lotito, Giuseppe Rabbagietti, Margherita Notarantonio, "The ultra sonographic image of the infant hip affected by developmental dysplasia with a positive Ortolani's sign" *Pediatric Radiology* (2002 Jun)32(6),418-22.
15. Screening for Developmental Dysplasia of the Hip, 2006, available from U.S. Department of Health and Human Services Agency for Healthcare Research and Quality, website: www.ahrq.gov
16. Marino Ortolani, "Congenital hip dysplasia in the light of early and very early diagnosis." *Clinical Orthopaedics Related Research*. (1976)119,6-10.
17. Thomas Geoffrey Barlow, "Early diagnosis and treatment of congenital dislocation of the hip in the newborn" *Proceedings of the Royal Society of Medicine* (1966)59,1103-1106.
18. IA Lennox, J McLauchlan, R Murali, "Failures of screening and management of congenital dislocation of the hip" *Journal of Bone and Joint Surgery British* (1993)75(1),72-5.
19. V Bialik, M Berant, "'Immunity' of Ethiopian Jews to developmental dysplasia of the hip: a preliminary sonographic study" *Journal of Pediatric Orthopedics part B*(1997 Oct)6(4),253-4.
20. N.S Tibrewala, P.M Pai, "Congenital malformations in the newborn period" *Indian Pediatrics* (1974)11(6),403-407.